

A Case of HTLV-I Associated Myelopathy(HAM) in Korea

Jae-Hyeon Park¹, Byung-In Lee¹, Sae-il Chun², and Mitsuhiro Osame³

We report the first Korean case of HTLV-I associated myelopathy (HAM), which was confirmed by Western blot assay of serum and cerebrospinal fluid. Interestingly, the proband's wife was a Japanese Korean who had lived in the endemic area of HAM, Kyushu, Japan. Investigations revealed significantly elevated anti HTLV-I antibody titers in the serum, but not in the CSF, suggesting that she was a carrier of HTLV-I. Considering that the patient had not had a previous blood transfusion, the most common route of HTLV-I, it is likely that the patient was infected by his wife through sexual intercourse. Although previous reports suggest that the transmission of HTLV-I is essentially from man to man or man to woman, our case suggests that woman to man transmission also occurs.

Key words : HTLV-I, Myelopathy, TSP

Human T Lymphotropic Virus Type I(HTLV-I) is a human retrovirus known as a causative agent of adult T cell leukemia and lymphoma(ATLL) (Poiesz 1980). The same virus was recently found to be related to certain types of chronic myelopathies in the tropical area(tropical spastic paraparesis) (Gessain et al.1985, Rodgers-Johnson et al. 1985). Subsequently, Osame et al. (1986) reported that HTLV-I was also associated with the spastic paraparesis occurring in Japan. Because Japan was a temperate zone, they proposed the term HTLV- I associated myelopathy(HAM) in distinction from the tropical spastic paraparesis(TSP).

Recent investigations clearly demonstrated the close link between HTLV-I and TSP/HAM which confirm HTLV-I as a causative agent of TSP/HAM. TSP and HAM are now considered the same disorder(Roman et al. 1988).

Despite very intimate communications between Korea and Japan, no cases of HAM have been reported in Korea. We report here a 40-year-old Korean male with HAM, confirmed by Western blot assay of serum and cerebrospinal fluid.

CASE REPORT

A 40-year-old Korean male was admitted to the Yonsei University Medical Center, Severance Hospital, for further evaluation of a progressive gait disturbance which started three years ago. His past medical history and family history were essentially negative. He was a star player of the Korean National Soccer Team in the 70's and had been very active working as a director of a soccer team. He denied any previous history of transfusion. In 1982, he married a Japanese Korean female who had lived in Kyushu, Japan, known as an endemic area of HAM.

In late 1986, over a few months cold sensations and paresthesia developed in the right lower extremity with gradual involvement of the left lower extremity. Shortly after that, he felt weakness in lower extremities when he ran. Since 1988, he has had trouble in walking due to weakness of the legs,

Received February 13, 1991

Accepted March, 20, 1991

Departments of Neurology¹ and Rehabilitation², Yonsei University College of Medicine, Seoul, Korea

Department of Internal Medicine³, Faculty of Medicine, Kogoshima University, Kagoshima, Japan.

Address reprint requests to Dr. J-H Park, Department of Neurology, Yonsei University College of Medicine, Severance Hospital. C. P. O. Box 8044, Seoul Korea, 120-752

slightly worse in the right. In 1989, he began to use a walker due to progressive motor weakness and stiffness of the lower extremities. He denied any problem with upper extremities but noticed urinary frequency and incontinence.

Neurological examination at admission showed normal mental status and cranial nerves. In the motor examination, muscle strength, bulk and tone were normal in both upper extremities. In the lower extremities, however, strength was Grade 3/5 in the left and Grade 2/5 in the right flexor muscles, Grade 4+/5 in the left and Grade 4/5 in the right extensor muscles. Muscle tone was markedly increased in both lower extremities with easily elicited sustained ankle clonus. In the sensory examination, upper extremities were normal. Pin prick and light touch were normal, but position and vibration sense was moderately impaired in the lower extremities, being slightly worse in the right. Sensory levels were not clearly defined. Deep tendon reflexes were brisk symmetrically in the lower extremities. Plantar responses were dorsiflexion in the right and equivocal in the left. Anal sphincter tone was normal.

Laboratory tests including CBC, urinalysis, serum electrolyte, ESR, EKG, liver function test, renal function test and serum CPK were normal. Serum VDRL was non reactive and serum vitamin B12 and folate were 1230 pg/ml and 7.38 ng/ml respectively. Serum protein electrophoresis was in the normal range.

Electrodiagnostic studies showed normal NCV, EMG, visual evoked potentials and brain stem auditory evoked potentials. Median nerve evoked somatosensory evoked potentials(SEPs) elicited normal responses, but posterior tibial nerve stimulation elicited no cortical waves bilaterally.

Radiological studies including chest PA, brain CT scan, myelography with CT scan and spinal MR imaging were all normal.

Lumbar puncture yielded clear CSF with normal pressure. RBCs were 10, WBCs were 3. Sugar was 59mg/dl, protein was 85 mg/dl and no atypical lymphocytes were seen. CSF oligoclonal band was not detected and myelin basic protein was 2.6ng/ml, but IgG index was elevated(0.73). Serum and CSF samples of the patient and his wife were sent to Dr. Osame's lab in Japan for western blotting. In particle agglutination method(PA method) using the Serodia-ATLA kit of Fujirebio, Inc. (Ikeda et al. 1984), both serum and CSF of the patient showed very high titers of HTLV-I antibody, 1 : 8192 and 1 : 512, respectively. His wife also showed high

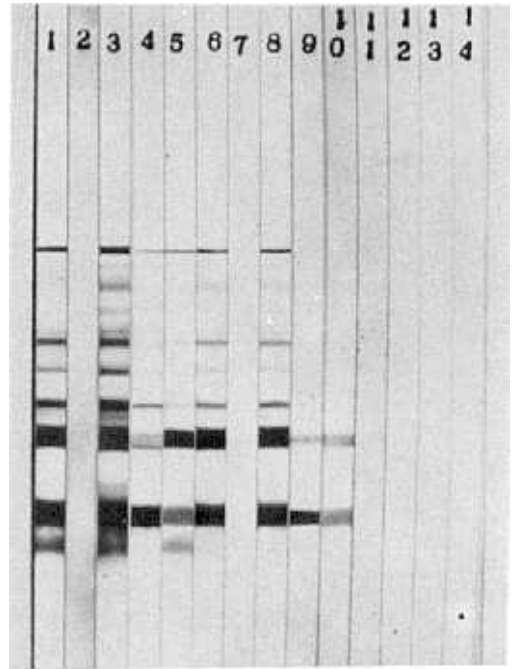


Fig. 1. Western blot pattern in serum and CSF samples from patient, his wife, Japanese HAM patients and controls.

Lane 1 : serum IgG from Japanese HAM patient
Lane 2 : serum IgG from control
Lane 3 : serum** IgG from patient
Lane 4 : serum IgG from patient's wife
Lane 5 : CSF IgG from Japanese HAM patient
Lane 6 : CSF** IgG from patient
Lane 7 : CSF IgG from patient's wife
Lane 8 : CSF* IgG from patient
Lane 9 : serum IgM from Japanese HAM patient
Lane 10 : serum** IgM from patient
Lane 11 : serum IgM from patient's wife
Lane 12 : CSF** IgM from patient
Lane 13 : CSF IgM from patient's wife
Lane 14 : CSF* IgM from patient

CSF* : CSF obtained before steroid therapy

CSF** : CSF obtained after steroid therapy

serum** : serum obtained after steroid therapy

HTLV-I antibody titers in the serum(1 : 256), but not in CSF(1 : 8). Confirmation by western blot with MT-2 cell lysate antigens (Miyoshi et al. 1981) was done in the serum and CSF of the patient and his wife. The patient's serum and CSF showed p19, p24 and p53 band but his wife's did not(fig. 1).

After steroid therapy(prednisolone 60mg per day) for one month, western blot assay and neurologic examination were repeated without significant interval changes.

DISCUSSION

HTLV-I is known to cause HAM and TSP in endemic areas including southern islands of Japan, Caribbean Sea, Africa and Southern America, etc.

Since Gessain et al. (1985) first reported that 59 % of patients with TSP had antibodies to HTLV-I in a serological test in Martinique, subsequently antibodies to HTLV-I were also found in the serum and CSF in cases from Jamaica and Columbia. In Japan, Osame et al. (1986) have reported a new entity of HTLV-I associated myelopathy(HAM) characterized by chronic progressive spastic paraparesis. Because Japan is a temperate zone, they proposed the term HAM instead of TSP. The current belief is that HAM and TSP are the same disease(Roman 1988).

Clinical features suggesting HAM include slowly progressive and symmetrical lower extremities weakness with burning or tingling sensations and urinary disturbances. On neurologic examination, patients with chronic disease may show atrophy of lower limbs. Hyperreflexia, Babinski sign and ankle clonus are found in almost all patients, and sensory examination usually shows mild diminution of position and vibration sense in the lower legs with no definite sensory level.

Characteristic laboratory findings in patients with HAM, in addition to elevated titers in both serum and CSF, include atypical lymphocytes in serum and CSF, mild CSF pleocytosis, increased IgG index and presence of CSF oligoclonal bands. However, clinical and laboratory features characteristics of HAM may not present in all patients. In multimodality evoked potentials, Kakigi et al. (1988) reported abnormal posterior tibial nerves SEPs with normal median nerve SEPs in patients with HAM and suggested that the predominant lesion was in the level of thoracic cord.

There is usually no definite abnormality found in both cerebral and spinal MR imaging. However Kira et al. (1988) reported that thirteen(59%) of 22 patients of HAM showed high signal intensity lesions in the cerebral white matter suggesting difficult problems in the differential diagnosis of HAM from multiple sclerosis. In fact, Koprowski et al. reported that a large number of the serum and CSF samples from Swedish and American(Key West, Florida)

multiple sclerosis patients contained antibody reactive with P24 gag protein of HTLV-I(1985). Ohta et al. also reported that 11(24%) of 46 Japanese multiple sclerosis patients had antibodies reactive with P15, P19 and P24 gag proteins(1986). However, Hauser et al. (1986) and Karpas et al. (1986) failed to detect any antibody to HTLV-I in the sera and CSF of multiple sclerosis patients. It was suggested that positive reaction of multiple sclerosis patients to HTLV-I may represent antibodies to proteins in human tissue immunologically cross reactive with HTLV-I gag protein.

Necropsy finding of HAM was reported that the predominant change was in the anterior and lateral columns of the thoracic spinal cord and consisted of meningo-myelitis with loss of axons, astrocytosis, and vasculitis(Akizuki et al. 1987).

The pathogenesis of HAM is unknown. Four possible mechanisms in the pathogenesis of HAM are a slow virus infection with direct invasion of the nervous system, a cell mediated immune reaction in the nervous system associated with the presence of ATL-like cells in the CSF, nervous system damage by immunoglobulin through an antibody mediated immune response and viral infection rendering the person vulnerable to secondary infection, particularly of the nervous system(Osame et al. 1987).

It was reported that the prevalence of high anti HTLV-I titer in the residents of endemic areas was much higher than that of nonresidents. The prevalence of serum antibodies to HTLV-I among normal subjects has been found to be 2-4%(de-Thie G et al. 1985). However, as many as 16% of the population in areas of Kyushu, endemic area of HAM, were reported to carry antibodies to HTLV-I (Osame et al. 1986). A total of 710 patients with HAM were reported in Japan in 1989(Osame et al. 1990b).

There are many known possible routes of HTLV-I transmission, including blood transfusion(Minamoto et al. 1988), intrafamilial transmission and presumably a sharing contaminated needle(Robert-Guroff et al. 1986). In the nationwide survey in Japan, significantly more patients with HAM(20%) had a history of blood transfusion than the general population(3%) in the endemic area(Osame et al. 1990b). In intrafamilial transmission, there are two proposed routes. One is a vertical transmission from mother to child(Kondo et al. 1985, Sugiyama et al. 1986) and the other is a horizontal transmission between spouses, especially from husband to wife (Tajima et al. 1982, Zaninovic et al. 1986). There is no definite data supporting female to male transmission(Kim et

et. 1988).

In this aspect, our case is quite unique because he is the first known Korean male patient with HAM in Korea, and his wife is a seropositive Japanese Korean female who lived in the endemic area of HAM, Kyushu. Despite very intimate communications between Korea and Japan, there are no previous known cases of HAM in Korea. This suggests that the infectivity of HTLV-I is quite limited. Considering that the proband did not have any previous transfusion and was not a drug abuser, the most likely possibility would be the horizontal transmission of HTLV-I from his wife through sexual intercourse. We suspect that the horizontal transmission of HTLV-I in a family is not necessarily only male to female. The reverse may also occur.

Therapy of HAM is still controversial. Corticosteroid treatment and other immunotherapies, such as azathioprine, were reported to be helpful in patients with HAM (Osame et al. 1990a). Plasma exchange therapy was also reported beneficial for short-term symptomatic improvement (Matsuo et al. 1989). However, our patient did not show any significant improvement of symptoms with corticosteroid therapy.

REFERENCES

- Akizuki S, Nakazato O, Higuchi Y, Tanabe K, Setoguchi M, Yoshida S, Miyazaki Y, Yamamoto S, Sudou S, Sannomiya K, Okajima T: Necropsy Findings in HTLV-I associated myelopathy. *Lancet* 1: 156-157, 1987
- de-Thé G, Gessain A, Gazzolo L, Robert-Guroff M, Majberg G, Calender A, Peti M, Broubaker G, Bensliman a, Fabry F, Strobel M, Robin Y, Fortune R: Comparative seroepidemiology of HTLV-I and HTLV-III in the French West Indies and some African countries. *Cancer Res* 45: 4633s-4636s, 1985
- Gessain A, Barin F, Vernant JC, Gout O, Maurs L, Calender A, De-Thé G: Antibodies to human T-lymphotropic virus type-I in patients with tropical spastic paraparesis. *Lancet* 2: 407-411, 1985
- Hauser SL, Aubert C, Burks JS, Keer C, Lyon-Caen O, de-Thé G, Brahic M: Analysis of human T-lymphotropic virus sequence in multiple sclerosis tissue. *Nature* 322: 177-178, 1986
- Ikeda M, Fujino R, Matsui T, Yoshiad T, Komoda H, Imai J: A new agglutination test for serum antibodies to adult T-cell leukemia virus. *Gann* 75: 845-848, 1984
- Kakigi R, Shibasaki H, Kuroda Y, Endo C, Oda K, Ikeda A, Hashimoto K: Multimodality evoked potentials in HTLV-I associated myelopathy. *J Neurol Neurosurg Psychiatr* 51: 1094-1096, 1988
- Karpas A, Kampf U, Siden A, Koch M, Poser S: Lack of evidence for involvement of known human retroviruses in multiple sclerosis. *Nature* 322: 177-178, 1986
- Kim JH, Durack DT: Manifestations of human T-lymphotropic virus type I infection. *Am J Med* 84: 919-928, 1988
- Kira J, Minato S, Itoyama Y, Goto I, Kato M, Hasuo K: Leukoencephalopathy in HTLV-I associated myelopathy: MRI and EEG data. *J Neurol Sci* 87: 221-232, 1988
- Kondo T, Nonaka H, Miyamoto, Yoshida R, Matsue Y, Ohguchi Y, Inouye H, Komoda H, Hinuma Y, Hanaoka M: Incidence of adult T-cell leukemia-lymphoma and its familial clustering. *Int J Cancer* 35: 749-751, 1985
- Koprowski H, DeFreitas EC, Harper ME, Sandberg-Wollheim M, Sheremata WA, Robert-Guroff M, Saxinger CW, Feinberg MB, Wong-Staal F, Gallo RC: Multiple sclerosis and human T cell lymphotropic retroviruses. *Nature* 318: 154-160, 1985
- Matsuo H, Nakamura T, Tsujihata M, Motomura M, Nagasato K, Nagataki S: Human T-lymphotropic virus type I (HTLV-I) associated myelopathy in Nagasaki: Clinical features and treatment of 21 cases. *Jpn J Med* 28: 328-334, 1989
- Minamoto GY, Gold JWM, Scheinberg DA, Hardy WD, Chein N, Zuckerman E, Reich L, Dietz K, Gee T, Hoffer J, Mayer K, Gabrilove J, Clarkson B, Armstrong D: Infection with human T cell leukemia virus type I in patients with leukemia. *N Engl J Med* 318: 219-222, 1988
- Miyoshi I, Kubonishi I, Yoshimoto S, Akagi T, Ohtsuki Y, Shiraishi Y, Nagata K, Hinuma Y: Type C virus particles in a cord T-cell line derived by co-cultivating normal human cord leukocytes and human leukemic T cells. *Nature* 294: 770-771, 1981
- Ohta M, Ohta K, Mori F, Nishitani H, Saida T: Sera from patients with multiple sclerosis react with human T cell lymphotropic virus-I gag proteins but not env proteins-western blotting analysis. *J Immunol* 137: 3440-3443, 1986
- Osame M, Igata A, Matsumoto M, Kohka M, Usuku K, Izumo S: HTLV-I-associated myelopathy (HAM), treatment trials, retrospective survey and clinical and laboratory findings. *Hematol Reviews* 3: 271-284, 1990a
- Osame M, Janssen R, Kubota H, Nishitani H, Igata A, Nagataki S, Mori M, Goto I, Shimabukuro H, Khabbaz R, Kaplan J: Nationwide survey of HTLV-I-associated myelopathy in Japan: Association with blood transfusion. *Ann Neurol* 28: 50-56, 1990b
- Osame M, Matsumoto M, Usuki K, Izumo S, Iijichi N, Amitani H, Tara M, Igata A: Chronic progressive myelopathy associated with elevated antibodies to human T-lymphotropic virus type I and adult T cell

- leukemialike cells. *Ann Neurol* 21 : 117-122, 1987
- Osame M, Usuku K, Izumo S, Ijichi N, Amitani, H, Igata A, Matsumoto M, Tara M : HTLV-I associated myelopathy, a new clinical entity. *Lancet* 1 : 1031-1032, 1986
- Poiesz BJ, Ruscetti FW, Gazdar AF, Bunn Pa, Minna JD, Gallo RC : Detection and isolation of type C retrovirus particles from fresh and cultured lymphocytes of a patient with cutaneous T-cell lymphoma. *Proc Natl Acad Sci USA* 77 : 7415-7419, 1980
- Robert-Guroff M, Weiss SH, Giron JA, Jennings M, Ginzburg HM, Margolis IB, Blattner WA, Gallo RC : Prevalence of antibodies to HTLV-I, -II and -III in intravenous drug abusers from an AIDS endemic region. *JAMA* 255 : 3133-3137, 1986
- Rodgers-Johnson P, Gajdusek DC, Morgan OSC, Zaninovic V, Sarin PS, Graham DS : HTLV-I and HTLV-III antibodies and tropical spastic paraparesis. *Lancet* 2 : 1247-1248, 1985
- Roman GC, Osame M : Identity of HTLV-I- associated tropical spastic paraparesis and HTLV-I-associated myelopathy. *Lancet* 1 : 651, 1988
- Roman GC : Retrovirus-associated myelopathy. *Arch Neurol* 44 : 659-663, 1987
- Sugiyama H, Doi H, Yamaguchi K, Tsuji Y, Miyamoto T, Hino S : Significance of postnatal mother-to-child transmission of human T-lymphotropic virus type-I on the development of adult T-cell leukemia/lymphoma. *J Med Virol* 20 : 253-260, 1986
- Tajima K, Tominaga S, Suchi, T, Kawage T, Komoda H, Hinuma Y, Oad T, Fujita K : Epidemiological analysis of the distribution of antibody to adult T-cell leukemia-virus-associated antigen : possible horizontal transmission of adult T-cell leukemia virus. *Cann* 73 : 893-901, 1982
- Zaninovic V : A possible sexually transmitted viral myeloneuropathy. *Lancet* 2 : 697-698, 1986
-