

## Sclerotherapy with OK-432 for Recurrent Cystic Thyroid Nodule

Hang-Seok Chang, Jong Ho Yoon, Woung Youn Chung,  
and Cheong Soo Park

*We have adopted OK-432 as a sclerosing agent in the treatment of cystic predominant thyroid nodules and have analyzed our findings to assess the efficacy of intralesional instillation of OK-432. From 1992 through 1993, 48 patients with recurrent or progressive cystic thyroid nodules after 2 or 3 aspirations alone, and whom were cytologically negative for malignancy, were used for this study. The OK-432 solution was prepared by dissolving 0.1 mg of OK-432 in 2 ml of physiologic saline and it was instilled in the amount of 1/10-to-1/5 of the aspirated cystic fluid. A repeated course of therapy was given up to 3 times when sufficient resolution was not obtained 4-to-6 weeks after treatment. The mean number of treatment sessions per patient was 1.5. Throughout the follow-up period from 30-to-45 months (mean, 38 months), 32 (66.7%) patients experienced an almost complete disappearance (<0.5 cm in diameter) of the cystic lesion, and 12 (25%) patients responded partially by having it decrease by more than half (>0.5 cm in diameter) of the initial cyst size, and none of these patients required further treatment. The remaining 4 (8.3%) patients showed insufficient resolution despite 3 courses of therapy and 2 of these patients underwent thyroidectomy, in which the lesion proved benign in both cases. All of the patients tolerated the sclerotherapy well. No significant local complications attributed to this treatment were observed. However, a low-grade fever was observed in 26 (54.2%) patients for 2 to 5 days after instillation, which subsided with symptomatic treatment. On the basis of our experience, OK-432 sclerotherapy appears to be safe, simple and effective, and can be a useful alternative treatment for cystic thyroid nodules.*

**Key Words:** Thyroid cyst, OK-432, sclerotherapy

Purely or partially cystic thyroid nodules account for 6~26% of all solitary thyroid nodules (Miskin *et al.* 1973; Gobien, 1979). Such lesions are most often benign, although, as Crile (1966) pointed out,

thyroid carcinoma may occasionally present as a purely cystic nodule (Miller *et al.* 1974). Fine needle aspiration (FNA) has been routinely performed for diagnostic or therapeutic purposes. However, cystic recurrence is not uncommon even after repeated aspiration, often leading to subsequent surgical excision (Miller *et al.* 1974; Jensen and Rasmussen, 1976). To reduce the high rate of relapse after FNA, both suppressive levothyroxine therapy (McCowen *et al.* 1980) and percutaneous injection of several sclerosing agents have been proposed with conflicting results (Sykes, 1981; Ryan *et al.* 1982; Edmonds and Tellez, 1987; Hegedus *et al.* 1988; Yasuda *et al.* 1992). Until now, only anecdotal reports of success were available (Crile and Hawk, 1973; Ryan

Received June 1, 1998

Accepted July 22, 1998

Department of Surgery, Institute of Endocrinology,  
Yonsei University College of Medicine, Seoul, Korea

This paper was presented at the 6th Biennial Congress  
of the Asian Association of Endocrine Surgeons, March  
26-29, 1988, Kuala Lumpur, Malaysia

Address reprint request to Dr. C.S. Park, Department  
of Surgery, Yonsei University College of Medicine,  
C.P.O. Box 8044, Seoul 120-752, Korea. Tel: 361-5540,  
Fax: 313-8289, e-mail: ysurg@yumc.yonsei.ac.kr

*et al.* 1982). We have adopted OK-432 as a sclerosing agent in the treatment of cystic thyroid nodules and have analyzed our findings to assess the efficacy of intra-lesional instillation of OK-432.

## MATERIALS AND METHODS

Forty-eight consecutive patients (42 women, 6 men) from 1992 through 1993, with recurrent or progressive cystic predominant thyroid nodules (the proportion of cystic component was more than 90% in ultrasonographic findings), despite 2 or 3 simple aspirations, were enrolled in this study. Their ages ranged from 17 to 87 years with a mean age of 39 years.

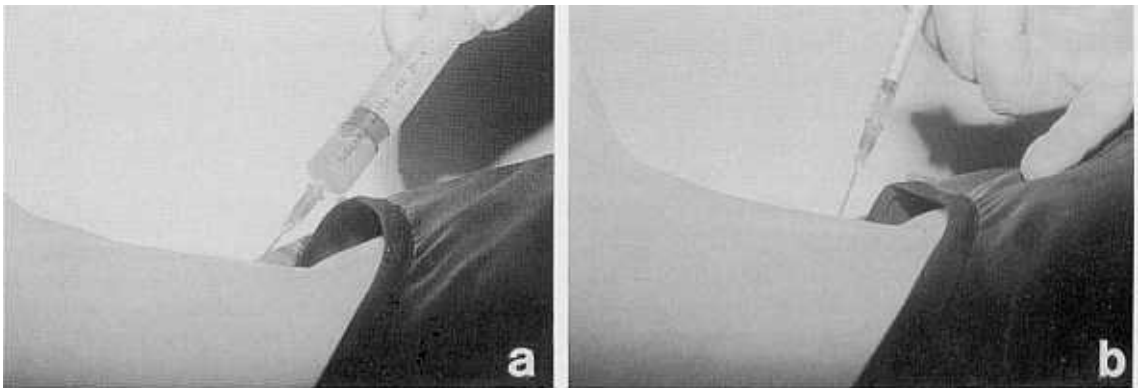
All patients were clinically and biochemically euthyroid, and cytologically negative for malignancy by repeated fine needle aspiration biopsy (FNAB). All patients were examined with ultrasonography using a 7.5 or 10 MHz transducer. FNA was performed in a supine position with a slightly hyper-extended neck position. After skin sterilization, the cystic fluid was aspirated completely using a 19-gauge needle fitted to a disposable plastic syringe. The OK-432 solution was prepared by dissolving 0.1 mg of OK-432 (Chungai Pharmaceutical Co., Tokyo, Japan) in 2 ml of physiologic saline. A syringe containing dissolved OK-432 solution was then substituted for the aspirating syringe without

removing the needle. Thereafter, OK-432 was slowly instilled in the amount of 1/10-to-1/5 of the aspirated cystic fluid (Fig. 1). After instillation, a small pressure dressing was applied for 2 hours. Patients remained under observation for 15 minutes. A repeated course of therapy was given up to 3 times when sufficient resolution was not obtained 4-to-6 weeks after treatment.

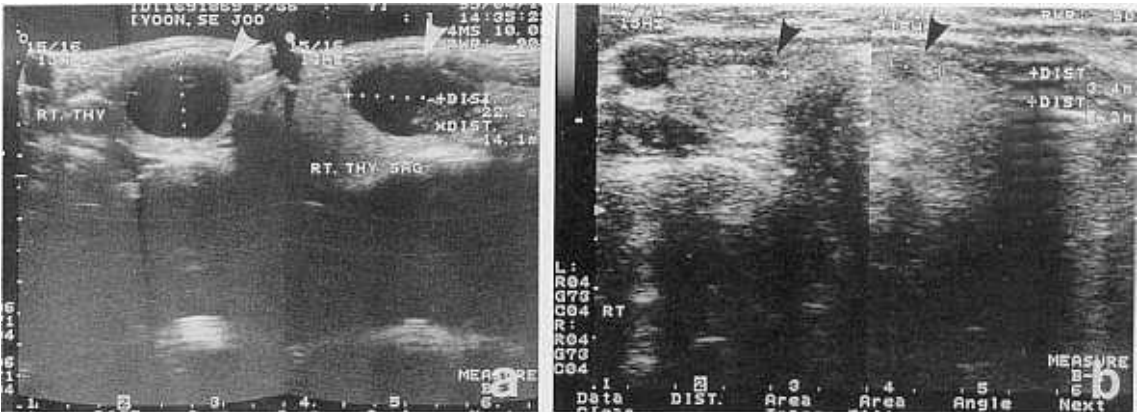
All patients were followed-up at 1, 3, 6, and 12 months or longer after their last treatment. The responses to the sclerotherapy were evaluated by the measurement of the reduced cyst size using ultrasonography at the time of the last follow-up. The responses were categorized by the diameters of residual nodules as follows; 1) near-complete response: less than 5 mm in diameter, 2) partial response: 5 to 10 mm in diameter, and 3) insufficient response: more than 10 mm in diameter.

## RESULTS

The mean number of treatment sessions per patient was 1.5 times. Throughout the follow-up period from 30 to 45 months (mean; 38 months), 32 (66.7%) patients experienced a near-complete response of cystic lesions, and 12 (25.0%) patients responded partially and none of these patients required further treatment (Fig. 2). The remaining 4 (8.3%) showed insufficient resolution despite 3



**Fig. 1.** The procedures of aspiration and instillation of OK-432; a) Aspiration of the cystic fluid with a 19 gauge needle. b) The syringe is changed after aspiration and instillation of OK-432 is slowly undertaken.



**Fig. 2.** The ultrasonographic findings of the pre and post-treatment state (An example of a near-complete response case); a) A cystic lesion on the right thyroid gland measuring 2.2X1.4 cm in size. b) The cystic nodule is reduced to minimal size after sclerotherapy with OK-432.

courses of therapy and 2 of them underwent thyroidectomy, in which the lesions proved to be adenomatous hyperplasia without any evidence of fibrosis or inflammatory reaction in histological examination. All of the patients tolerated the sclerotherapy well. No significant local complications attributed to this treatment were observed. However, a low-grade fever was observed in 26 (54.2%) patients for 2 to 5 days after instillation of OK-432, but it subsided with symptomatic treatment.

## DISCUSSION

Needle aspiration as a treatment for cystic thyroid nodule was reintroduced to modern medicine by Crile (1966). This conservative non-surgical approach to treatment of thyroid cyst seems justified in light of the low incidence of primary thyroid cancer in these lesions (Crile, 1966; Miller *et al.* 1974; Ma and Ong, 1975). However, a firm cytologic diagnosis is mandatory when the cyst recurs or a residual mass persists after aspiration (de los Santo *et al.* 1990). Thus, a careful preliminary cytological evaluation should be carried out before performing a conservative treatment of cystic thyroid nodules.

Empirically, many unnecessary thyroidectomies have been obviated by using simple aspiration as the initial therapy for thyroid cyst (Treece *et al.* 1983).

Aspiration *per se* may cure a cystic nodule and the reported efficacy ranges between 42~94% (Crile, 1966; Miller *et al.* 1974; Jensen and Rasmussen, 1976; Clark *et al.* 1979). However, the actual therapeutic effectiveness of the procedure can be hampered by frequent reaccumulation of the fluid component of the nodule (Miller *et al.* 1974; Jensen and Rasmussen, 1976; Galvan and Maurer, 1977).

Various modalities of treatment have been proposed to reduce the relapse rate of cystic thyroid nodules. Thyroid hormone administration has been reported to be ineffective (McCowen *et al.* 1980), and this therapy may be associated with long-term side effects such as osteoporosis or cardiac arrhythmia (Forfar *et al.* 1979; Ribot *et al.* 1990; Tealman *et al.* 1990).

A sclerotherapy by means of percutaneous instillation of sclerosing agents into the cysts, such as sodium tetradecyl sulphate and hydroxy-polyethoxy-dodecan (Edmonds and Tellez, 1987; Monzani *et al.* 1994), or tetracycline (Ryan *et al.* 1982; Treece *et al.* 1983; Hegedus *et al.* 1988) has produced conflicting results. The results of a randomized trial demonstrated that tetracycline instillation was no more effective than isotonic saline in treating thyroid cysts (Hegedus *et al.* 1988). Moreover, tetracycline instillation therapy occasionally caused severe pain or vocal-cord paralysis due to extravasation of the drug (Ryan and Dwarakanathan, 1986; Treece *et al.* 1986). Sclerotherapy using pure eth-

**Table 1. Treatment results of cystic thyroid nodules with sclerotherapy**

Author	Sclerosing agents	Patients treated(n)	Success rate(%)
Sykes (1981)	Tetracycline-sulphate	75	95
Ryan <i>et al</i> (1982)	Tetracycline	1	100
Treece <i>et al</i> (1983)	Tetracycline	9	78
Edmonds and Tellez (1987)	Tetracycline	10	62
Hegedus <i>et al</i> (1988)	Tetracycline, saline	23	43
Rozman <i>et al</i> (1989)	Ethanol	13	77
Yasuda <i>et al</i> (1992)	Ethanol	61	72
Monzani <i>et al</i> (1994)	Ethanol	20	95
Verde <i>et al</i> (1994)	Ethanol	24	80
Current Data (1998)	OK-432	48	91.7

anol instillation has been reported to be more effective than simple aspiration alone. The range of efficacy rates was 72~95% (Rozman *et al.* 1989; Yasuda *et al.* 1992; Monzani *et al.* 1994; Verde *et al.* 1994). However, sclerotherapy with ethanol also has some side effects such as local or jaw pain, vocal-cord paralysis, or local hematoma (Monzani *et al.* 1994). In addition, the development of thyrotoxicosis after instillation of ethanol was reported recently, which may be caused by the elevation of thyroid hormone due to ethanol-induced damage to follicular cells (Monzani *et al.* 1992; Papini *et al.* 1993). The reports on the results of sclerotherapy for cystic thyroid nodules are summarized in Table 1.

OK-432 is the lyophilized incubation mixture of the low virulent Su strain of type III, group A *Streptococcus pyogenes* of human origin with penicillin G potassium which has lost its streptolysin S-producing ability (Ishida and Hoshino, 1985). It is routinely administered intradermally or intravenously as a biological response modifier (Ishida and Hoshino, 1985). This potent biological response modifier augments various cytotoxic effector cells and induces immunostimulatory cytokines (Ishida and Hoshino, 1985; Talmadge and Herberman, 1986).

There have been several reports of OK-432 used as a sclerosant for malignant ascites, malignant pleural effusion, and unresectable cystic hygroma

(Nakao, 1982; Torisu *et al.* 1983; Ishida and Hoshino, 1985). The reason that this drug was used first as a sclerosant is because intradermal injection of OK-432 caused a moderate-to-marked inflammatory reaction at the injection site in almost all cases without causing damage to the skin or scar formation, and it caused no serious side effects even if it was injected via the jugular vein (Hanaue *et al.* 1985; Ishida and Hoshino, 1985). The mechanism of the therapeutic effect of OK-432 as a sclerosant in cystic lesion is probably due to damage to the endothelial lining by chemical stimulation of the tissue, consequently preventing further accumulation of fluid within the lesion and causing shrinkage of the cystic lesion as a result (Torisu *et al.* 1983). In our series, two patients who did not respond to OK-432 sclerotherapy underwent thyroidectomy, of which the histologic features of the nodules showed no fibrosis or inflammatory changes. We think that there are several reasons responsible for these findings; first, both of the patients were operated on 5 or 6 weeks after the last session of sclerotherapy and the inflammatory reaction or fibrosis caused by the sclerosing agent may have been resolved for the time being. Second, the non-refractory cysts may have had considerable solid components and the concentration of OK-432 was not high enough to sclerose the solid portion of the cystic nodule. Furthermore, the effect of OK-432 in the treatment of cystic thyroid nodule is mainly caused by the sclerosis of the endothelial lining of the cyst, and not by the destruction of the solid portion.

In our series, the sclerotherapy with OK-432 showed excellent results; the response rate was 91.7%. All patients except 4 had a completely satisfactory response after 1 or 2 sessions. Compared with other sclerosing agents, OK-432 sclerotherapy was only responsible for a low-grade fever as a side effect, but the febrile symptom was easily controlled by symptomatic treatment measures. There were no significant other side effects such as tissue necrosis or vocal cord paralysis from leakage of the sclerosing agent, which is not uncommon in ethanol or tetracycline instillation.

In conclusion, sclerotherapy with OK-432 appears to be safe, simple and effective, and it can be a useful alternative treatment for cystic thyroid nodules.

## REFERENCES

- Clark OH, Okerlund MD, Cavalieri RP, Greenspan FS: Diagnosis and treatment of thyroid, parathyroid and thyroglossal duct cysts. *J Clin Endocrinol Metab* 48: 983-988, 1979
- Crile G: Treatment of thyroid cyst by aspiration. *Surgery* 59: 210-212, 1966
- Crile G, Hawk WA: Aspiration biopsy of thyroid nodules. *Surg Gynecol Obstet* 136: 241-245, 1973
- de los Santos ET, Keyhani-Rofaga S, Cunningham JJ, Mazzaferri EL: Cystic thyroid nodules. the dilemma of malignant lesions. *Arch Intern Med* 150: 1422-1427, 1990
- Edmonds CJ, Tellez M: Treatment of thyroid cyst by aspiration and injection of sclerosant. *Br Med J* 295: 529, 1987
- Forfar JC, Miller HC, Toft AD: Occult thyrotoxicosis: a correctable cause of 'idiopathic' atrial fibrillation. *Am J Cardiol* 44: 9-12, 1979
- Galvan G, Maurer H: Emptying of goitre cysts by small needle aspiration. *Duetsche Medizinische Wochenschrift* 102: 829-830, 1977
- Gobien RP: Aspiration biopsy of the solitary thyroid nodule. *Radiol Clin North Am* 17: 543-554, 1979
- Hanaue H, Kurosawa T, Miyakawa S, Horie F, Nemoto A, Nishimura S, Yamato H, Yasuda H, Asagoe J, Miura S: Immunohistological studies of the skin at the injection site of cases receiving the streptococcal agent OK-432. *J Jpn Soc Cancer Ther* 20: 2271-2278, 1985
- Hegedus L, Hansen JM, Karstrup S, Torp-Pederson S, Juul N: Tetracycline for sclerosis of thyroid cyst. A randomized study. *Arch Intern Med* 148: 1116-1118, 1988
- Ishida N, Hoshino T: A *Streptococcal preparation as a potent biological response modifier OK-432*. 2nd ed. Amsterdam, Excerpta Medica, 1985, 1-5
- Jensen F, Rasmussen SN: The treatment of thyroid cysts by ultrasonically guided fine needle aspiration. *Acta Chirurgica Scandinavica* 142: 209-211, 1976
- Ma MKG, Ong GB: Cystic thyroid nodules. *Br J Surg* 62: 206-206, 1975
- McCowen KD, Reed JW, Fariss BL: The role of thyroid therapy in patients with thyroid cysts. *Am J Med* 68: 853-855, 1980
- Miller JM, Zafar SU, Karo JJ: The cystic thyroid nodule: recognition and management. *Radiology* 110: 257-261, 1974
- Miskin M, Rosen IB, Walfish PG: B-mode ultrasonography in assessment of thyroid gland lesion. *Ann Intern Med* 79: 505-510, 1973
- Monzani F, Goletti O, Caraccio N, Del Guerra P, Ferdeghini M, Pucci E, Baschieri L: Percutaneous ethanol injection treatment of autonomous thyroid adenoma: hormonal and clinical evaluation. *Clin Endocrinol* 36: 491-497, 1992
- Monzani F, Lippi F, Goletti D, Del Guerra P, Caraccio N, Lippolis PV, Baschieri L, Pinchera A: Percutaneous aspiration and ethanol sclerotherapy for thyroid cysts. *J Clin Endocrinol Metab* 78: 800-802, 1994
- Nakao K: Study on treatment of pleural carcinomatosis with special reference to effect of OK-432. *Chiba Med* 58: 345-353, 1982
- Papini E, Panunzi C, Pacella CM, Bizzarri G, Fabbri R, Petrucci L, Piscichio G, Nardi F: Percutaneous ultrasound-guided ethanol injection: a new treatment of toxic autonomously functioning thyroid nodules. *J Clin Endocrinol Metab* 76: 411-416, 1993
- Ribot C, Tremolieres F, Ponilles JM, Juvet JP: Bone mineral density and thyroid hormone therapy. *Clin Endocrinol* 33: 428-436, 1990
- Rozman B, Bence-Zimman Z, Tomic-Brzac H, Skreb F, Pavlinovic Z, Simonovic I: Sclerosis of thyroid cysts by ethanol. *Periodicum Biologorum* 91: 453-456, 1989
- Ryan WG, Dwarakanathan A: Minor complication of thyroid cyst sclerosis with tetracycline. *Arch Intern Med* 146: 201-202, 1986
- Ryan WG, Schwartz TB, Harris J: Sclerosis of thyroid cysts with tetracycline(letter). *N Engl J Med* 308: 157, 1982
- Sykes D: The solitary thyroid nodule. *Br J Med* 68: 510-513, 1981
- Talmadge JE, Herberman RB: The preclinical screening laboratory: evaluation of immunomodulatory and therapeutic properties of biological response modifiers. *Cancer Treat Rep* 70: 171-182, 1986
- Tealman P, Kaufman JM, Janssen X, Vandeauter H, Vermeulen A: Reduced forearm bone mineral content and biochemical evidence of increased bone turnover in women with euthyroid goitre treated with thyroid hormone. *Clin Endocrinol* 33: 107-117, 1990
- Toritsu M, Katano M, Kimura Y, Itoh H, Takesue T: New approach to management of malignant ascitis with a streptococcal preparation, OK-432. *Surgery* 93: 357-364, 1983
- Treece GL, Georgitis WJ, Hofeldt FD: Resolution of recurrent thyroid cysts with tetracycline instillation. *Ach Intern Med* 143: 2285-2287, 1983
- Treece GL: Reply to Drs Ryan and Dwarakanathan. *Arch Intern Med* 146: 202, 1986
- Verde G, Papini E, Pacella CM, Gallott C, Delplano S, Strada S, Fabbri R, Bizzarri G, Rinaldi R, Panuzi C, Gelli D: Ultrasound guided percutaneous ethanol injection in the treatment of cystic thyroid nodules. *Clin Endocrinol* 41: 719-724, 1994
- Yasuda K, Ozaki O, Sugino K, Yamashita T, Toshima K, Ito K, Harada T: Treatment of cystic lesions of the thyroid by ethanol instillation. *World J Surg* 16: 958-961, 1992