

# Percutaneous Transluminal Coronary Angioplasty for Ostial Stenosis of the Left Coronary Artery

— A case report and literature review —

Hae-Yong Lee

*A 11-year-old girl developed left main coronary artery ostial stenosis after Takayasu's arteritis for which she underwent Percutaneous Transluminal Coronary Angioplasty(PTCA). The narrowing of the left coronary artery was successfully dilated by angioplasty without apparent complication.*

*This case suggests that PTCA may have a potential advantage as a temporary method to postpone the aortocoronary bypass surgery in a child with coronary artery stenosis due to Takayasu's arteritis*

**Key Words:** Takayasu's arteritis, percutaneous transluminal coronary angioplasty, coronary artery stenosis

In Takayasu's arteritis, coronary arterial involvement may be as high as 7%(Lupi-Herrera *et al.* 1977) by coronary arteriography or at necropsy, young female patients are most commonly affected. In patients with these obstructive lesions, aortocoronary bypass surgery may sometimes be required to preserve ventricular function(Suzuki *et al.* 1985; Morgan *et al.* 1987), however, the long term patency rate of the bypass graft remains unsatisfactory(Invert *et al.* 1988), especially in children. In this report, we present the case of a young girl with Takayasu's arteritis in whom left coronary ostial stenosis was demonstrated by angiography and her anginal pain was relieved by Percutaneous Transluminal Coronary Angioplasty (PTCA).

## CASE REPORT

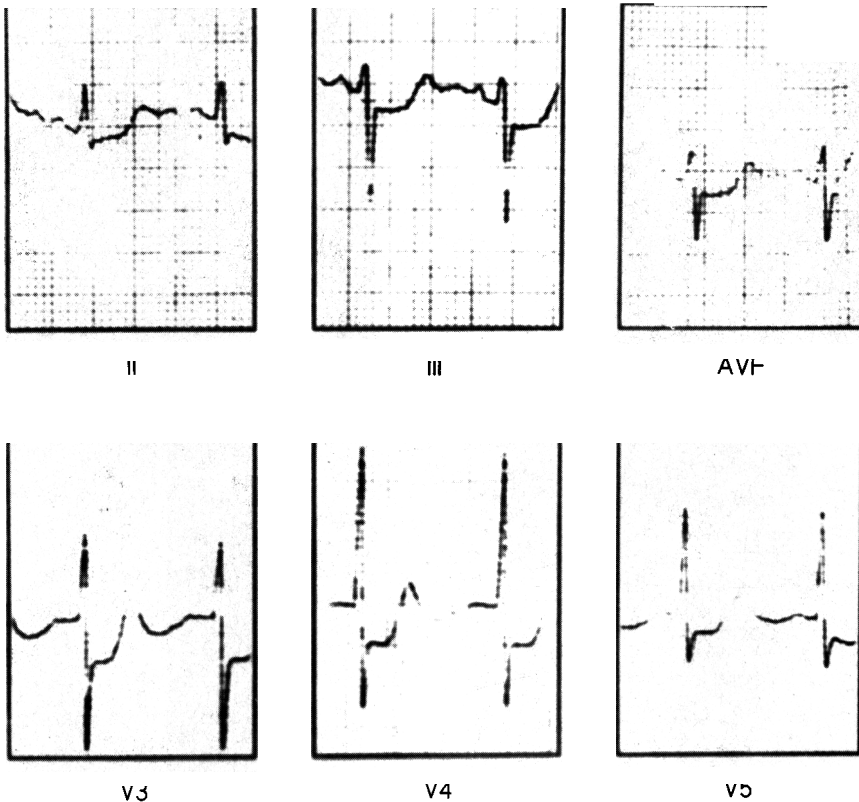
A 11-year-old girl was admitted because of syncope after exercise. She had been well until 6 months prior to admission, when she noted sharp chest pains on exertion that increased progressively. On physical examination, the patient appeared ill-looking with and no evidence of systemic disease. Her blood pressure was 100/70mmHg and her pulse rate was 88 beats/min in the right upper extremity but the left brachial and radial pulses were not palpable. Blood pressure of lower extremities were 118/72 mmHg in the right lower extremity and 122/72 mmHg in the left lower extremity. Murmur and bruit were not audible on the abdomen. Laboratory studies revealed normal urinalysis, normal blood count, and normal serum lipid levels. Serologic tests were negative for both C-reactive protein and syphilis. The erythrocyte sedimentation rate was 46 mm/hr. All indexes of collagen disorders including LE cell, antinuclear antibody, and rheumatoid factor were negative. The resting electrocardiogram was normal, but, on

Received September 7, 1995

Accepted October 25, 1995

Department of Pediatrics, Yonsei University, Wonju College of Medicine, Wonju, Korea

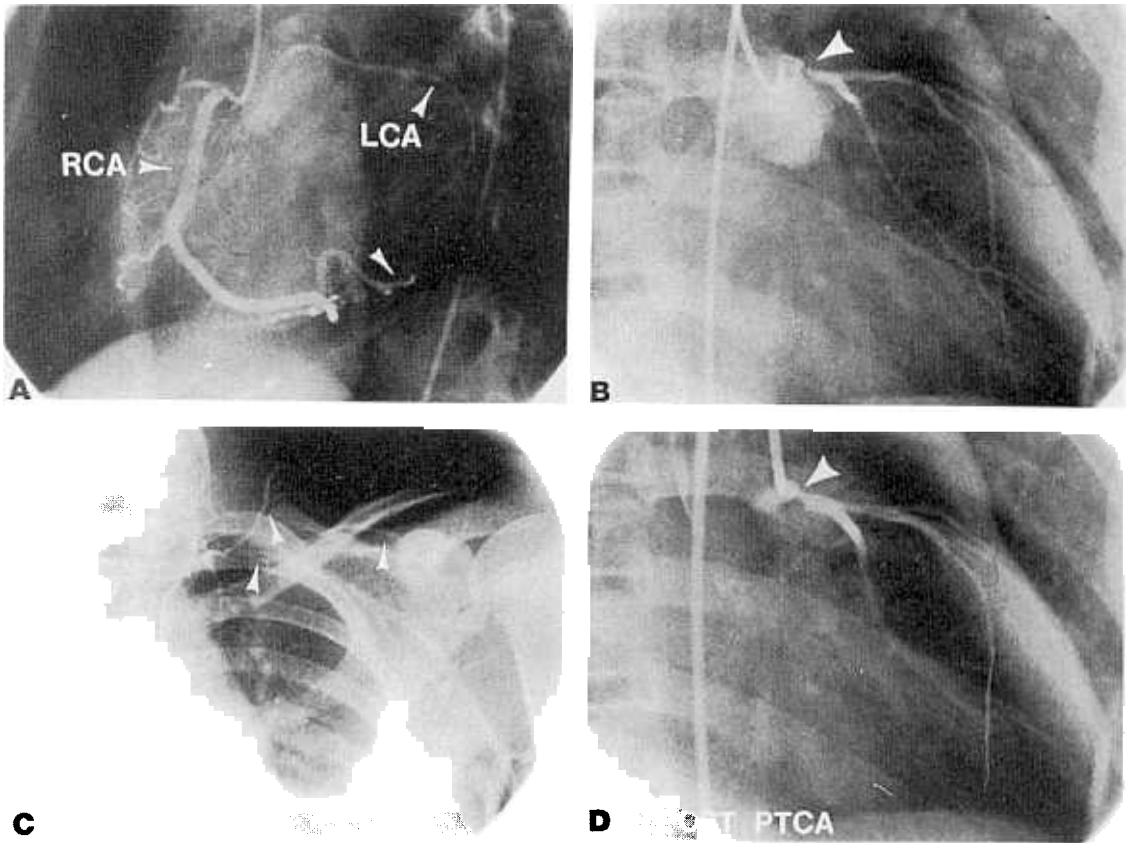
Department of Pediatrics, Wonju Christian Hospital, Yonsei University, Wonju College of Medicine, 162 Ilsan-Dong, Wonju, Korea 220-701, Office:371-41-1286, Fax: 371-732-6229



*Fig. 1. Electrocardiograms at mild exercise (Bruce Stage 1, 1.7 mph at a grade of 10%), ST depression appeared in leads II, III, AVF, V<sub>3</sub>, V<sub>4</sub>, V<sub>5</sub> and V<sub>6</sub>.*

treadmill testing, she developed chest pain during mild exercise (Bruce Stage 1, 1.7 mph at a grade of 10%) associated with significant ST segment depression of 2 to 6 mm in leads II, III, AVF, and V<sub>3</sub> to V<sub>6</sub>, together with a decrease in systolic blood pressure (Fig. 1). Selective coronary arteriograms revealed a 90% left coronary ostial stenosis (Fig. 2B) with collateral flow from the right coronary artery to the anterior descending coronary artery (Fig. 2A). The remaining coronary artery tree was normal. Aortic arch arteriogram revealed complete occlusion of the left subclavian artery with well developed collateral from the vertebral artery and ascending cervical artery (Fig. 2C). There was no abnormal angiographic finding in the thoracic and abdominal aorta. The angiographic evidence suggested a potential risk of sudden death by acute myocardial

infarction and therefore, PTCA was performed. A balloon angioplasty catheter was introduced by a 7-F guiding catheter (SCIMED, Co Ltd., Maple Grove, Minnesota, U.S.A.) with a 0.14" steerable guide (ACS, Co Ltd., Temecula, California, U.S.A.) wire. The balloon was inflated with diluted contrast material to 6 and 9 atm pressure. The duration of inflation was approximately 80 seconds at each dilation, and the procedure was repeated twice. Repeat angiography after PTCA showed a 40% residual left coronary ostial stenosis (Fig. 2D). Transient depression of the ST segment in lead II, III and AVF was observed during the procedure. No complications were encountered during and after the procedure. Corticosteroid therapy (prednisone, 10 to 30 mg/day for 6 months) was begun, with resultant normalization of the ESR. Follow up treadmill



**Fig. 2.** Right coronary (RCA) arteriogram showing collateral flow to left coronary (LCA) system (A). Left coronary arteriogram before PTCA showing a severe ostial stenosis (B). Aortogram showing complete occlusion of left subclavian artery with well developed collateral from the vertebral artery and ascending cervical artery (C). The stenosis was well dilated shortly after PTCA (D); mild residual obstruction persists.

testing 2 months after the procedure revealed electrocardiographic changes during moderate exercise (Bruce Stage 5, 50 mph at a grade of 18%) associated with significant ST segment depression of 2 to 4 mm in leads II, III, AVF, and  $V_2$  to  $V_6$  and no chest pain developed. The post PTCA clinical course was uncomplicated and the patient remains asymptomatic over a year following balloon angioplasty.

## DISCUSSION

Takayasu's Arteritis is an inflammatory disorder of the aorta with unknown specific eti-

ology, and the fibrous intimal proliferation produces narrowing or obstruction of main branches of the aorta, including coronary artery ostia. Coronary artery disease is a rare involvement of Takayasu's arteritis. The incidence of coronary artery involvement has been reported to be 8.5% in Korea (Park *et al.* 1992) and 9% in Japan (Matsubara *et al.* 1992), and is observed mainly in autopsy cases because coronary artery disease is usually not evident until the occurrence of angina pectoris or myocardial infarction, or after the onset of congestive heart failure. From 1961 to 1991, 68 patients have been reported to undergo operations for coronary artery disease resulting from Takayasu's arteritis. Operative mortality

was eight(12.3%) and operation was repeated in two patients because of graft failure(2.8%) (Amano and Sujuki, 1991). The long term patency of coronary artery bypass graft(CABG) is 78% in Takayasu's arteritis (Kano *et al.* 1992).

Recently, balloon angioplasty of the aorta in Takayasu's arteritis has produced good results both immediately after and on long term follow up. Commonly, though not invariably, a small intimal tear or stretching that is observed after successful angioplasty may underlie the mechanism of angioplasty in Takayasu's arteritis(Sanjay *et al.* 1992). No aneurysm developed at the site of angioplasty after balloon dilatation of the aorta in patients with Takayasu's arteritis, in contrast to occasional aneurysms that are observed after angioplasty for coarctation of the aorta. This could be due to this markedly thickened vessel wall caused by inflammatory fibrosis of all three layers as observed in Takayasu's arteritis(Virmamani *et al.* 1986). To our knowledge, this is the first case of PTCA for coronary artery stenosis in Takayasu's arteritis. Hitherto, PTCA in Kawasaki disease has been reported. In one case who had undergone PTCA for coronary artery stenosis in Kawasaki disease, death resulted due to the obstruction of the left coronary artery immediately after balloon rupture caused by a high inflating pressure. The other two were successfully dilated(Echigo, 1988; Toshihiro *et al.* 1991). Pathologic findings are different between Kawasaki disease and Takayasu's arteritis. In Kawasaki disease, pathologic findings of the vessel is marked intimal thickening, so intimal tearing during angioplasty may rupture of vessel directly, but there may lesser vessel rupture in Takayasu's arteritis because of fibrotic thickening of all three layers of the vessel.

This case suggests that PTCA may well be an effective alternative method to aortocoronary bypass surgery for coronary artery stenosis in Takayasu's arteritis.

## REFERENCES

- Amano J, Sujuki A: Coronary artery involvement in Takayasu's arteritis. *J Thorac Cardiovasc Surg* 102: 554-560, 1991
- Echigo S: PTCA In Abstracts of the 3rd International Kawasaki Disease Symposium. Tokyo, 1988, 64
- Ino T, Nishimoto N, Akimoto K, Park I, Shmajaki S, Yabuta K, Yamaguchi H: Percutaneous transluminal coronary angioplasty for Kawasaki disease: A case report and literature review. *Pediatr Cardiol* 12: 33, 1991
- Invert T, Huttunen K, Landou X, Bjork VO: Angiographic studies of internal mammary artery grafts after coronary bypass grafting. *J Thorac Cardiovasc Surg* 96: 1, 1988
- Kano T, Kobayashi S, Uamanaka O, Kasuya H, Ozaki H, Wakiya Y, Amano J, Sujuki A: A long-term result of coronary artery bypass on coronary ostial stenosis secondary to Takayasu's disease. *Respiration & Circulation* 40: 621-626, 1992
- Lupi-Herrera E, Sanchez-Torres G, Marcusshamer J, Mispireta J, Horwitz S, Vela J E: Takayasu's arteritis clinical study of 107 cases. *Am Heart J* 93: 94-103, 1977
- Matsubara O, Kuwata T, Nemoto T, Kasuga T, Numano F: Coronary artery lesions in Takayasu's arteritis. *Heart Vessels Suppl* 7: 26-31, 1992
- Morgan J M, Honey M, Gray H H, Belcher P, Paneth M: Angina pectoris in a case of Takayasu's disease: revascularization by coronary osteoplasty and bypass grafting. *Eur Heart J* 8: 1354, 1987
- Park TB, Hong SK, Choi KJ, Shon DW, Oh BH, Lee MM, Choi US, Seo JD, Lee UW, Park JH: Takayasu's arteritis in Korea. *Heart Vessels Suppl* 7: 55-59, 1992
- Suzuki A, Kitamura T, Ona Y, Takahashi N, Naito Y, Koh Y: Indication of aortocoronary bypass for coronary arterial obstruction due to Kawasaki disease. *Heart Vessels* 1: 94, 1985
- Tyagi S, Kaul UA, Nair M, Sethi KK, Arora R, Khalilullah M: Balloon angioplasty of the aorta in Takayasu's arteritis: initial and long term results. *Am Heart J* 124: 876, 1992
- Virmamani R, Lande A, McAllister HA: Pathological aspects of Takayasu's arteritis. In Lande A, Berkmen YM, McAllister HA, eds. Aortitis: clinical, pathologic and radiographic aspects. New York, Raven, 1986, 56