

## GM-CSF and Low-dose AraC Treatment of AML in Prolonged Hypoplasia with Residual Leukemic Cells after Induction Chemotherapy

Yoo Hong Min, Sung Eun Kim, Seung Tae Lee, Sun Ju Lee  
Jee Sook Hahn and Yun Woong Ko

*We describe a case with acute myelogenous leukemia (AML; M2) who developed prolonged marrow hypoplasia with residual leukemic blasts and recurrent infections after induction chemotherapy. He was treated successfully with a sequential treatment of recombinant human granulocyte-macrophage colony-stimulating factor (rhGM-CSF) and low-dose cytosine arabinoside (LD AraC). To the best of our knowledge this is the first reported case of a successful treatment of a patient with AML, who showed prolonged markedly hypocellular bone marrow with significant residual leukemic cells after induction chemotherapy, with a sequential treatment of GM-CSF and LD AraC.*

**Key Words:** Acute myelogenous leukemia, GM-CSF, low-dose Ara-C

A minority of patients with acute myeloid leukemia (AML) regenerate with blasts having passed through a period of hypoplasia, or attain marrow hypocellularity with residual leukemic cells which persists for more than four weeks after induction chemotherapy (Preisler 1978). In that latter type of failure, treatment is usually troublesome, especially complicated by recurrent, severe infections and dysplasia of the erythroid, granulocytic, or megakaryocytic lineage that might herald leukemic regrowth (Cheson *et al.* 1990). It seems rather inappropriate to administer reinduction chemotherapy for decreasing residual leukemic hemopoiesis because that kind of therapy will increase chemotherapy-induced toxicities such as infection and hemor-

rhage. We describe a patient with AML (M2) who developed prolonged marrow hypoplasia with residual leukemic blasts and recurrent infections after induction chemotherapy and was treated successfully with sequential recombinant human granulocyte-macrophage colony-stimulating factor (GM-CSF) and low-dose cytosine arabinoside (LD AraC).

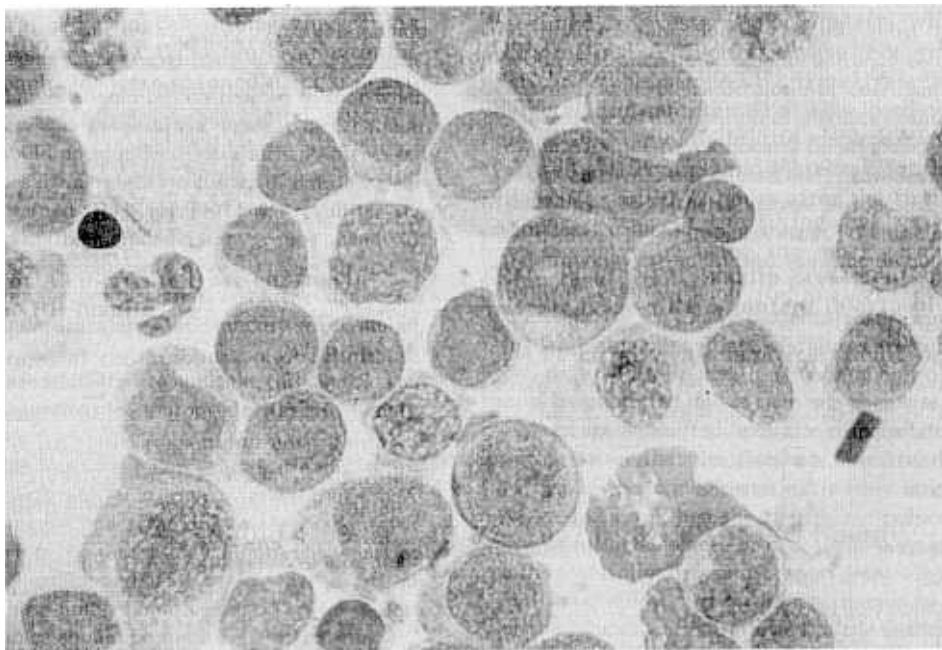
### CASE REPORT

A 46-year-old male was admitted to our hospital for evaluation of general weakness and dizziness for 2 months. On admission, a complete blood count showed Hb 4.8g/dl, WBC 12,900/mm<sup>3</sup> with 31% blasts and platelet 98,000/mm<sup>3</sup>. His bone marrow was markedly hypercellular with cells morphologically classified as FAB M2 (Fig. 1). Cytochemical examination revealed that blasts were strongly positive for myeloperoxidase. Immunophenotyping of blasts with monoclonal antibodies revealed 45% of the blasts to express CD33

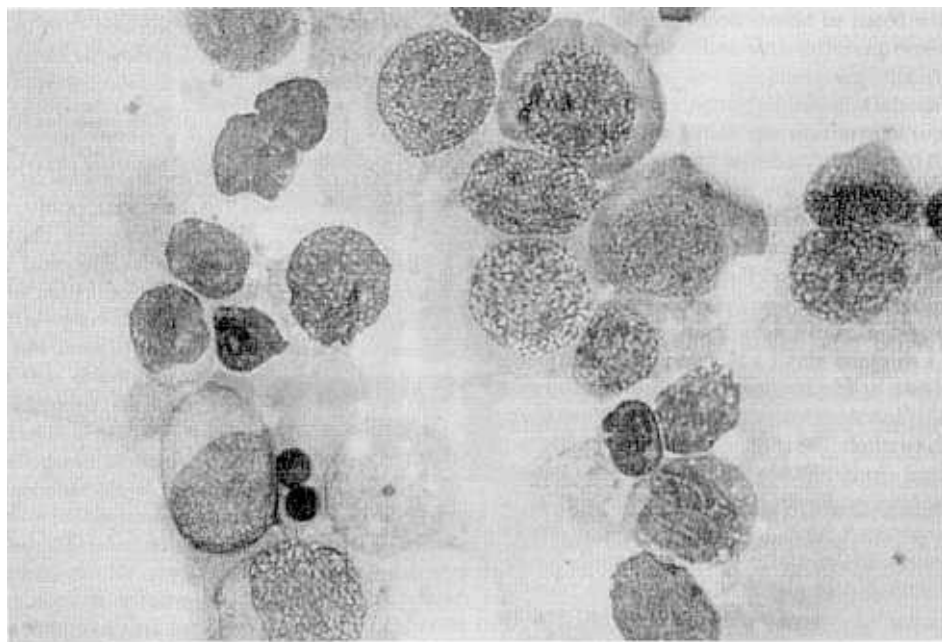
Received July 14, 1993

Department of Internal Medicine, Division of Hemato-Oncology, Yonsei University College of Medicine, Seoul, Korea

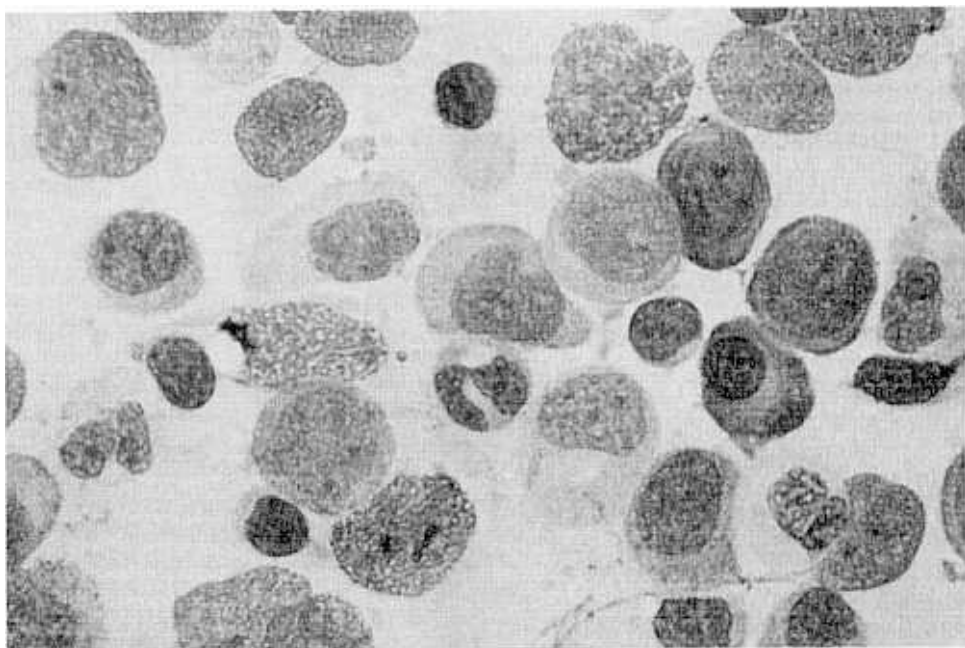
Address reprint requests to Dr. YH Min, Department of Internal Medicine, Yonsei University College of Medicine, C.P.O. Box 8044, Seoul, Korea, 120-752



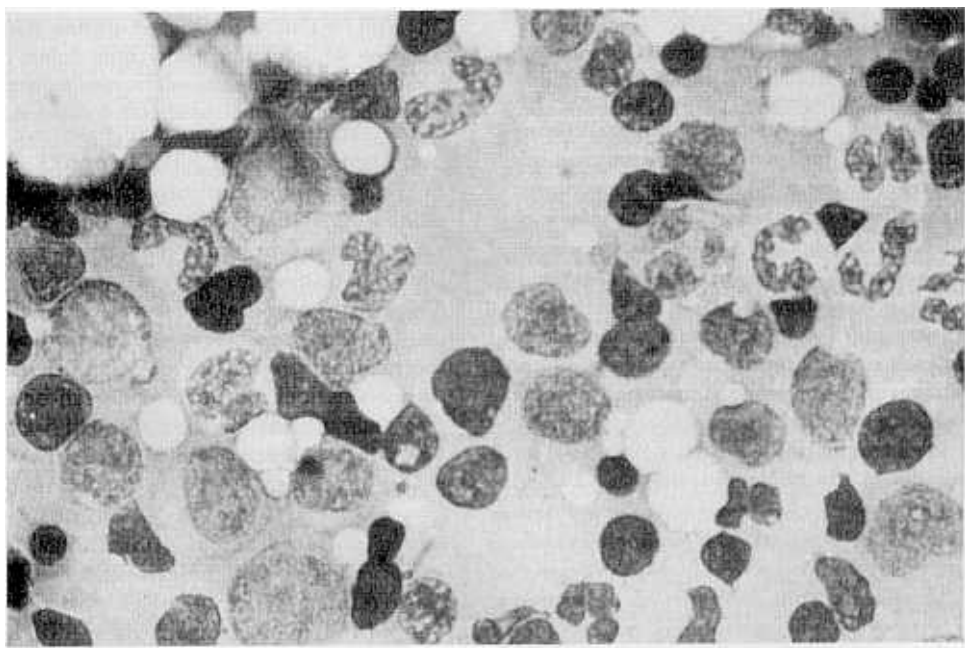
**Fig. 1.** Markedly hypercellular marrow loaded with myeloblasts (Wright stain,  $\times 1,000$ ).



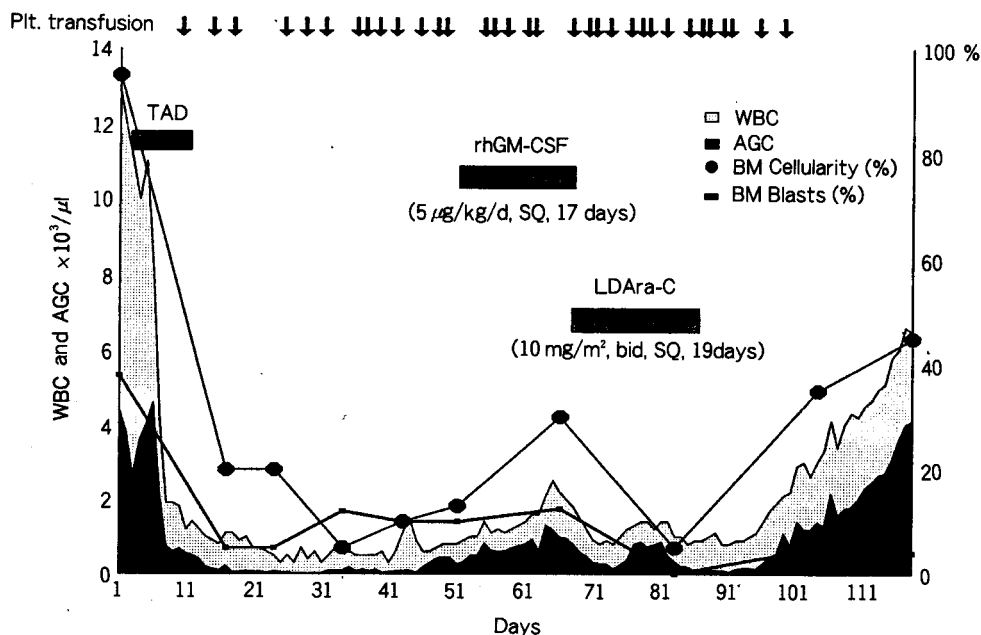
**Fig. 2.** Hypocellular marrow with residual leukemic blasts (Wright stain,  $\times 1,000$ ).



**Fig. 3.** Increased marrow cellularity with persistent leukemic blasts after GM-CSF (Wright stain,  $\times 1,000$ ).



**Fig. 4.** Bone marrow showing complete remission after LD AraC (Wright stain,  $\times 1,000$ ).



**Fig. 5.** Hematological parameters during treatment.

TAD: 6-TG 100 mg/m<sup>2</sup>/d, 7 days, Daunorubicin 45 mg/m<sup>2</sup>/d, 3 days  
Ara-C 100 mg/m<sup>2</sup>/d, 7 days

and 70% to be CD13 positive. Metaphase suitable for chromosome analysis was not obtained. He underwent remission induction chemotherapy consisting of cytosine arabinoside (AraC) (100 mg/m<sup>2</sup> by continuous infusion x7d), daunorubicin (45 mg/m<sup>2</sup> days 1~3) and 6-thioguanine (100 mg/m<sup>2</sup> x7d). The bone marrow done on the 31st day after chemotherapy showed hypocellular marrow (<15~20%) with 16% myeloblasts present, and granulocytic series and megakaryocytes were hardly seen. Repeated bone marrow aspirations and trephines done on day 41 showed a more decreased cellularity (<5~10%) without a significant change of blasts from the previous examinations (Fig. 2). This resulted in extreme pancytopenia for 42 days and during this time recurrent infections such as neutropenic enterocolitis on day 13, mucositis on day 21, bronchopneumonia (*Klebsiella pneumoniae*) on day 34 developed in spite of broad spectrum antibiotics. On day 49 rhGM-CSF (Schering-Plough/Sandoz; 5  $\mu$ g/kg/d SQ) therapy was commenced. During the following 17 days, the WBC rose from 800/mm<sup>3</sup>

(day41) to 2,500/mm<sup>3</sup> (day66), the absolute granulocyte count from 432/mm<sup>3</sup> to 1,550/mm<sup>3</sup>. The bone marrow examinations which were performed on day 67 showed an increased cellularity (30%) with a predominant and markedly left shifted granulopoiesis, but without changes of blasts (15%) at the same time (Fig. 3). Megakaryopoiesis and erythropoiesis were unremarkable. GM-CSF treatment was stopped and LD AraC treatment (10 mg/m<sup>2</sup>  $\times$  2/d/SQ) was followed for 19 days. A complete blood count, done 35 days after LD AraC treatment, revealed Hb 11.0g/dl, platelet 153,000/mm<sup>3</sup> and WBC 4,500/mm<sup>3</sup> with 57% neutrophils without blast and bone marrow examination, done on the same day revealed findings compatible with complete remission (Fig. 4). Hematological changes after GM-CSF and LD AraC treatment are shown in Fig. 5. His complete remission was maintained by another 2 courses of simultaneous administration of GM-CSF and LD AraC for more than 6 months.

## DISCUSSION

The mechanisms of remission failure with prolonged marrow hypoplasia with residual leukemic cells after induction chemotherapy in patients with acute leukemia can be suggested as the following; 1) the existence of a leukemic stem cell population which is resistant to the chemotherapeutic agents, or inadequate leukemic cell kill 2) the absence of adequate normal stem cell reserves to recover complete normal marrow function (Preisler 1978; Estey *et al.* 1982). So it could be beneficial to stimulate the normal stem cell pool while reducing residual leukemic clones in such a situation.

GM-CSF is a cytokine that promotes proliferation and maturation of myeloid progenitor cells both in vitro and in vivo, giving rise primarily to neutrophils, eosinophils and monocytes (Gasson 1991). GM-CSF also maintains and enhances the function of these mature myeloid effector cells (Weisbart *et al.* 1987). Under various conditions such as marrow suppressions due to chemotherapy, GM-CSF has been proven to effectively stimulate granulopoiesis, and to decrease neutropenia-associated complications such as life-threatening infections (Bettelheim *et al.* 1991; Lieschke and Burgess 1992). It was reported that a rapid recovery of the neutrophil count was observed with GM-CSF following chemotherapy in six patients with AML (Buchner *et al.* 1988). But its use in AML deserves special cautions because GM-CSF stimulates growth of malignant myeloid cells through specific receptors (Hoang *et al.* 1986; Delwel *et al.* 1988; Young *et al.* 1988) as shown in cases with myelodysplastic syndrome (MDS) (Hoelzer *et al.* 1989). Recent in vitro study has shown that GM-CSF triggers quiescent AML blasts to enter G<sub>1</sub>- and S-phases of the cell cycle and thereby renders them more susceptible to subsequent kill by cell-cycle specific drugs such as AraC (Bhalla *et al.* 1988; Miyauchi *et al.* 1989). And it was demonstrated that leukemic clonogenic cells can be eradicated preferentially by prolonged exposure to LD AraC in the presence of GM-CSF with relative preservation of the normal

hematopoietic progenitor cells (Lely *et al.* 1991). The dosages of AraC used in this study were in the same range as the plasma concentration reached with in vivo LD AraC administration (Spriggs *et al.* 1985).

To the best of our knowledge this is the first reported case of a successful treatment of a patient with AML, who showed prolonged markedly hypocellular bone marrow with significant residual leukemic cells after induction chemotherapy, with a sequential treatment of GM-CSF and LD AraC. This type of treatment schedule has already been applied in patients with MDS who received LD AraC in combination with GM-CSF (Hoelzer *et al.* 1989). We propose the use of GM-CSF followed by LD AraC in cases with prolonged marrow hypoplasia with residual leukemic blasts to expedite myeloid recovery and augment residual leukemic cell kill by recruiting leukemic blasts leading to complete remission.

## REFERENCES

- Bettelheim P, Valent P, Andrrff M, Tafuri A, Haimi J, Gorischek C, Muhm M, Silaber CH, Haas O, Vieder L, Maurer D, Schulz G, Speiser W, Geissler K, Kier P, Hinterberger W, Lechner K: Recombinant human granulocyte-macrophage colony-stimulating factor in combination with standard induction chemotherapy in de novo acute myeloid leukemia. *4Blood* 77: 700-711, 1991
- Bhalla K, Birkhofer M, Arlin Z, Grant S, Lutzky J, Graham G: Effects of recombinant GM-CSF on the metabolism of cytosine arabinoside in normal and leukemic human bone marrow cells. *Leukemia* 2: 810-813, 1988
- Buchner TH, Hiddemann W, Zuhlsdorf M: Human recombinant granulocyte-macrophage colony-stimulating factor (GM-CSF) treatment of patients with acute leukemia in aplasia and at high risk of early death. *Behring Inst Mitt* 83: 308-312, 1988
- Cheson BD, Cassileth PA, Head DR, Schiffer CA, Bennett JM, Bloomfield CD, Brunning R, Gale RP, Grever MR, Keating MJ, Sawitsky A, Strass S, Weinstein H, Woods WG: Report of the National Cancer Institute-Sponsored Workshop on definition of diagnosis and response in acute myeloid leukemia. *J Clin Oncol* 8: 813-819, 1990

- Delwel R, Salem M, Pellens C, Dorssers C, Wagemaker G, Clark S, Lowenberg B: Growth regulation of human acute myeloid leukemia: Effects of five recombinant hematopoietic factors in a serum-free culture system. *Blood* 72: 1944-1949, 1988
- Estey EH, Keating MJ, McCredie KB: Causes of initial remission induction failure in acute myelogenous leukemia. *Blood* 60: 309-315, 1982
- Gasson JC: The molecular physiology of GM-CSF. *Blood* 77: 1131-1145, 1991
- Hoang T, Nara N, Wong G, Clark S, Minden MD, McCulloch EA: Effects of recombinant GM-CSF on the blast cells of acute myeloblastic leukemia. *Blood* 68: 313-316, 1986
- Hoelzer D, Ganser A, Hoffken K, Boggaerts M, Lutz D, De Witte T, Diehl V, Sokal S, Ottmann OG, Schulz G: Combination therapy with recombinant human granulocyte-macrophage colony-stimulating factor (rhGM-CSF) and low-dose cytosine arabinoside in patients with myelodysplastic syndrome. *Exp Hematol* 17: 652-657, 1989
- Lely NVD, Witte TD, Muus P, Raymakers R, Preijers F, Haanen C: Prolonged exposure to cytosine arabinoside in the presence of hematopoietic growth factors preferentially kills leukemic versus normal clonogenic cells. *Exp Hematol* 19: 267-272, 1991
- Lieschke GJ, Burgess AW: Granulocyte colony-stimulating factor and granulocyte-macrophage colony-stimulating factor (Second of Two Parts). *N Engl J Med* 327: 99-106, 1992
- Miyauchi J, Kelleher CA, Wang C, Minkin S, McCulloch EA: Growth factors influence the sensitivity of leukemic stem cells to cytosine arabinoside in culture. *Blood* 73: 1272-1278, 1989
- Preisler HD: Failure of remission induction in acute myelocytic leukemia. *Med Ped Oncol* 4: 275-278, 1978
- Spriggs D, Griffin J, Wisch J, Kufe D: Clinical pharmacology of low-dose cytosine arabinoside. *Blood* 65: 1087-1089, 1985
- Young DC, Demetri GD, Ernst TJ, Cannistra SA, Griffin JD: In vitro expression of colony-stimulating factor genes by human acute myeloblastic leukemia. *Exp Hematol* 16: 378-382, 1988
- Weisbart RH, Kwan L, Golde DW, Gasson JC: Human GM-CSF primes neutrophils for enhanced oxidative metabolism in response to the major physiologic chemoattractants. *Blood* 69: 18-21, 1987