

Hereditary Spastic Paraplegia

Il Saing Choi, Hyo Kun Cho and Ki Whan Kim

*Department of Neurology, Yonsei University College of Medicine,
Seoul, Korea*

Hereditary spastic paraplegia (HSP) is a rare hereditary disorder and becomes clinically apparent during adolescence or in childhood and progresses slowly throughout the adult years with a variability in the severity of expression.

We experienced 3 cases of hereditary spastic paraplegia. Cases 1 and 2, which were pure HSP, had only the signs and symptoms of corticospinal tract involvement with the positive family history, and case 3, which was a complicated case of HSP, had distal muscle wasting, dysarthria, signs and symptoms of the corticospinal tracts, and a positive family history.

All are thought to be inherited in an autosomal dominant pattern.

Key Words : Hereditary spastic paralysis, pure HSP, complicated HSP

Hereditary spastic paraplegia (HSP) is characterized by progressive weakness and spasticity of the legs, with progressive demyelination of the lateral corticospinal tracts. Since the first description of hereditary spastic paraplegia was that of Strümpell in 1880 (although Seeligmüller and described a similar disorder 4 years previously), varieties with additional features have been described, including mental retardation and ichthyosis (Sjögren and Larsson, 1957), pigmentary retinal degeneration (Kjellin, 1959), optic atrophy (Nyberg-Hansen and Refsum, 1972), extrapyramidal features (Dick and Stevenson, 1953), amyotrophy (Silver, 1966; Cross and McKusick, 1967), sensory neuropathy (Cavanagh *et al*, 1979), and cutaneous hypo-

pigmentation (Stewart *et al*, 1981). In Korea, there were case reports of hereditary spastic paraplegia (Kim *et al*, 1982; Chu *et al*, 1983). We present three cases of HSP, 2 cases of pure HSP, and a case of complicated HSP with distal muscle wasting and dysarthria.

Report of Cases

Case 1 (YUMC, No. 816264): A 54 year old man was thought to be normal until approximately 34 year of age when weakness of the lower extremities developed. This symptom was slowly progressive and weakness of the upper extremities developed 3 years ago.

His father died with the same symptoms at 66 years of age. His brother and sister died due to cirrhosis of the liver at 44 and 39 years

of age, but they had no neurologic problems. His eldest daughter had increased DTR, without any gait disturbance. His mother, son and other daughter were thought to be normal. Further pedigree of his family was unknown (Fig. 1-1).

He was well developed and well nourished. His intelligence seemed to be normal. Cranial nerve functions were intact. No ataxia tremor was noted. No wasting of musculature or fasciculation was noted. Deep tendon reflexes were increased in all extremities and spasticity was noted in all extremities, particularly the lower extremities. Bilateral extensor plantar responses and ankle clonus were elicited.

CBC, urinalysis, SMA-12, chest X-ray and ECG were normal. Spine X-ray, nerve conduction velocity (NCV) and electromyographic (EMG) studies were also normal.

Case 2 (YUMC, No. 882682): A 22 year old woman was admitted to YUMC with the C.C of walking difficult.

She was in relatively good health until 4 years prior to admission (PTA) when she felt a tightness of the lower extremities on walking. After that, tremor of the hands developed, and weakness of the lower extremities was noted.

Her mother (no brother or sister) had a history of gait disturbance, and died due to cirrhosis of the liver at 40 years of age. Her elder sister suffered from the same symptoms for 6 years. Her father, 4 brothers and 2 other sisters had no neurologic problems. Further pedigree of her family was unknown (Fig. 1-2).

She was well developed and well nourished. Her intelligence seemed to be normal. Cranial nerve functions were intact. Mild intention tremor was elicited, but other cerebellar function were intact. No wasting of musculature or fasciculation was noted. Deep tendon reflexes were increased in all extremities and spasticity was noted in the extremities, particularly the

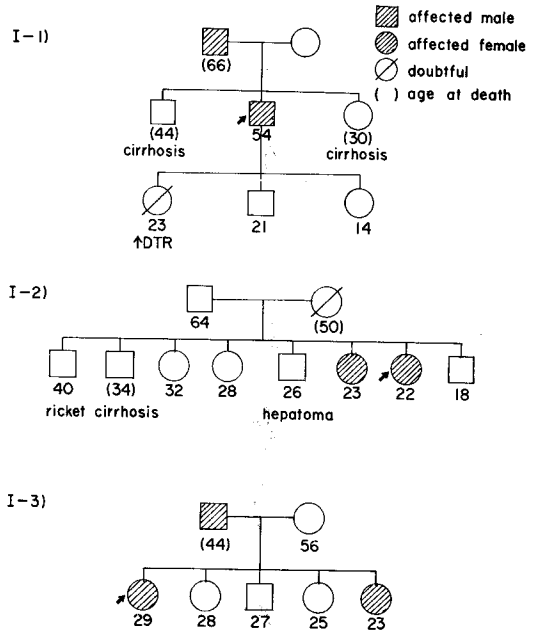


Fig. 1. Pedigrees of the three families.

lower extremities. Bilateral extensor plantar responses and ankle clonus were elicited.

CBC, urinalysis, SMA-12, chest X-ray, ECG and CSF studies were normal. Spine X-ray, NCV and EMG studies were also normal.

Case 3 (YUMC, No. 1289912): A 29 year old woman was admitted to YUMC with the C.C. of weakness of the extremities and slurred speech.

She was in relatively good health until 9 years PTA when she noted weakness of the extremities. After that, slurred speech developed, and 4 years PTA, the above symptoms gradually progressed and distal muscle wasting developed.

Her father died with the same symptoms at 44 years of age. Her younger sister suffered from the same symptoms for 5 years. Her mother, brother and 2 other sisters were normal. Her father had 3 brothers and 2 sisters living in North Korea. Further pedigree of her family was unknown (Fig. 1-3).

She was well developed. Her intelligence seemed to be normal. Speech was slurred and her gag reflex was weak. Marked wasting of the distal muscles were noted in the upper extremities with thenar, hypothenar, and dorsal interos-seus atrophy. Interos-seus muscles of the feet were also atrophied. No fasciculation was noted. Deep tendon reflexes were increased in the lower extremities. Bilateral ankle clonus were elicited, but extensor plantar responses were flexed.

CBC, urinalysis, SMA-12, chest X-ray and ECG were normal. NCV & EMG studies were normal, and muscle biopsy of the right vastus lateralis revealed no neurogenic or myopathic evidence except slight type 2 fiber predominance.

DISCUSSION

Spastic paralysis is caused by multiple sclerosis, spinal cord tumor, arteriovenous malformation of the spinal cord, cervical spondylosis, motor neuron disease, unappreciated structural lesions and hereditary disease (Ungar-Sargon *et al*, 1980).

Hereditary spastic paraplegia was first reported by Seeligmüller in 1876, and Strümpell recorded the case histories of 2 brothers presenting in middle age with progressive weakness and spasticity involving predominantly the lower extremities 4 year later. Contributions by Strümpell had led writers to designate this disease with his name. After that, many additional cases have been reported (Behan & Maia, 1974; Holmes, 1977; Harding, 1981).

Although the diagnosis is commonly made in patients with evidence of pyramidal tract disease beginning in the lower extremities and family history, the disease is frequently more extensive and may progress to involve the arms as well as

cranial nerves. Some difference of opinion exists regarding the full range of clinical manifestations of spastic paraplegia (Cross and McKusick, 1967; Harding, 1981).

Pratt (1967) refers to the profusion of descriptions of "hereditary spastic paraplegia plus" syndromes in the subsequent literature. These include spastic paraplegia in association with mental retardation and ichthyosis (Sjögren and Larsson, 1957), pigmentary retinal degeneration (Kjellin, 1959), optic atrophy (Nyberg-Hansen and Refsum, 1972), extrapyramidal features (Dick and Stevenson, 1953), amyotrophy (Silver, 1966; Cross and McKusick, 1967), sensory neuropathy (Cavanagh *et al*, 1979) ataxia and dysarthria (Van Beusekom *et al*, 1965) and cutaneous hypopigmentation (Stewart *et al*, 1981).

So HSP can be classified as pure HSP and complicated HSP.

On genetic grounds, three types must exist: An autosomal dominant, an autosomal recessive and a sex-linked recessive (Behan & Maia, 1974; Harding, 1981). But most reported cases were inherited as autosomal dominant.

Of our 3 cases, 2 cases were pure HSP, and one was a complicated case, HSP with amyotrophy.

Although case 3 had clinically a resemblance to familial motor neuron disease (Horton *et al*, 1976), it could be easily distinguished by the clinical course, normal EMG and muscle biopsy findings.

We could not obtain a complete pedigree of the families, but our cases were thought to be inherited in an autosomal dominant pattern.

REFERENCES

Behan WMH, Maia M: *Strümpell's pure familial*

- spastic paraplegia: Case study and review of the literature. J Neurol Neurosurg Psychiat* 37:8, 1974
- Cavanagh NPC, Eames RA, Galvin RJ, Brett EM, Kelly RE: *Hereditary sensory neuropathy with spastic paraplegia. Brain* 102:79, 1979
- Cross HE, McKusick VA: *The Troyer syndrome. A recessive form of spastic paraplegia with distal muscle wasting. Arch Neurol* 16:473, 1967
- Chu JH, et al: *Strümpell's hereditary spastic paraplegia. J Korean Med Assoc* 26:351, 1983.
- Dick AP, Stevenson CJ: *Hereditary spastic paraplegia: Report of a family with associated extrapyramidal signs. Lancet* 1:921, 1953
- Harding A: *Hereditary pure spastic paraplegia: A clinical and genetic study of 22 families. J Neurol Neurosurg Psychiat* 44:871, 1981
- Holmes GL, Shaywitz BA: *Strümpell's pure familial spastic paraplegia: Case study and review of the literature. J Neurol Neurosurg Psychiat* 40:1003, 1977
- Horton WA, Eldridge R, Brody JA: *Familial motor neuron disease. Evidence for at least 3 different types. Neurology* 26:460, 1975
- Kim NA, Cho MK, Coe CJ, Yun DJ: *Hereditary spastic paraplegia. J Korean Ped Assoc* 25:498, 1982
- Kjellin K: *Familial spastic paraplegia with amyotrophy, oligophrenia and central retinal degeneration. Arch Neurol* 1:133, 1959
- Vyberg-Hansen R, Refsum S: *Spastic paraparesis associated with optic atrophy in monozygotic twins. Acta Neurol Scand Suppl* 51:261, 1972
- Pratt RTC: *The genetics of neurological disorder. Oxford university press, 1967, p. 44, cited from Harding A*
- Seeligmüller A: *Sklerose der reitenstränge des Rücken marks bei 4 kindern derselben Familie. Dtsch Med Wochenschr* 2:185, 1876, cited from Harding A
- Silver JR: *Familial spastic paraplegia with amyotrophy of the hands. J Neurol Neurosurg psychiat* 29:135, 1966
- Stewart RM, Tunell G, Ehle A: *Familial spastic paraplegia, peroneal neuropathy, and crural hypopigmentation: A new neurocutaneous syndrome. Neurology* 31:754, 1981
- Strümpell A: *Beiträge zur pathologie des Rücken marks. Arch psychiat Nervenkr* 10:676, 1980. Cited from Harding A
- Unger-Sargon JY, Lovelace RE, Brust JCM: *Spastic paraplegia-paraparesis. J Neurol Neurosurg Psychiat* 46:1, 1980
- Van Beusekom GT, Stall A, Went LN: *A family with hereditary spastic ataxia. Acta Neurol Scand* 41:97, 1965