

Electromyographic Studies of Obstetrical Palsy

In Hee Chung, Jung Soon Shin, and Hyungnam Moon

Department of Orthopedic Surgery, Yonsei University College of Medicine

ABSTRACT

Electromyography and related electrodiagnostic techniques are being applied to clinical studies of neuromuscular diseases with increasing frequency and effectiveness.

Four patients with obstetrical palsy were examined and followed up with electromyography. The findings from clinical observation and electromyographic studies were discussed in regard to the site of the lesion, prediction of prognosis and the degree of nerve regeneration.

It is emphasized that findings provided by electromyographic examinations can not only contribute to accurate diagnosis, but also serve as a guide for selecting appropriate means of treatment with physical therapy for the patients with obstetrical palsy as well as to monitor progress, by doing a series of periodic examinations.

Adler and Patterson(1967) reported that the incidence of Erb's palsy has remarkably decreased. From 1939 to 1962 they found only one hundred and twenty three cases instead of four hundred and ninety one cases in the period from 1928 to 1939 at the Hospital for Special Surgery.

Statistics on obstetrical palsy due to the brachial plexus injury are not available in Korea. It is assumed however that its incidence

here must also be decreased as the obstetric services have advanced significantly in recent years.

The clinical picture of a brachial plexus palsy is dependent on the location of the pathology in the plexus and it is not easy to predict the prognosis without knowledge of the degree of injury.

With electromyographic studies it is possible to detect the exact site of the lesion in the brachial plexus, the degree of injury and the progress of nerve regeneration. Therefore, it is a useful tool for making accurate diagnosis and prognosis and the findings provided by the electromyographic studies permit appropriate selection of treatment as the nerve regeneration takes place.

Four cases of obstetrical palsy of the brachial plexus were referred to Severance Hospital for electromyographic examination and subsequent treatment from February to September 1972.

REPORT of CASES

Case 1.

A twelve day old girl with paralysis of the right upper extremity was brought for examination. The mother had been healthy during her pregnancy but the baby was delivered with difficulty due to large head size(birth weight; 4.0 kg.) at the hospital. Immediately after birth

the right upper extremity was found to be completely paralyzed.

On physical examination the baby did not respond to pin-pricks on the right arm which was flaccid.

There were no deep tendon reflexes. There was no motor response to percutaneous electrical stimulation of the median and ulnar nerves on the right side. Sensory nerve action potentials and motor conduction of these nerves could not be elicited. When a needle electrode was inserted into the muscles of the right arm, eg. deltoid, triceps, biceps, brachioradialis, extensor carpi radialis, abductor pollicis brevis, and abductor digiti quinti, there was electrical silence.

The patient received physical therapy daily, including hot packs to the arm, electrical stimulation therapy to the muscles, and passive exercises to maintain the range of motion of all joints.

After eight weeks, voluntary contraction of the deltoid muscle was observed. Sensation over the deltoid area returned. Sixteen weeks after the first examination, electromyography revealed a few normal motor unit potentials (Fig. 1) in the deltoid, triceps, biceps, brachioradialis, and extensor carpi radialis muscles and "nascent potential" (Fig. 2) was seen in the flexor carpi ulnaris. Many fibrillation potentials were seen in the abductor pollicis brevis and abductor digiti quinti.

At this time, by manual muscle test, the muscle strength of the deltoid was fair, biceps poor⁽⁻⁾, and triceps showed a trace but the other muscles, eg. brachioradialis, extensor carpi radialis, and flexor carpi ulnaris, although showing normal motor unit potentials on electromyography, were graded as zero. Electrical stimulation therapy was continued only for the forearm and hand muscles. Active assistive

exercise was started for the shoulder muscles.

Six months after birth, voluntary contraction of the flexors and extensors of the wrist were observed. Sensory nerve action potential of the right median nerve was normal (Fig. 3). The motor conduction velocity was not measurable either in the median or the ulnar nerve. Electromyography showed an increase in the number of normal motor unit potentials in the muscles which had previously recorded only a few

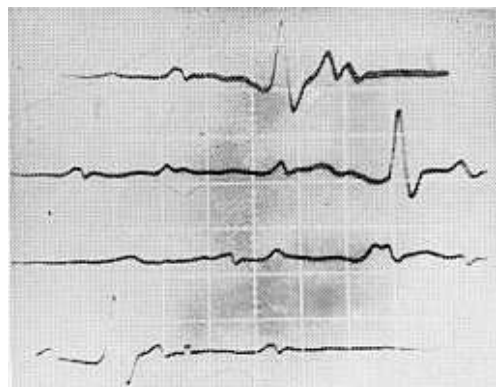


Fig. 1. Normal motor unit potentials. (Case 1) 500 μ V, 10 msec. per division.

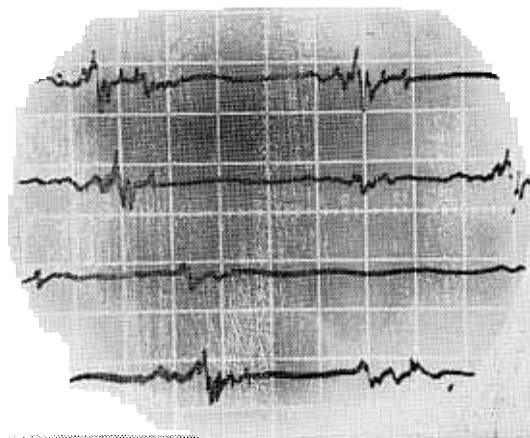


Fig. 2. Nascent potentials. (Case 1) 200 μ V, 10 msec. per division.

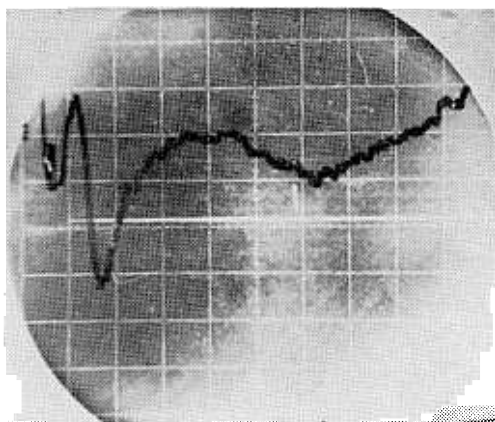


Fig. 3. Sensory nerve action potential of median nerve. (Case 1) $10\ \mu\text{V}$, 2.0 msec. per division
Amplitude: $40.0\ \mu\text{V}$, Latency: 1.2 msec.

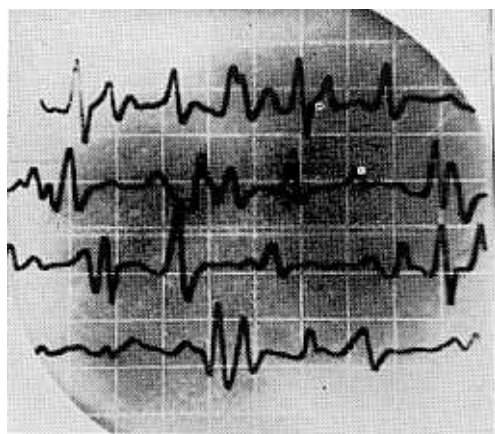


Fig. 4. Normal motor unit potentials. (Case 1) 1.0 mV, 10 msec. per division. Notice increased number and amplitude of potentials, compared with Fig. 1.

(Fig. 4). Their amplitude was also increased.

Abductor pollicis brevis showed fibrillations at rest and a few normal motor unit potentials on voluntary contraction. In the hypotenar muscles, fibrillations were present but no motor unit potentials were observed.

A minimal degree of muscle atrophy was seen in the intrinsic muscles of the hand. The length

of both arms was equal. Shoulder muscles were tested as fair/fair⁽⁻⁾ and wrist muscles poor⁽⁻⁾.

Case 2.

A two month old girl came with left upper extremity paralysis. The pregnancy was normal but the mother had a difficult delivery. At birth the baby's left arm was found to be paralyzed.

Physical examination revealed findings similar to Case 1. On electromyography many fibrillation potentials (Fig. 5) but no motor unit potentials were seen in the muscles of the left arm. Sensory nerve action potentials and motor conduction velocity were not detectable in the left arm. There were many normal motor unit potentials in the rhomboid muscle on electromyography.

After four weeks of physical therapy, normal motor unit potentials appeared in the deltoid, biceps, and triceps muscles. In other muscles, fibrillations and positive sharp waves were present. At five and a half months of age, normal motor unit potentials appeared down

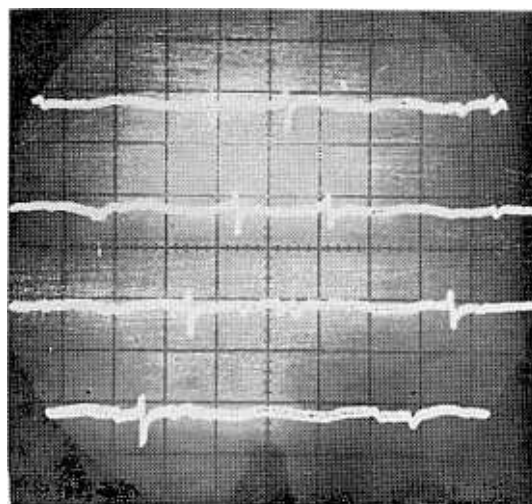


Fig. 5. Fibrillation potentials. (Case 2) $500\ \mu\text{V}$, 10 msec. per division.

to the abductor pollicis brevis. Other intrinsic hand muscles showed denervation potentials. At this time sensory nerve action potentials and motor conductions were not yet elicited. Physical therapy in the form of hot packs, electrical stimulation and therapeutic exercises was continued daily.

A moderate degree of muscle atrophy in the wrist flexors causing muscle imbalance resulted in wrist hyperextension (Fig. 6). To prevent joint deformity, a simple volar splint was used for the wrist (Fig. 7). There was no difference in arm length.

Case 3.

A two year old boy with a history of right upper extremity paralysis due to birth injury complained of poor function of the right hand. He has received physical therapy for a year on irregular visits, the mother said, and the problem is a poor grasp, though there was significant motor and sensory return in the right arm.

The muscle strength of the right upper extremity was generally fair⁽⁺⁾/fair. The deep tendon reflexes were decreased and sensation was intact in all areas. The right arm was about 1.5cm. shorter and the right hand appeared to be smaller than the left. There was no muscle atrophy.

To percutaneous electrical stimulation of the nerves, muscles responded with strong contractions. Distal latency of the right median nerve was 1.9 msec. and its conduction velocity was 35.0 m/sec. Normal motor unit potentials showed in the deltoid, biceps and abductor pollicis brevis muscles. There were no denervation potentials throughout.

Because it was deemed more important for this patient to improve his hand skills and function in activities of daily living rather

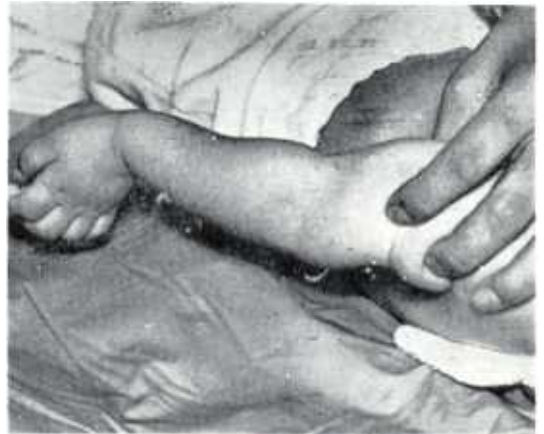

Fig. 6. Wrist hyperextension due to muscle imbalance in brachial plexus palsy. (Case 2).

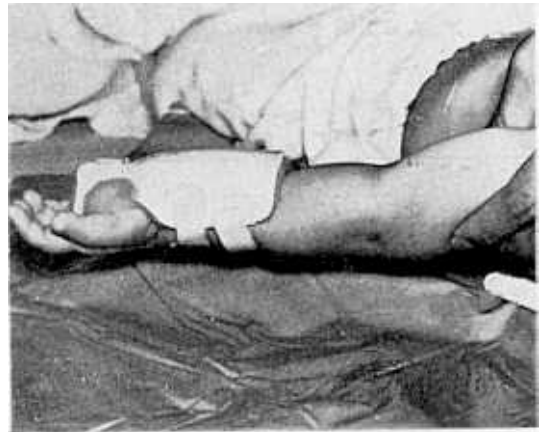


Fig. 7. Splinting to prevent joint deformity due to muscle imbalance. (Case 2).

than just muscle strength itself, the boy received occupational therapy along with physical therapy.

Case 4.

A seventeen day old baby was brought in with Erb's palsy. The mother was healthy during pregnancy. The baby was delivered at home with difficulty due to the large head size. Several days after birth, it was discovered that the left arm was not normal.

On physical examination the left upper extremity was in the typical position of Erb's palsy, ie. shoulder adduction and internal rotation, elbow extension, forearm pronation, and wrist flexion, the so-called "waiter's tip position" (Fig 8). Finger movements were normal. There was sensory loss in the dermatomes of C5 and C6. No biceps tendon reflex was elicited.

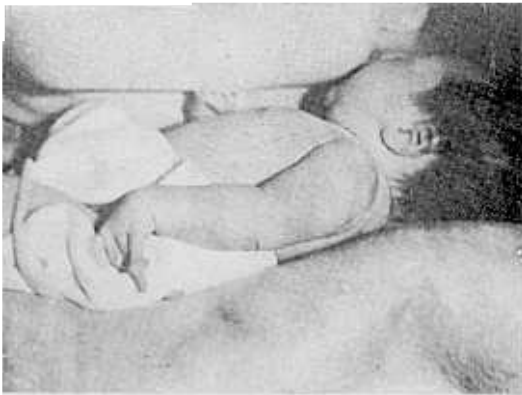

Fig. 8. Erb's palsy. (Case 4).
Showing "waiter's tip" position

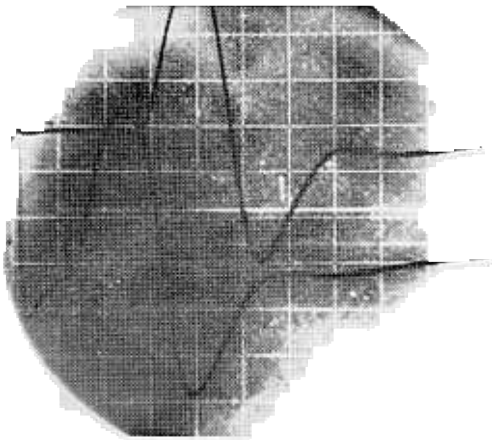


Fig. 9. Motor conduction study of median nerve.
(Case 4).

1.0 mV, 2.0 msec. per division

Distal latency: 2.4 msec.

Amplitude: 6.2 mV

Conduction velocity: 29.7 m/sec.

The motor conduction of the left median nerve was 29.7m/sec.(Fig. 9) with distal latency of 2.4 msec. There were no sensory nerve action potentials. On electromyography many normal motor unit potentials appeared in the rhomboid and abductor pollicis brevis muscles but there was electrical silence in the deltoid and biceps.

The mother was advised to put the baby in the prone position with the shoulder in abduction and external rotation, the elbow in flexion, and the wrist in a neutral position at home. The baby received daily hot packs to the shoulder followed by electrical stimulation therapy and passive exercises to maintain the range of motion and to prevent joint deformity.

After five weeks, fibrillation potentials were seen in the deltoid at rest and normal motor unit potentials were recorded in the deltoid and biceps. Clinically the muscle strength was fair⁽⁺⁾ in deltoid and fair⁽⁻⁾ in biceps. Electrical stimulation therapy was discontinued thereafter and active assistive exercises started to maintain range of motion and improve muscle strength.

DISCUSSION

Obstetrical palsy is caused during a difficult delivery due to abnormal presentation or cephalo-pelvic disproportion, etc. Brachial plexus palsy can be classified into three types according to the anatomical site of injury: upper trunk involvement(Erb's palsy), lower trunk involvement (Klumpke's), and the whole arm paralysis (Erb-Duchenne-Klumpke).

Diagnosis is rather easy to make from clinical manifestations but it is not easy to predict the prognosis. Electromyography can be used for prognosis and for selecting appropriate physical therapy during treatment. Whether the lesion

is pre or post-ganglionic is an important factor for prognosis. In preganglionic lesions, sensory nerve action potentials can be elicited (Robles, 1968; Warren et al, 1969; Zverina et al, 1969) and denervation potentials are present in the posterior cervical (Bufalini and Pescatori, 1969) and rhomboid muscles. Poor prognosis is expected for proximal root lesions.

In Case 2 and 4, it was clear that the lesion was distal to the roots because normal motor unit potentials were seen in the rhomboid muscle and sensory nerve action potentials were absent (Fig. 10). Sensory nerve action potentials were detected nine months after birth in Case 1. This means that the nerve regeneration was almost complete. When a peripheral nerve is injured, sensory nerve action potentials are the first to show changes with delayed latency, decreased amplitude, or complete absence.

Motor conduction velocity was not measurable in Case 1 and 2 on their first visit because the peripheral nerve is no longer excitable three days after injury. In Erb's palsy, motor conduct-

ion of the median nerve was 29.7m/sec. which is normal for the new born. Motor conduction in the new born is known to be half the adult value and reaches adult values anywhere from age two to five (Johnson and Olsen, 1960).

It takes about two to three weeks for an axon to undergo Wallerian degeneration. Fibrillation potentials become evident after Wallerian degeneration is complete (Buchthal, 1962). This is why there was no fibrillation potential in the paralyzed muscles in Case 1 and 2 at the first electromyographic examination.

As muscles become reinnervated, the number of fibrillations decrease gradually and highly polyphasic low potentials begin to appear. These are called "nascent potentials" (Fig. 2) and were seen in Case 1. As reinnervation progresses further, fibrillation disappears and normal motor unit potentials increase in number and amplitude (Fig. 3). These findings were observed in Case 1, 2, and 4.

One patient (Case 3) complained of dysfunction of the right hand, though the muscles

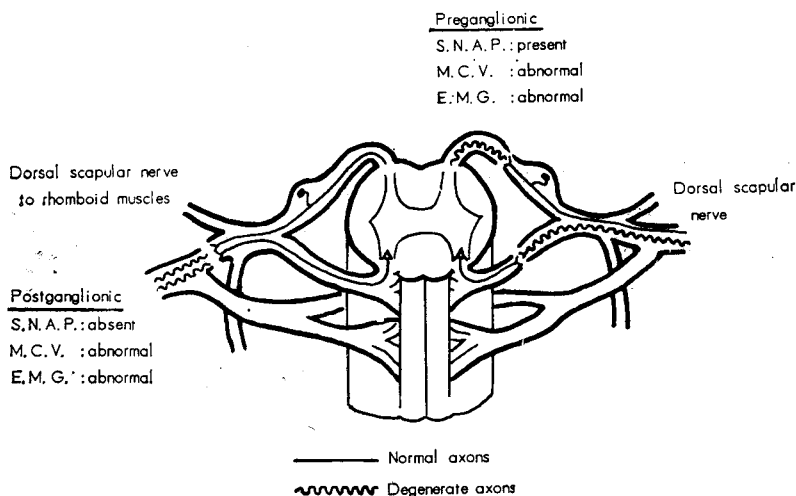


Fig. 10. Diagrammatic illustration of the brachial plexus lesions. (at C5 level).

S.N.A.P.: Sensory nerve action potential.

M.C.V.: Motor conduction velocity.

E.M.G.: Electromyography.

showed evidence of full innervation on electromyography. The recovery of electrical activity usually precedes the functional return of muscles.

In the treatment of brachial plexus palsy patients, therapeutic exercises are thought to be most important. All involved joints should be moved passively twice a day to maintain the range of motion and to prevent contracture which is usually caused by muscle imbalance, especially in Erb's palsy. It is reported that bracing in "the statue of liberty position," ie. shoulder abduction and external rotation, elbow flexion, and forearm supination, can be dangerous and often results in joint deformity or contracture (Adler and Patterson, 1967). The easiest and most effective method is to put the child in the prone position with the involved arm in proper position.

The use of electrical stimulation therapy is controversial; however, it is thought to be effective in delaying the occurrence of muscle atrophy in denervated muscles. When a muscle is reinnervated, this therapy should be discontinued.

Simple splints are useful for protecting joints and for preventing deformity due to muscle imbalance during nerve regeneration.

In general, the patients need to be encouraged to use the involved arm even after the motor function returns. Early occupational therapy in combination with physical therapy is effective to improve the function of the arm.

CONCLUSION

1. Four cases of obstetrical palsy of brachial

plexus are reported: three of them are Erb-Duchenne-Klumpke palsy and one is Erb's palsy.

2. Findings provided by series of electromyographic studies make for accurate diagnosis and prognosis and indicate the courses of nerve regeneration which permits appropriate selection of treatment procedure.

3. Satisfactory results are obtained from early treatment with physical and occupational therapy as the nerve regenerates.

REFERENCES

- Adler, J.B. and Patterson, R. L. Jr.: *Erb's Palsy. Long-term Results of Treatment in Eighty-eight Cases. J. Bone and Joint Surg.* 49A: 1052-1064, 1967.
- Buchthal, F.: *The Electromyogram. World Neurology* 3:16-31, 1962.
- Bufoalini, C. and Pescatori, G.: *Posterior Cervical Electromyography in the Diagnosis and Prognosis of Brachial Plexus Injuries. J. Bone and Joint Surg.* 51B:627-631, 1969.
- Johnson, E.W. and Olsen, K.J.: *Clinical Value of Motor Nerve Conduction Velocity Determination. J.A.M.A.* 172:2030-2035, 1960.
- Ish, F. et al.: *EMG Findings on Re-innervation in Peripheral Nerve Lesions. Electroenceph. Clin. Neurophysiol.* 25:404-405, 1968.
- Robles, J.: *Brachial Plexus Avulsion, A Review of Diagnostic Procedures and Report of Six Cases. J. Neurosurg.* 28:434-438, 1968.
- Warren, J. et al.: *Electromyographic Changes of Brachial Plexus Root Avulsions. J. Neurosurg.* 31:137-140, 1969.
- Zverina, E. et al.: *Possibilities of the Electromyographic Diagnosis of Brachial Plexus Injury. Electroenceph. Clin. Neurophysiol.* 26:233, 1969.