



Unexpected Septic Shock after Ureteroscopic Lithotripsy in a Patient Preoperatively Treated for a Urinary Tract Infection

Jong Wook Kim, Hyoung Kook Jeong, Jong Jin Park, Ji Yun Chae, Hong Seok Park, Du Geon Moon, Mi Mi Oh

Department of Urology, Korea University Guro Hospital, Seoul, Korea

We describe a case of life-threatening septic shock after ureteroscopic lithotripsy. Prior to surgery, the patient had a confirmed sterile urine culture posttreatment for a urinary tract infection due to extended spectrum beta-lactamase-positive *Escherichia coli*.

Received: 15 March, 2016

Revised: 13 June, 2016

Accepted: 5 July, 2016

Keywords: Shock, septic; Urinary stone; Urinary tract infections

Copyright © 2016, Korean Association of Urogenital Tract Infection and Inflammation. All rights reserved.



This is an open access article distributed under the terms of the Creative Commons Attribution Non-Commercial License (<http://creativecommons.org/licenses/by-nc/4.0>) which permits unrestricted non-commercial use, distribution, and reproduction in any medium, provided the original work is properly cited.

Correspondence to: Mi Mi Oh

<http://orcid.org/0000-0002-1232-2598>

Department of Urology, Korea University Guro Hospital,
148 Gurodong-ro, Guro-gu, Seoul 08308, Korea
Tel: +82-2-2626-1310, Fax: +82-2-2626-1321
E-mail: mamah@hanmail.net

Despite careful preoperative preparation of patients, there is persistent risk of urosepsis in patients undergoing operation for obstructive uropathy associated with stones. We report a case of unexpected septic shock after ureteroscopic lithotripsy. Prior to surgery, the patient had a confirmed sterile urine culture after successful treatment of a urinary tract infection caused by extended spectrum beta lactamase (ESBL)-positive *Escherichia coli*.

CASE REPORT

A 60-year-old woman was referred to our hospital with a 3-day history of right flank pain. The patient had a history of type 2 diabetes and hypertension. The results of all physical examinations at the time of admission were normal except right costovertebral angle tenderness. Plain radiography revealed a 2 cm radiopaque stone in the right renal pelvis (Fig. 1A). Urinalysis results were as follows: pH level was 6.0; red blood cell count was 1-4 cells/high powered field (HPF); and white blood cell (WBC) count was 30-60 cells/HPF. The culture of midstream urine revealed ESBL-positive *E. coli*. Her serum blood urea nitrogen and creatinine levels were within the normal range

(18.3 mg/dl and 0.76 mg/dl, respectively), and her serum uric acid level was 5.7 mg/dl.

The *E. coli* infection was successfully treated with intramuscular antibiotics (amikacin sulfate) for 5 days, which was confirmed by a posttreatment sterile urine culture. We proceeded with the ureteroscopic lithotripsy. We followed the general protocol, including the introduction of a guidewire, a 9.5 French rigid ureteroscope, and extraction of the stone with a stone basket. Stone fragmentation was performed by pneumatic lithotripsy. The operation time was only 35 minutes, during which, her vital signs remained stable.

Six hours after the operation, the patient developed fever, nausea, and myalgia. On a physical examination, the patient showed to have fever (39.0°C), regular tachycardia (112 beats per minute), and hypotension (90/60 mmHg), without tachypnea (20 breaths per minute). On a laboratory examination, her WBC count increased to 24,600 cells/ μ l with 98.2% of neutrophil. Her C-reactive protein level was 359.07 mg/L and erythrocyte sedimentation rate was >120 mm/h. The patient was not anemic (hemoglobin, 11.2 g/dl) and was slightly thrombocytopenic (platelet count, 94,000 cells/ μ l). Despite a load of normal saline, her blood pressure

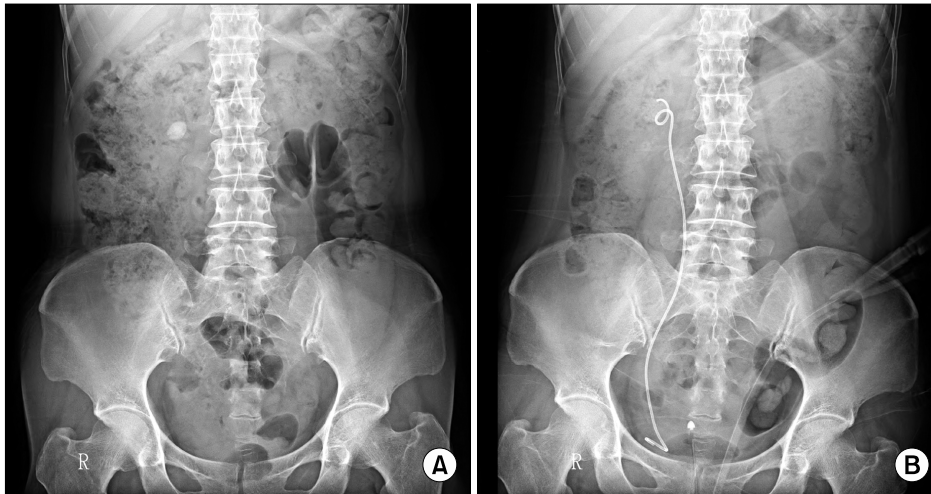


Fig. 1. (A) A plain radiograph image of a 2 cm radiopaque stone in the right renal pelvis. (B) After ureteroscopic lithotripsy, the stone was no longer present.

decreased to 70/40 mmHg. Septic shock was suspected, and therefore, the initial doses of ertapenem were administered as an empirical antibiotic treatment for ESBL-positive *E. coli*.

The vital signs became stable after 2 days. Renal pelvis stone was absent according to the follow-up radiograph obtained on the second postoperative day (Fig. 1B). Her fever and leukocytosis lasted for 4 and days respectively. The urine and blood cultures demonstrated an ESBL-positive *E. coli* infection. By hospital day 7, the patient was discharged and was maintained on oral amoxicillin/clavulanate. The final diagnosis was septic shock due to ESBL-positive *E. coli* infection.

DISCUSSION

An obstructed, infected kidney combined with ureteral stones can be a catastrophic event despite treatment with prophylactic antibiotics. Kamei et al. [1] revealed that thrombocytopenia and a positive blood culture were independent risk factors for septic shock in cases of acute obstructive pyelonephritis requiring emergency drainage.

When a midstream urine sample shows evidence of infection, the operation should be postponed until a sterile urine sample is achieved. Despite this, the patient is still potentially at risk of a life-threatening systemic infection [2]. Infected stones, obstructed pelvocalyceal system, prolonged operation, or comorbidity have all been implicated as the potential causes for this complication, which often results in high dependence or intensive care escalating the total cost of treatment.

Tambo et al. [3] reported a patient with obstructive acute pyelonephritis and showed an association between diabetes mellitus and a low level of platelet count. Our patient had thrombocytopenia (platelet count, 94,000 cells/ μ l) and diabetes mellitus. These two risk factors are thought to have affected the occurrence of septic shock.

In this case, we successfully treated the infection of ESBL-positive *E. coli* using intramuscular amikacin sulfate, which was confirmed via a sterile urine culture, and ureteroscopic lithotripsy was performed thereafter. The hydronephrosis was not severe, and the total operation time was relatively short. However, the patient still experienced a life-threatening episode of severe septic shock.

Although we concur that a midstream urine sample culture is a poor predictor of infected urine proximal to the obstructing ureteric stone or infected stones, as asserted by Mariappan et al. [2], it is the only preoperative option immediately after confirming the elimination of bacteria in midstream urine samples in clinical practice.

Thus, we reported a case of potential unexpected septic shock after ureteroscopic lithotripsy in a patient who had been preoperatively treated for a urinary tract infection.

CONFLICT OF INTEREST

No potential conflict of interest relevant to this article was reported.

REFERENCES

1. Kamei J, Nishimatsu H, Nakagawa T, Suzuki M, Fujimura T, Fukuhara H, et al. Risk factors for septic shock in acute obstructive pyelonephritis requiring emergency drainage of the upper urinary tract. *Int Urol Nephrol* 2014;46:493-7.
2. Mariappan P, Smith G, Bariol SV, Moussa SA, Tolley DA. Stone and pelvic urine culture and sensitivity are better than bladder urine as predictors of urosepsis following percutaneous nephrolithotomy: a prospective clinical study. *J Urol* 2005; 173:1610-4.
3. Tambo M, Okegawa T, Shishido T, Higashihara E, Nutahara K. Predictors of septic shock in obstructive acute pyelonephritis. *World J Urol* 2014;32:803-11.