



## Mondor's Disease of the Penis Mistaken for Penile Fracture

Young Hwan Jung, Dong Soo Ryu

Department of Urology, Samsung Changwon Hospital, Sungkyunkwan University School of Medicine, Changwon, Korea

Superficial thrombophlebitis of the dorsal vein of the penis, known as penile Mondor's disease, is an uncommon genital disease. We report on a healthy 44-year-old man who presented with painful penile swelling, ecchymosis, and penile deviation after masturbation, which initially imitated a penile fracture. Thrombosis of the superficial dorsal vein of the penis without rupture of corpus cavernosum was found during surgical exploration. The patient recovered without erectile dysfunction.

**Keywords:** Thrombophlebitis; Penis

**Received:** 22 September, 2015

**Revised:** 10 November, 2015

**Accepted:** 23 November, 2015

Copyright © 2016, Korean Association of Urogenital Tract Infection and Inflammation. All rights reserved.



This is an open access article distributed under the terms of the Creative Commons Attribution Non-Commercial License (<http://creativecommons.org/licenses/by-nc/4.0>) which permits unrestricted non-commercial use, distribution, and reproduction in any medium, provided the original work is properly cited.

**Correspondence to:** Dong Soo Ryu

<http://orcid.org/0000-0002-7557-0820>

Department of Urology, Samsung Changwon Hospital, Sungkyunkwan University School of Medicine, 158 Paryong-ro, Masanhoewon-gu, Changwon 51353, Korea

Tel: +82-55-290-6551, Fax: +82-55-290-1224

E-mail: dsryumd@skku.edu

Mondor's disease, a rare and self-limiting benign disease, which causes superficial venous thrombosis on the chest wall, was first described by Mondor in 1939, and penile Mondor's disease was first reported by Braun-Falco. They described the disease as clinically presenting with superficial vein thrombosis without contagious skin inflammation of the chest wall veins and rarely of the superficial dorsal vein of the penis [1].

The cause of penile Mondor's disease remains unclear but a detailed history frequently reveals prolonged or vigorous sexual intercourse causing stretching and torsion of penile veins. The disease has also been associated with several other risk factors: vacuum erection device, local trauma, urogenital infections, prostate surgery and prostate biopsy, hematologic diseases, or idiopathic cases [2].

In this report we describe a case of penile Mondor's disease in a 44-year-old man.

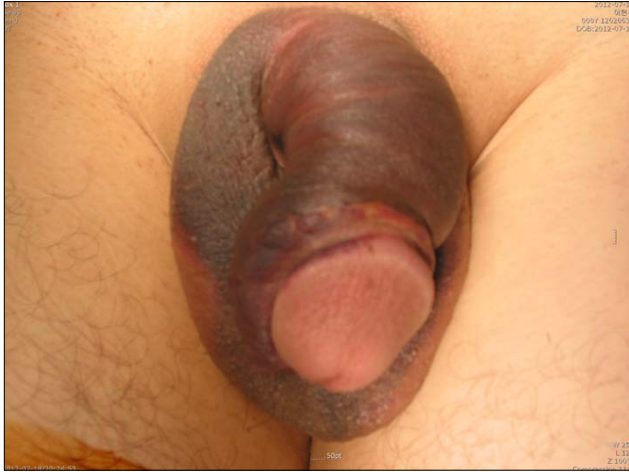### CASE REPORT

A 44-year-old man presented with painful penile swelling. He had developed sudden spontaneous penile swelling

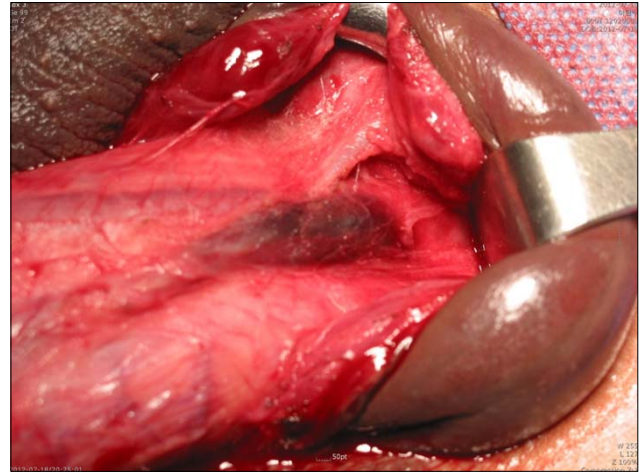
not accompanied by rapid detumescence during masturbation 1 day earlier. However, he denied history of acute bending of the penis during masturbation and he did not describe the "snap-pop" sound typically associated with penile fracture.

The patient was a cigarette smoker, but there was no chronic or acute illness and no risk for a venous thromboembolic disease. His familial history also revealed no hereditary malignancy or venous disease. Physical examination showed a marked swollen, ecchymotic, and deviated circumcised penis without blood at the meatus (Fig. 1). Genitourinary examination and the laboratory tests were all normal. Despite the non-typical history, we strongly suspected a penile fracture and decided on operative management without imaging studies.

At the time of the operation, a subcoronal circumcising incision was made and the penis was completely degloved after urethral catheterization. However, no defect was observed on either side of the corpus cavernosum and corpus spongiosum. Further dissection found thrombosis of the superficial dorsal vein of the penis at the proximal part of the penis, which was completely excised and the



**Fig. 1.** Photograph shows a markedly swollen, ecchymotic, and deviated circumcised penis without blood at the meatus.



**Fig. 2.** Surgical approach reveals superficial thrombophlebitis of the dorsal vein of the penis.

affected vein was ligated (Fig. 2). The subcoronal incision was repaired with simple interrupted sutures. The urethral catheter was removed on postoperative day 1 and the patient was discharged without complication. He had achieved satisfactory painless erections without penile curvature or any erectile dysfunction at the 2-year follow-up visit.

## DISCUSSION

Penile Mondor's phlebitis is a rare benign pathology of superficial thrombophlebitis involving the superficial vein of the penis mainly affecting sexually active men. Retro-glandular plexus, originating behind the corona of the glans, is a network of fine veins located on the dorsal aspect of the penis [3].

The retroglandular plexus is often exposed to inflammatory responses occurring under different conditions [1,4-6]. Although the exact pathophysiologic cause of Mondor's disease remains unclear, all proposed causes revolve around Virchow's triad of vessel: wall damage, vascular stasis, and hypercoagulable state [4].

The appropriate diagnosis of the disease can be established almost exclusively from the high index of suspicion with a thorough history and focused physical exam. Ultrasonography is a valuable diagnostic tool for detection of veins containing thrombus for the differential diagnosis between venous and lymphatic disease. Sclerosing lymphangitis and Peyronie's disease are two distinct entities that should be considered in the differential diagnosis [5,7-10].

In this case, the patient presented with painful penile

swelling with penile shaft deviation after masturbation suggesting a penile fracture. Immediate surgical repair was performed because delay of surgical treatment of penile fracture results in poor functional outcome.

During the operation, we found thrombosis of the superficial dorsal vein of the penis at the proximal part of the penis, which was completely excised and the affected vein was ligated. Treatment options for Mondor's disease vary from therapeutic abstention to anticoagulants, non-steroidal anti-inflammatory drugs (NSAIDs) or even surgery based on symptoms, locations, and mechanisms. This variety has led to the constitution of a heterogeneous entity precluding from a consensual mode of care.

Application of prophylactic antibiotics can be necessary in cases of cellulite. NSAIDs provide relief of pain and diminished inflammatory reaction, making them useful in cases of insistent pain and localized inflammation. Surgical thrombus excision also should be the treatment option in cases with no resolution, despite conservative treatment, and symptoms undistinguishable from penile fracture.

## CONFLICT OF INTEREST

No potential conflict of interest relevant to this article was reported.

## REFERENCES

1. Nazir SS, Khan M. Thrombosis of the dorsal vein of the penis (Mondor's disease): a case report and review of the literature.

- Indian J Urol 2010;26:431-3.
2. Ozturk H. Penile Mondor's disease. Basic Clin Androl 2014; 24:5.
3. Khan SA, Smith NL, Hu KN. New perspectives in diagnosis and management of thrombophlebitis of the superficial dorsal vein of the penis. J Dermatol Surg Oncol 1982;8:1063-7.
4. Kumar B, Narang T, Radotra BD, Gupta S. Mondor's disease of penis: a forgotten disease. Sex Transm Infect 2005;81:480-2.
5. Al-Mwalad M, Loertzer H, Wicht A, Fornara P. Subcutaneous penile vein thrombosis (penile Mondor's disease): pathogenesis, diagnosis, and therapy. Urology 2006;67:586-8.
6. Walsh JC, Poimboeuf S, Garvin DS. A common presentation to an uncommon disease. Penile Mondor's disease: a case report and literature review. Int Med Case Rep J 2014;7:155-7.
7. Day S, Bingham JS. Mondor's disease of the penis following a long-haul flight. Int J STD AIDS 2005;16:510-1.
8. Griger DT, Angelo TE, Grisier DB. Penile Mondor's disease in a 22-year-old man. J Am Osteopath Assoc 2001;101:235-7.
9. Yanik B, Conkbayir I, Oner O, Hekimoglu B. Imaging findings in Mondor's disease. J Clin Ultrasound 2003;31:103-7.
10. Kartsaklis P, Konstantinidis C, Thomas C, Tsimara M, Andreadakis S, Gekas A. Penile Mondor's disease: a case report. Cases J 2008;1:411.