

Obstructive Fibrinous Tracheal Pseudomenbrane Mimicking Tracheal Stents

Ju Sang Kim, M.D., Ji Hyun Yu, M.D., Yu Seung Kim, M.D., Il Kim, M.D., Joong Hyun Ahn, M.D.

Division of Pulmonology, Critical Care Medicine, Department of Internal Medicine, The Catholic University of Korea College of Medicine, Seoul, Korea

Obstructive Fibrinous Tracheal Pseudomenbrane (OFTP) is a rarely known but potentially fatal complication of endotracheal intubation. Sudden respiratory failure shortly after extubation is not infrequent in the ICU. However, these cases are commonly diagnosed as laryngospasm, retention of secretion or laryngeal edema. A 68-year-old woman presented with a 6-day history of progressive dyspnea. She had undergone invasive ventilator care for 24 hours. The patient was discharged from the hospital with improvement after having an extubation. However, after 3 days she revisited the emergency department with progressive dyspnea. The patient was diagnosed with OFTP from the results of chest CT and bronchoscopy. This is the first case studied in detail using CT images, pulmonary function test, and bronchoscopy.

Key Words: Trachea; Airway Obstruction; Fibrin; Stents

Case Report

A 68-year-old woman with ischemic heart disease presented with a 6-day history of progressive dyspnea. Her symptoms had been progressively worsening for 6 days before the admission. On the first admission, her blood pressure was 130/70 mm Hg, and the pulse rate was 100/min. She was diagnosed with acute pulmonary edema, and she had undergone invasive ventilator care with a high volume-low pressure cuffed tube (Hi-Lo™; Mallinckrodt Medical, Athlone, Ireland) for 24 hours. While incubating, the intra-cuff pressure was monitored, and it was stable to maintain below 25 cm H₂O. She improved, and the tube was removed immediately. She was discharged from the hospital on the 3rd day after extubation. After 3 days from being discharged, she re-

visited the emergency department with progressive dyspnea. On physical examination, breathing sound was coarse and stridor was auscultated on anterior neck. A chest CT scan was performed to search for an etiology

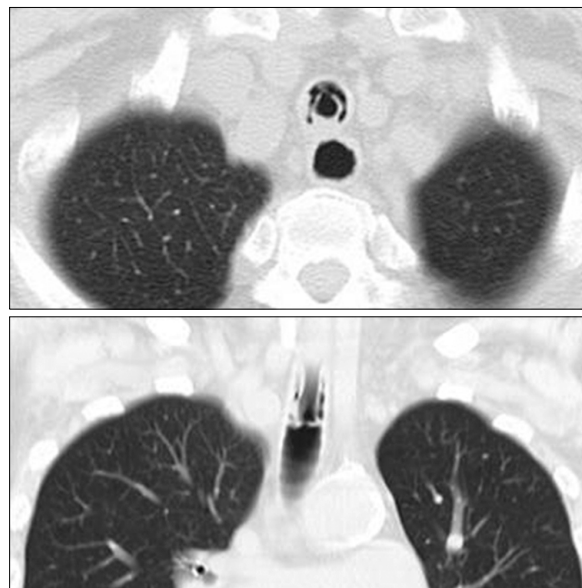

Figure 1. Chest axial and coronal CT images are showing tubular structure with a good patency. It looks like a tracheal stents at upper trachea. CT: computed tomography.

Address for correspondence: **Joong Hyun Ahn, M.D.**
Department of Internal Medicine, Incheon St. Mary's Hospital, The Catholic University of Korea College of Medicine, 665, Bupyeong 6-dong, Bupyeong-gu, Incheon 403-720, Korea
Phone: 82-32-280-5842, Fax: 82-32-280-5190
E-mail: ajhcmcim@catholic.ac.kr
Received: Apr. 27, 2011
Accepted: Jun. 28, 2011

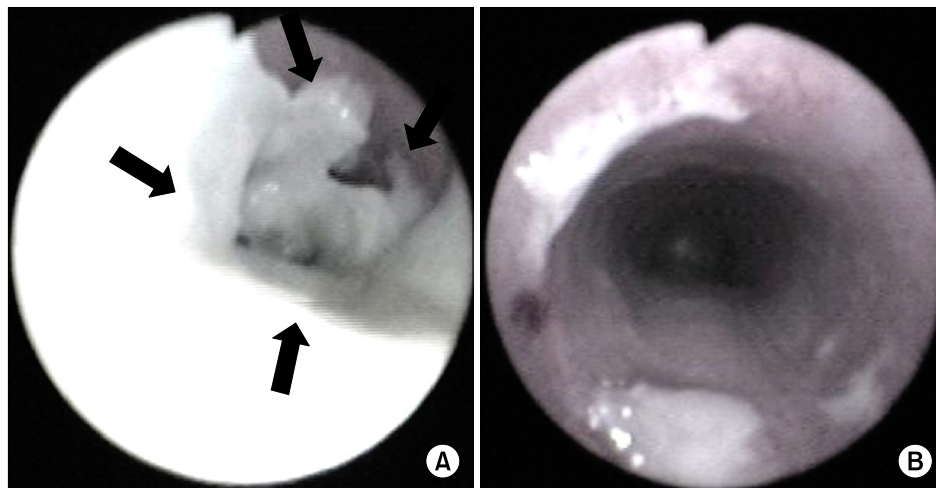


Figure 2. (A) Fiberoptic bronchoscopy showing a thick tubular, rubber-like, whitish pseudomembrane moulding covering 2~3 cm of the tracheal wall at the level of the endotracheal cuff (the *arrows* indicate the pseudomembrane partially detached from trachea). (B) Fiberoptic bronchoscopy showing good patency after mechanical ablation with fiberoptic bronchoscopy.

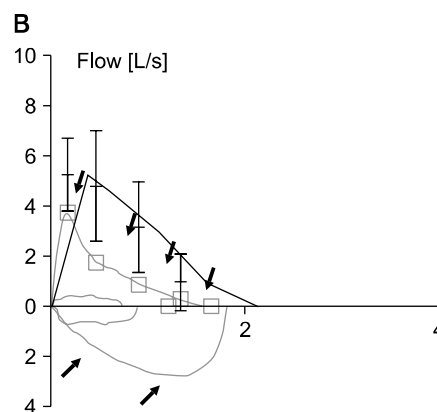
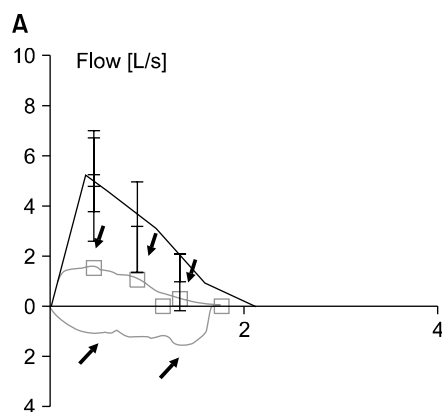


Figure 3. Flow-volume loops showed a fixed airway obstruction before mechanical removal of OFPT (the *arrows* indicate flow-volume loops) (A) and complete recovery of a fixed airway obstruction after mechanical removal of OFPT (B).

of tracheal stenosis. The chest CT showed tubular structure mimicking stents at upper trachea (Figure 1). Pulmonary function test showed fixed airway obstruction (Figure 2). A bronchoscopy was performed under moderate sedation and showed a thick tubular, rubber-like, whitish pseudomembrane moulding, covering 2~3 cm of the tracheal wall at the level of the previously placed endotracheal tube cuff (Figure 2). It was completely ablated without secondary development of tracheal stenosis using a fiberoptic bronchoscope and forceps alone. After the mechanical removal of OFTP using a fiberoptic bronchoscope and forceps alone, following pulmonary function test showed no limitation of airway flow (Figure 3). A bronchoscopy was performed

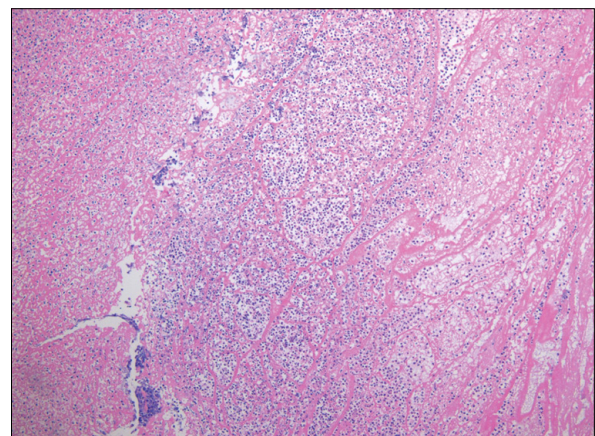


Figure 4. Microscopic examination showing that the pseudomembrane consists of fibrinous material with acute inflammatory cell infiltration (H&E stain, $\times 100$).

1 month later, but showed no residual lesion. The biopsy specimen showed fibrinous material with acute inflammatory cells (Figure 4).

Discussion

Obstructive fibrinous tracheal pseudomembrane (OFTP) is a potentially fatal complication of tracheal intubation, consisted of fibrinous material with acute inflammatory cell infiltration and respiratory failure^{1,2} with unknown causes. OFTP typically appears as sudden upper airway obstruction occurring shortly after extubation. The clinical feature may be various from subclinical airway obstruction to acute respiratory failure. The delay from extubation to initial symptoms varies from several hours to several days^{1,2}. So, it could be misled to the other causes of upper airway obstruction related to intubation such as acute retention of secretion, laryngospasm, glottic edema, and post-intubation tracheal stenosis. OFTP could sometimes be unrecognizable.

One possible cause of pathogenesis is a tracheal ischemic damage related to the cuff induced injury. According to the previous reports, the duration of intubation varies from 3 hours to 16 days. The delay from extubation to initial symptoms is anywhere between 3 hours to 9 days, and the delay from initial symptoms to diagnosis can be anywhere between <1 hour to 4

days¹. Fiberoptic bronchoscopy is the key for diagnosis. The treatment choice is mechanical ablation with fiberoptic or rigid bronchoscopy¹⁻⁴.

Unexplained respiratory failures with symptoms of upper airway obstruction, shortly after extubation, should lead to considering the diagnosis of OFTP. Learning points of this case are as following: 1) consider OFTP if unexplained respiratory failures occur shortly after extubation; 2) confirm the diagnosis of OFTP and ablate OFTP with bronchoscopy if OFTP is suspected.

References

1. Deslée G, Brichet A, Lebuffe G, Copin MC, Ramon P, Marquette CH. Obstructive fibrinous tracheal pseudomembrane. A potentially fatal complication of tracheal intubation. *Am J Respir Crit Care Med* 2000;162:1169-71.
2. Lins M, Dobbeleir I, Germonpré P, Waelput W, Pauwels P, Jorens PG. Postextubation obstructive pseudomembranes: a case series and review of a rare complication after endotracheal intubation. *Lung* 2011;189: 81-6.
3. Harbison J, Collins D, Lynch V, McNicholas WT. Acute stridor due to an upper tracheal membrane following endotracheal intubation. *Eur Respir J* 1999;14:1238.
4. Kang HH, Kim JW, Kang JY, Kim JS, Kim MS, Kim SS, et al. Obstructive fibrinous tracheal pseudomembrane after tracheal intubation: a case report. *J Korean Med Sci* 2010;25:1384-6.