

1

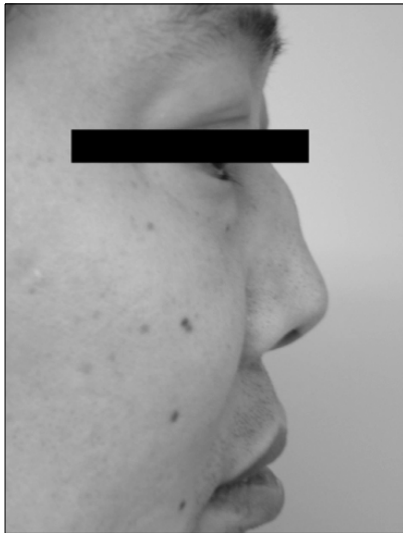

Figure 1. On patient's facial picture, a saddle nose is observed.

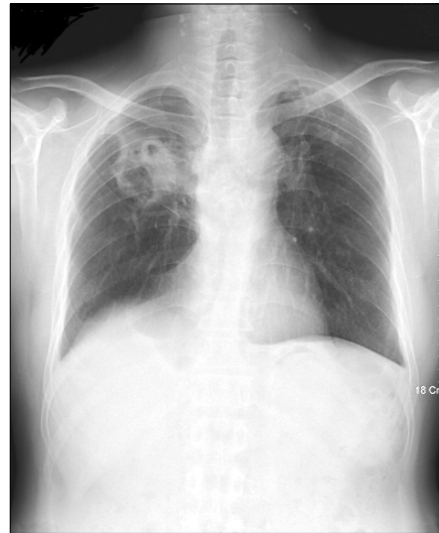

Figure 2. Chest radiography shows cavitary lung mass at the right upper lung field.

가 , 가 , 37 (infected bullae) , (chronic organizing pneumonia with fibrosis and necrosis) . C-ANCA (circulating antineutrophil cytoplasmic antibodies) . 42 2.0 mg/dL, 2.1 g/day, C-ANCA IgA (diffuse mesangial proliferative glomerulonephritis with focal necrotizing glomerulitis) 6 , 4 10 mg . , 가 신체검사 소견: 120/70 mmHg, 75 / , 20 / , 36.5°C , (Figure 1)가 . , (Figure 4).

검사실 소견: 8,770/mm³ (83.4%), 11.4 g/dL, 371,000/mm³ , aPTT 40.7 , PT 14.1 . AST 20 U/L, ALT 17 U/L, 6.8 mg/dL, 3.2 mg/dL, 39 mg/dL, 3.1 mg/dL, Na 141 mEq/L, K 5.1 mEq/L, Cl 108 mEq/L, 10.6 mg/dL, 9.1 mg/dL, 4.4 mg/dL . 1.015, pH 5.0, 0~1/HPF, 0~1/HPF , 24 143.5 mg/day, 34.2 mL/min , C-ANCA가 , P-ANCA (perinuclear antineutrophil cytoplasmic antibodies) 가 방사선학적 소견: 가 (Figure 2). 가 5.6×3.4 cm (Figure 3), (Figure 4). 임상 경과: 가

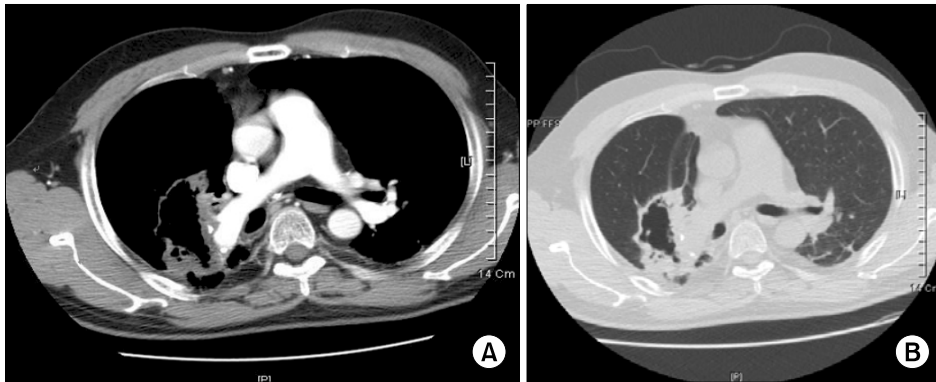


Figure 3. Chest CT scans show an irregular shaped mass consisted of various size of cavities with surrounding fibrosis and speckled margins (A; mediastinal setting view, B; lung setting view).

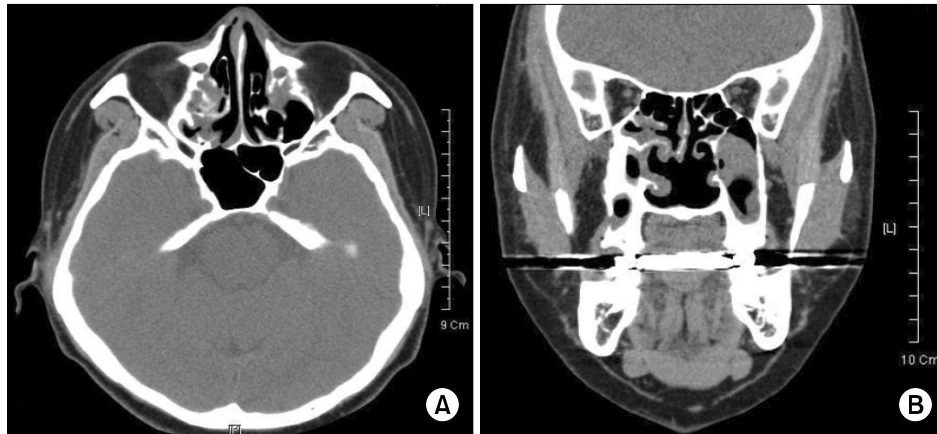


Figure 4. Facial CT shows small fluid density and thickening of bony wall in the right and left maxillary sinuses. Axial (A) and coronal (B) view.

수술 및 병리 소견:

5×4 cm 가
(Figure 5).

(histiocyte) (multinucleated giant cell)
(Figure 6)

치료 및 경과 관찰: 70 mg
125 mg , 1
C-ANCA

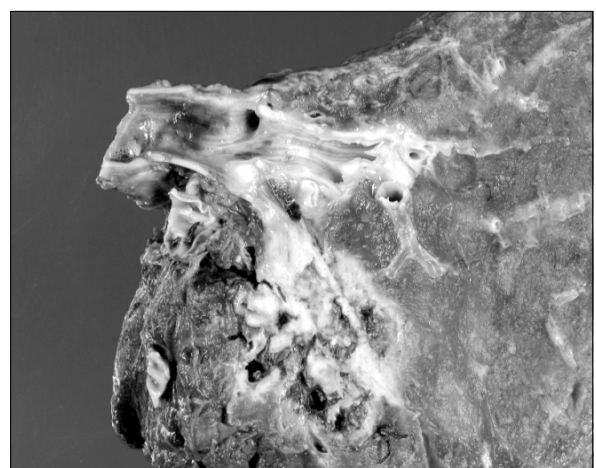


Figure 5. Cut surface shows a rather ill-defined mass, which is consisted of varying sized multiple cyst with dense fibrous walls in the middle lobe, measuring 5×4 cm in size.

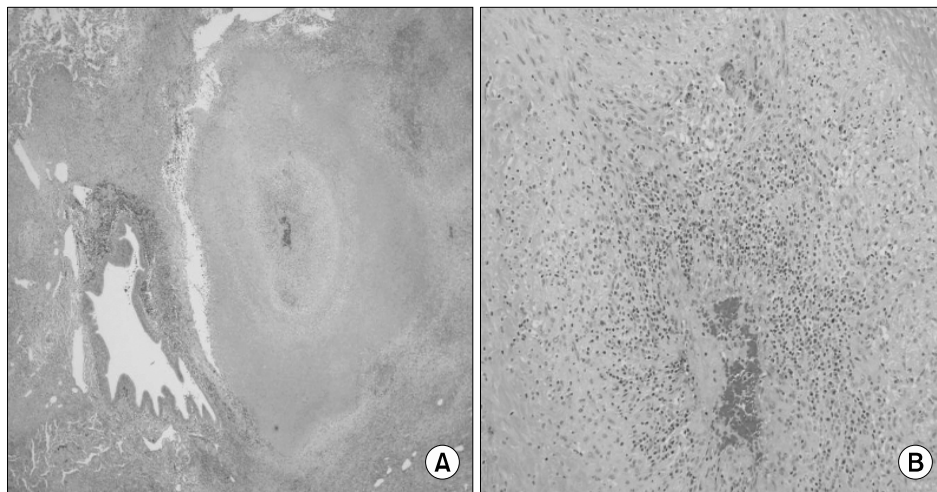


Figure 6. On microscopic examination, the granulomatous necrotizing vasculitis of large arteries and veins (A; H&E stain, $\times 200$), surrounded by irregular shaped fibrinous necrosis and histiocytes and multinucleated giant cells (B; H&E stain, $\times 400$).

고 찰

70% P-ANCA

가 (vasculitis and granulomatous inflammation)

50 가 25%

3 (leukocytoclastic vasculitis)

(necrotizing segmental glomerulonephritis)

8,9 Henoch-Schönlein

(leukocytoclastic vasculitis), IgA

2

4 가 가

(microscopic polyangiitis)

Henoch-Schönlein

5. Woodworth 68

C-ANCA

5

가

5,6

ANCA C-ANCA P-ANCA

90% C-ANCA

4 ~ 78

5
Miyata Henoch-Schönlein C-ANCA
(leukocytoclastic vasculitis) IgA 가
C-ANCA
Henoch-Schönlein 15
가 가
가
가 가
21
31 Henoch-Schönlein
가
가
C-ANCA가 37 42
42
(
가 ANCA Henoch-Schönlein
가 Henoch-Schönlein
IgA (3+)
IgA가 8

요 약

Henoch-Schönlein

IgA Henoch-Schönlein
, 15
1

참 고 문 헌

1. Duna GF, Galperin C, Hoffman GS. Wegener's granulomatosis. *Rheum Dis Clin North Am* 1995;21:949-86.
2. Miyata M, Kanno K, Nishimaki T, Sakuma F, Iwatsuki K, Kasukawa R. A patient with Wegener's granulomatosis with initial clinical presentations of Henoch-Schönlein purpura. *Intern Med* 2001;40:1050-4.
3. Stone JH; Wegener's Granulomatosis Etanercept Trial Research Group. Limited versus severe Wegener's granulomatosis: baseline data on patients in the Wegener's granulomatosis etanercept trial. *Arthritis Rheum* 2003;48:2299-309.
4. Cordier JF, Valeyre D, Guillevin L, Loire R, Brechot JM. Pulmonary Wegener's granulomatosis. A clinical and imaging study of 77 cases. *Chest* 1990;97:906-12.
5. Woodworth TG, Abuelo JG, Austin HA 3rd, Esparza A. Severe glomerulonephritis with late emergence of classic Wegener's granulomatosis. Report of 4 cases and review of the literature. *Medicine (Baltimore)* 1987;66:181-91.
6. Kallenberg CG, Brouwer E, Weening JJ, Tervaert JW. Anti-neutrophil cytoplasmic antibodies: current diagnostic and pathophysiological potential. *Kidney Int* 1994;46:1-15.
7. Seo P, Stone JH. The antineutrophil cytoplasmic antibody-associated vasculitides. *Am J Med* 2004;117:39-50.
8. Hauer HA, Bajema IM, van Houwelingen HC, Ferrario

F, Noël LH, Waldherr R, et al. Renal histology in ANCA-associated vasculitis: differences between diagnostic and serologic subgroups. *Kidney Int* 2002;61:80-9.

9. Schnabel A, Holl-Ulrich K, Dalhoff K, Reuter M, Gross WL. Efficacy of transbronchial biopsy in pulmonary vasculitides. *Eur Respir J* 1997;10:2738-43.
