

A Case of Bronchoscopic Treatment of a Bronchopleural Fistula Accompanied by Pneumonia

Hyoungrae Kim, M.D.

Department of Radiology, Donghae Hospital, Workers Accident Medical Cooperation, Donghae, Korea

A bronchopleural fistula (BPF) is traditionally treated by surgery, but currently various noninvasive forms of management, particularly the use of bronchoscopy, have been utilized. The substances and methods for noninvasive management of a BPF differ with individual clinicians. This case describes the use of flexible bronchoscopic treatment of a BPF complicating pneumonia using embolization coils and intraluminally injected fibrin glue. If the BPF is small and is located on the peripheral bronchus, this minimal invasive maneuver could be recommended for the treatment of a BPF. (*Tuberc Respir Dis* 2007;63:507-510)

Key Words: Bronchopleural fistula, Bronchoscopy, Coil, Fibrin glue

증례

환자: 62
주소: , 가
현병력: ,
가 가
2
가
가
과거력: .
사회력: , 3 3
1
직업력:
진찰소견: 110/70 mmHg, 110/ ,
28 / , 38.8°C ,
검사실 소견: 16,000/mm³,
10.5 g/dl, 30.5%, 140,000/
mm³ . 5 L
가 pH 7.31, PaCO₂ 31.3
mmHg, PaO₂ 71.2 mmHg, HCO₃⁻ 25.6 mEq/L, SaO₂
91.2% . 110 /
가 320 mg/dl,
HbA1c 7.8%
방사선 소견:
(Figure 1).
임상 경과: *Klebsiella pneumoniae*
*Streptococcus pyogenes*가
3 가
가
(Figure 2).
기관지 내시경:

Address for correspondence: Hyoungrae Kim, M.D.
Department of Radiology, Donghae Hospital, 190, Pyeong-neung-dong, Donghae 240-714, Korea
Phone: 033-520-3244, Fax: 033-532-3136
E-mail: fivos@unitel.co.kr
Received: Dec. 11, 2007
Accepted: Dec. 13, 2007

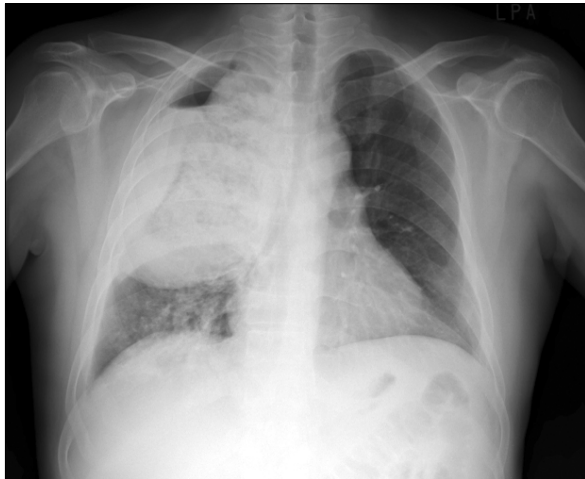


Figure 1. Initial chest X-ray finding of the patient: necrotizing pneumonia accompanying bronchopleural fistula in right upper lobe,

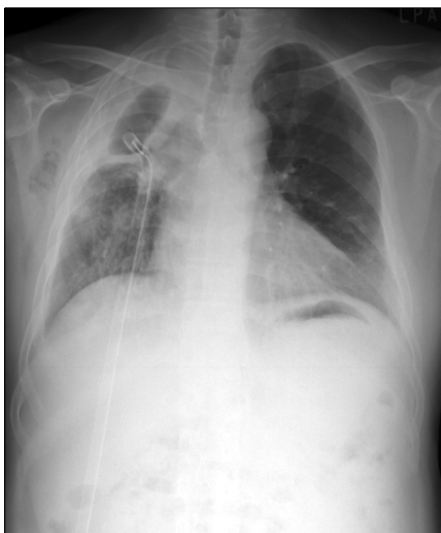

Figure 2. At three weeks after systemic antibiotics and closed thoracostomy for the treatment of bronchopleural fistula and necrotizing pneumonia, chest X-ray showed persistent dead space of right upper lobe. Also, minimal subcutaneous emphysema was noted in right axillary area,

비침습적 치료:

coil

fibrin glue

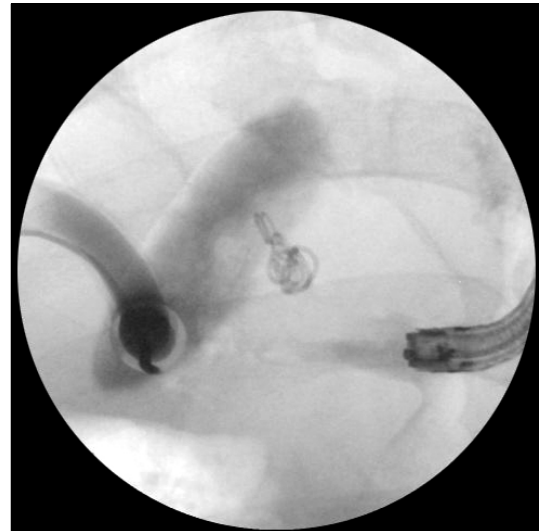


Figure 3. Intraoperative X-ray finding during bronchoscopic coiling for treatment of bronchopleural fistula: there was no gastrograffin leakage into diseased bronchopleural tract after coiling and injection of glue. Before procedures, gastrograffin was used for localization of bronchopleural fistula tract, so small amount of leaked gastrograffin in both the dead space and chest tube is visible,

gastrograffin

port 3

coil (Cook, Bloomington, USA)

C-arm

brin glue (, ,)

glue가

Swan-Ganz

5

gastrograffin

(Figure 3).

치료 후 경과: 2

5

7

coli glue

10

14

9

(Figure 4A).

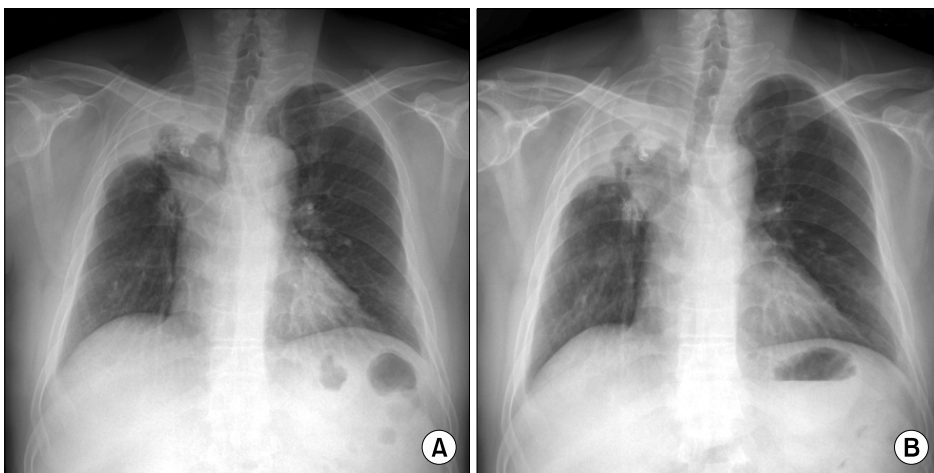


Figure 4. (A) Chest X-ray at discharge showed inserted coils into bronchopleural fistula and small amount of dead space and moderate pleural thickenings. (B) At 9 months postoperatively, chest x-ray revealed decreased pleural thickenings and well anchored coils in the bronchopleural fistula tract.

[illegible]

8 mm

참 고 문 헌

1. Puskas JD, Mathisen DJ, Grillo HC, Wain JC, Wright CD, Moncure AC. Treatment strategies for bronchopleural fistula. *J Thorac Cardiovasc Surg* 1995;109:989-95.
2. Lois M, Noppen M. Bronchopleural fistulas: an overview of the problem with special focus on endoscopic management. *Chest* 2005;128:3955-65.
3. Galetta D, Veronesi G, Solli P, Petrella F, Borri A, Gasparri R, et al. A safe and effective method for an immediate bronchopleural fistula repair. *Minerva Chir* 2007;62:137-9.
4. Hartmann W, Rausch V. New therapeutic application of the fiberoptic bronchoscope. *Chest* 1997;71:237.
5. Na KJ, Kim BP, Hong SB, Choi YS, Kim SH, Ahn BH. Endobronchial closure of postoperative bronchopleural fistula using vascular occluding coils. *Korean J Thorac Cardiovasc Surg* 2005;38:72-5.
6. Choi YI, Cho JH, Shim JY, Sheen SS, Oh YJ, Park JH, et al. A case of RUL bronchopleural fistula occluded by flexible bronchoscope with Endobronchial Watanabe Spigot (EWS). *Tuberc Respir Dis* 2005;58:404-9.
7. Varoli F, Roviato G, Grignani F, Vergani C, Maciocco M, Rebuffat C. Endoscopic treatment of bronchopleural fistulas. *Ann Thorac Surg* 1998;65:807-9.

gastrograffin

coil glue

coil

glue

coil

가

coil fibrin

glue

요 약

가

가