

조경욱, 홍윤기, 한정혜, 이재근, 홍상범

A Case of Pulmonary Artery-bronchial Fistula with Massive Hemoptysis due to Pulmonary Tuberculosis

Kyung-Wook Jo, M.D., YoonKi Hong, M.D., Jung-Hye Han, M.D., Jae-Keun Lee, M.D.,
Sang-Bum Hong, M.D.

Division of Pulmonary and Critical Care Medicine, University of Ulsan College of Medicine, Asan Medical Center, Seoul, Korea

Massive and untreated hemoptysis is associated with a >50% mortality rate. Since bleeding has a bronchial arterial origin in most patients, bronchial artery embolization (BAE) has become an accepted treatment in massive hemoptysis. The possibility of bleeding from pulmonary artery should be considered in patients in whom the bleeding focus cannot be found by Bronchial angiogram. Indeed, the bleeding occurs from a pulmonary artery in approximately 10% of patients with massive hemoptysis. The most common causes of bleeding from the pulmonary artery are pulmonary artery rupture associated with a Swan-Ganz catheter, infectious diseases and vasculitis. We report a rare case of a fistula between the right upper lobar pulmonary artery and the right upper lobar bronchus in a 71-year-old woman who presented with massive hemoptysis. (*Tuberc Respir Dis* 2007;63: 430-434)

Key Words: Pulmonary artery-bronchial fistula, Massive hemoptysis

서 론

10%⁵, Swan-Ganz
가
1. 6.
24 100~600 ml 1 가 7,
2.
3,
30~50% 가 8,9
가 4.

증 례

환 자: 71

주 소:

현병력: 6

, 1

4, 5 . 300 ml

Address for correspondence: Sang-Bum Hong, M.D.
Division of Pulmonary & Critical Care Medicine,
University of Ulsan College of Medicine, Asan Medical
Center, 388-1, Pungnap-dong, Songpa-gu, Seoul 138-736,
Korea
Phone: 82-2-3010-3893, Fax: 82-2-3010-6968
E-mail: sbhong@amc.seoul.kr

Received: Sep. 10, 2007

Accepted: Oct. 15, 2007

과거력: 10

가족력:

사회력:

신체검사 소견: 125/90 mmHg, 132
36.7°C

검사실 소견: 11.3 g/dL,
20,400/mm³ (neutrophil 58%, lymphocyte
31%), 259,000/mm³ 5.5
g/dL, 2.9 g/dL, 0.8 mg/dL, AST 24
IU/L, ALT 12 IU/L, BUN 9 mg/dL, creatinine 0.6 mg/dL,
prothrombin time (INR) 1.15, aPTT 30.5 sec, ESR 126
mm/hr, CRP 22.5 mg/dL . FiO₂ 0.4
가 pH 7.439, pCO₂ 28.7 mmHg, pO₂
53.1 mmHg, Bicarbonate 19.0 mEq/L .

방사선학적 소견:

(Figure 1).

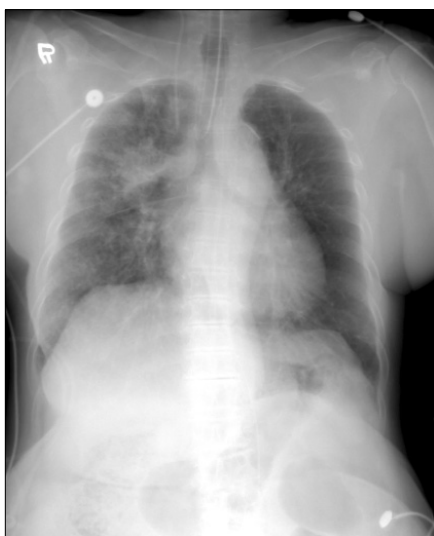

Figure 1. The chest radiography showed consolidation combined with linear opacity on right upper lobe.

(anthracofibrosis)
2
(Figure 2).

치료 및 경과: 200 ml

30

가

100~200 ml

가

가

가

가

(Figure 3),

가

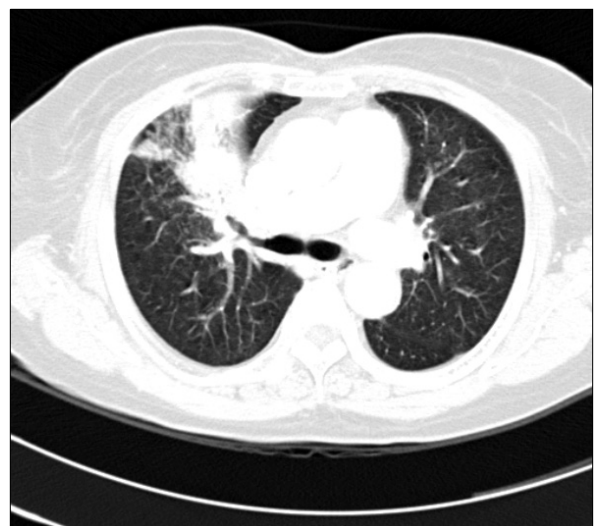

Figure 2. Chest computed tomography scan showed air-space consolidation and multiple centrilobular nodules in right upper and middle lobe with irregular luminal narrowing of anterior segmental bronchi of right upper lobe.

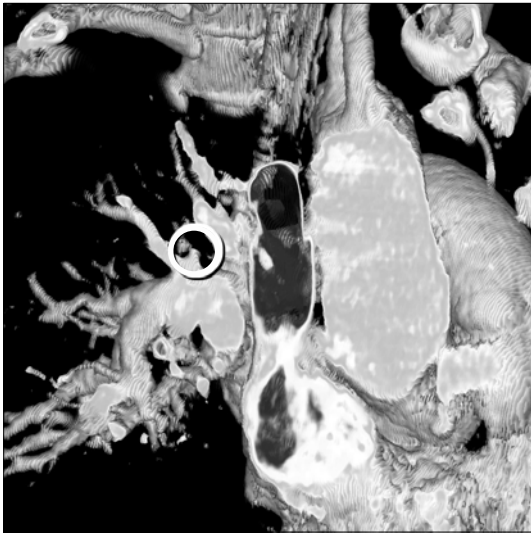

Figure 3. Reconstructed pulmonary embolism CT demonstrated a small sacular aneurysm in proximal portion of the segmental branch, right upper lobar pulmonary artery and diffuse bronchial wall thickening in right main and upper lobar bronchus.

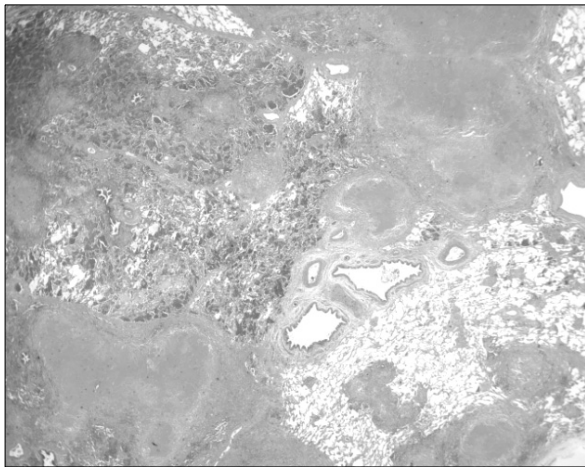


Figure 4. Lung biopsy showed chronic granulomatous inflammation with caseous necrosis, nonspecific interstitial fibrosis, inflammatory infiltration with airspace organization.

병리학적 소견:

TB-PCR

(Figure 4).

고 찰

11, 12, 13, 10,
14,
27%
15, 16,
가 ,
가 ,
7, 가 ,
가 9.

3

9

8

,

,

17

18

가

가

10%

5.

,

,

16.

가

가

,

1. Hirshberg B, Biran I, Glazer M, Kramer MR. Hemoptysis: etiology, evaluation, and outcome in a tertiary referral hospital. *Chest* 1997;112:440-4.
2. Thompson AB, Teschler H, Rennard SI. Pathogenesis,

- 433

- 2002;22:345-51.
17. Oh JY, Lee SW, Kang YA, Yoon YS, Yoo CG, Kim YW, et al. Bronchial artery embolization in patients with hemoptysis: outcome and predictors of success. *Kor J Med* 2005;68:400-6.
 18. Swanson KL, Johnson CM, Prakash UB, McKusick MA, Andrews JC, Stanson AW. Bronchial artery embolization: experience with 54 patients. *Chest* 2002;121:789-95.
 19. Erkan F, Gul A, Tasali E. Pulmonary manifestations of Behcet's disease. *Thorax* 2001;56:572-8.
 20. Sanyika C, Corr P, Royston D, Blyth DF. Pulmonary angiography and embolization for severe hemoptysis due to cavitary pulmonary tuberculosis. *Cardiovasc Intervent Radiol* 1999;22:457-60.
-