

¹ 박혜경¹, 강윤정¹, 최상봉¹, 박이내¹, 정 훈¹, 허진원¹, 이현경¹, 염호기¹, 이혁표¹, 장지민², 김정숙³, 최수전¹

A Case of Pulmonary Edema by Idiopathic Rupture of Mitral Chordae Tendinae

Hye Kyeong Park, M.D.¹, Yeun Jeong Kang, M.D.¹, Sang Bong Choi, M.D.¹, I Nae Park, M.D.¹, Hoon Jeung, M.D.¹, Jin Won Hur, M.D.¹, Hyun Kyung Lee, M.D.¹, Ho Kee Yum, M.D.¹, Hyuk Pyo Lee, M.D.¹, Ji Min Jang, M.D.², Joung Sook Kim, M.D.³, Soo Jeon Choi, M.D.¹

Departments of ¹Internal Medicine, ²Chest Surgery, ³Radiology, Inje University College of Medicine, Paik Hospital, Seoul, Korea

The typical radiographic findings of pulmonary edema from the increased hydrostatic pressure shows centrally localized consolidation, which is known as a "butterfly or bat's wing" pattern. These terms describe the anatomic distribution of edema that uniformly involve the hilum and medulla of the lung but not the peripheral region of the lung parenchyma (cortex). We present a case of butterfly wing-like pulmonary edema on a chest radiograph by mitral regurgitation due to an idiopathic chordal rupture. (*Tuberc Respir Dis* 2007;63:458-461)

Key Words: Pulmonary edema, Mitral regurgitation, Chordae tendineae

서 론

가

가

가가

과거력:

개인력: 30

사회력: 15

신체검사: , 110/86 mmHg,

24 /min, 86 /min, 37.5°C ,

1

3/6

증 례

환 자: O , , 46

주 소: ,

현병력: 2 ,

검사실 소견: 가 pH

7.5, PCO₂ 26 mmHg, PO₂ 61 mm Hg, HCO₃⁻ 22 mEq/L,

SaO₂ 95% , 13.0 g/dL,

13,000/mm³ (73%, 20.5%,

0.2%), 229,000/mm³ .

3.0 mg/dL, AST 45 U/L, ALT 30 U/L,

5.6 g/dL, 3.1 g/dL . PT , CRP

23.5 mg/dL , .

방사선 소견: 가

가가 ,

Address for correspondence: Soo Jeon Choi, M.D.
Department of Internal Medicine, Inje University College of
Medicine, Sanggye-Paik Hospital, 761, Sanggye 7-dong,
Nowon-gu, Seoul 139-707, Korea
Phone: 82-2-950-1990, Fax: 82-2-950-1955
E-mail: choijs@sanggyepaik.ac.kr

Received: Aug. 31, 2007

Accepted: Oct. 26, 2007

가 (Figure 1).
 심장 초음파 소견: 가 ,
 4.5 cm, 70% .
 (Figure 2).
 임상 경과: 가 .

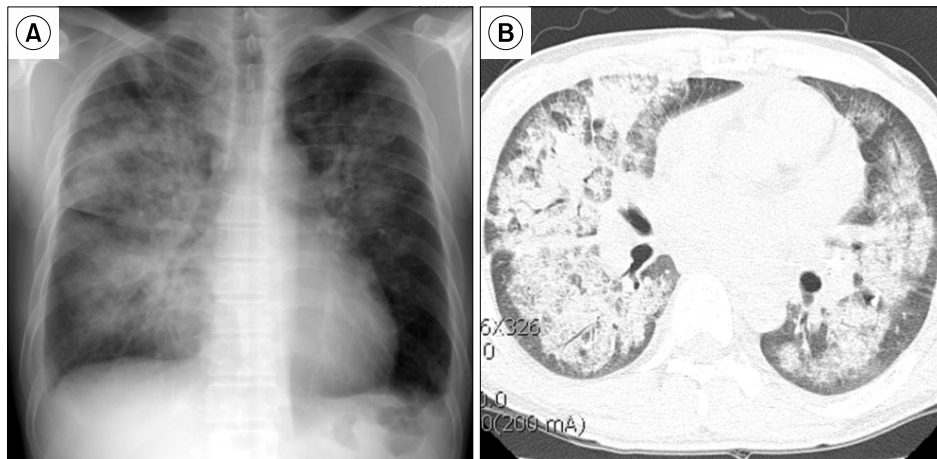


Figure 1. (A) Chest PA shows bilateral peribronchovascular thickening more prominent in right lung with small amount of pleural effusion in both costophrenic angles. (B) Thin-section Chest CT demonstrates bilateral diffuse consolidation and ground glass opacities sparing subpleural lung zone.

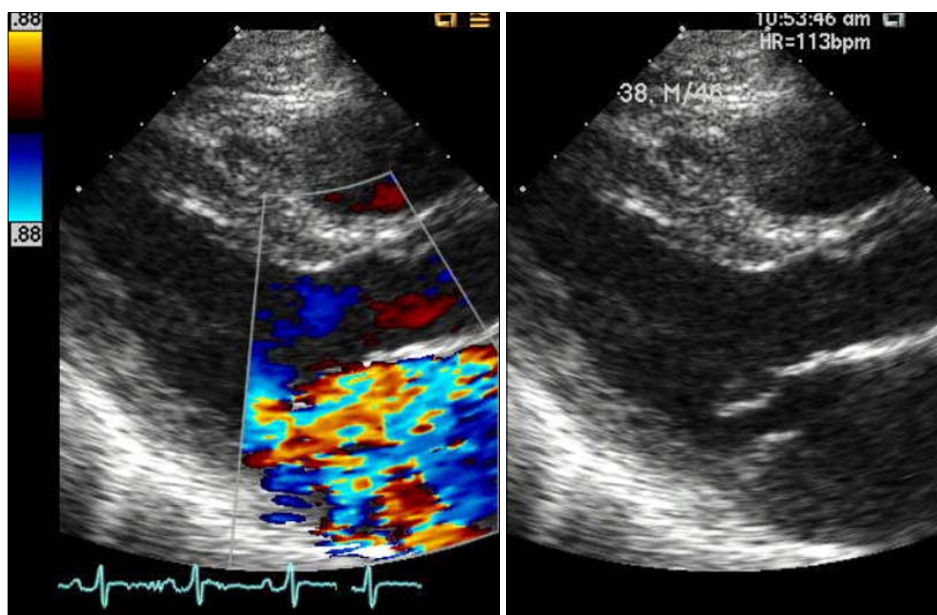


Figure 2. Long-axis parasternal view of two-dimensional echocardiogram during early systole demonstrates mitral regurgitant jet flow toward the left atrial appendage and mitral valve prolapse.

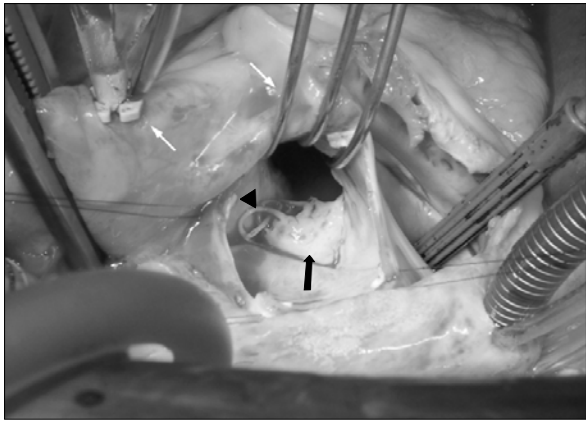


Figure 3. Thoracotomy view reveals the posterior leaflet of mitral valve (arrow) and multiple rupture of chordae tendinae (arrowhead).

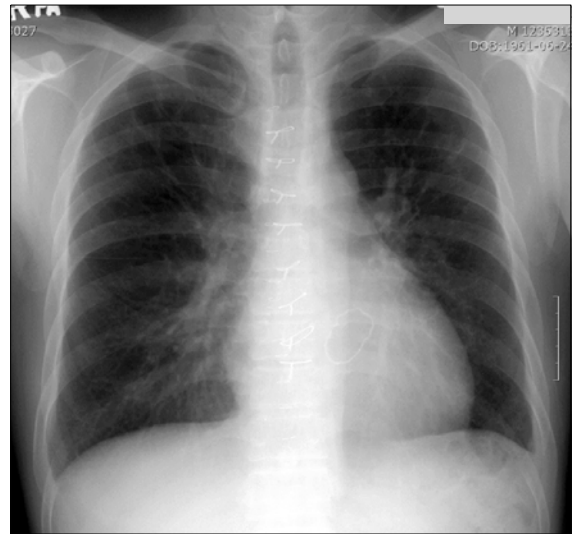


Figure 4. Follow-up chest PA after mitral valve replacement and chordal repair shows decreased cardiomegaly with near completely resorbed pulmonary edema and pleural effusion.

(Figure 3).

(Figure 4)

고 찰

2~3 cm

. Rajindar⁸

가 7

가 1.

("butterfly" or "bat's wing" pattern)

가

가

가

1.

2~3 cm

가

요 약

1

가

2.

가 36.

가

7.

참 고 문 헌

1. Ku JM, Chung JW. Chapter 9 Pulmonary edema and hypertension. In: Lim JK, Lee KS, editors. Thoracic radiology. Seoul: Ilchokak; 2000. p. 303-16.
2. Chapter 51 Pulmonary edema. In: Fraser RS, Muller NL,

- Colman NC, Pare PD, editors. Fraser and Pare's diagnosis of diseases of the chest. 4th ed. Montreal: Saunders; 1999. p. 1958-73.
3. Gurney JW, Goodman LR. Pulmonary edema localized in the right upper lobe accompanying mitral regurgitation. *Radiology* 1989;171:397-9.
 4. Schnyder PA, Sarraj AM, Duvoisin BE, Kapenberger L, Landry MJ. Pulmonary edema associated with mitral regurgitation: prevalence of predominant involvement of the right upper lobe. *Am J Roentgenol* 1993;161:33-6.
 5. Young AL, Langston CS, Schiffman RL, Shortsleeve MJ. Mitral valve regurgitation causing right upper lobe pulmonary edema. *Tex Heart Inst J* 2001;28:53-6.
 6. Grenon H, Bilodeau S. Pulmonary edema of the right upper lobe associated with acute mitral regurgitation. *Can Assoc Radiol J* 1994;45:97-100.
 7. Alarcon JJ, Guembe P, de Miguel E, Gordillo I, Abellas A. Localized right upper lobe edema. *Chest* 1995;107:274-6.
 8. Singh R, Schrank JP, Nolan SP, McGuire LB. Spontaneous rupture of mitral chordae tendinae. *JAMA* 1972;219:189-93.
-