

김은미¹, 김상하¹, 권우철², 김호영¹, 김종환¹, 이부길¹, 정순희³, 이종국⁴, 용석중¹

The Remission of Pure Red Cell Aplasia with a Thymoma after Surgical Resection

Eun Mi Kim, M.D.¹, Sang-Ha Kim, M.D.¹, Woocheol Kwon, M.D.², Ho Young Kim, M.D.¹, Chong Whan Kim, M.D.¹, Bu Ghil Lee, M.D.¹, Soon-Hee Jung, M.D.³, Chong Kook Lee, M.D.⁴, Suk Joong Yong, M.D.¹

Departments of ¹Internal Medicine, ²Radiology, ³Pathology and ⁴Thoracic and Cardiovascular Surgery, Yonsei University Wonju College of Medicine, Wonju, Korea

Thymomas are associated with different paraneoplastic syndromes, with the most clinically important association being with myasthenia gravis, hypogammaglobulinemia, and pure red cell aplasia (PRCA). The optimal therapy for PRCA that complicates a thymoma is unknown, given the rarity of the clinical situation. It has been suggested that remission following surgery alone is uncommon and most patients will require some other form of therapy. We report a case of PRCA with a thymoma in a 59-year-old man who remained in complete remission of the PRCA after surgical resection of the thymoma. (*Tuberc Respir Dis* 2007;63:454-457)

Key Words: Thymoma, Pure red cell aplasia, Surgery

서 론

가
100,000 0.15
1/3
(pure red cell aplasia, PRCA)
30 ~ 50%
10%, PRCA 5%
가
1 6 PRCA 1

증 례

환 자: ○○, 59
주 소:
현병력: 3 5
과거력: 2 3
가족력:
사회력 및 직업력: 30
진찰 소견: 95/58 mmHg,
85 , 18 , 36.8°C
검사실 소견: 3
9,360/mm³, 15.4 g/dL,

Address for correspondence: Suk Joong Yong, M.D.
Department of Internal Medicine, Yonsei University Wonju
College of Medicine, 162, Ilsan-dong, Wonju 220-701, Korea
Phone: 82-33-741-0926, Fax: 82-33-746-4667
E-mail: sjyong@yonsei.ac.kr
Received: Aug. 31, 2007
Accepted: Oct. 29, 2007

45.6%, 244,000/mm³.
 5,590/mm³ (55.0%,
 37.1%, 4.3%, 1.7%), 3.5 g/dL,
 10.5%, 92.8 fL,
 31.3 pg, 33.8 g/dL,
 371,000/mm³ 231 µg/dL,
 233 µg/dL, ferritin 666 ng/mL,
 0.68% . Coombs
 5.8 g/dL,
 3.6 g/dL, AST 10 U/L, ALT 8 U/L, alkaline phosphatase
 71 U/L, γGT 12U/L, 0.2 mg/dL, BUN 12 mg/
 dL, 0.8 mg/dL,
 139 mEq/L, 4.6 mEq/L, 111 mEq/L .
 IgG 705 mg/dL, IgM
 321 mg/dL, IgA 167 mg/dL, CD4 T
 23.4%, CD8 T 46.9% CD4 : CD8 0.50 (:
 1.3~2.3) 1:40
 11 IU/mL .
 parvovirus B19 IgM , par-
 vovirus B19 (polymerase chain re-
 action)
 (erythropoietin) 300 mU/mL 가
 40% .

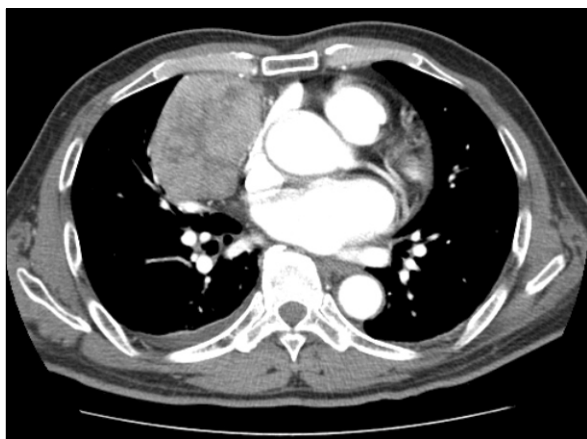


Figure 1. Contrast enhanced chest CT shows 7.3×5.3 cm, oval shape, well-defined mass within anterior mediastinum. The mass shows heterogeneous enhancement without evidence of invasion through capsule or involvement of nearby structures.

M : E 77.9 : 1 .

방사선 소견:

8 cm 가 가 .
 가 가
 가 ,
 (Figure 1).

병리학적 소견:

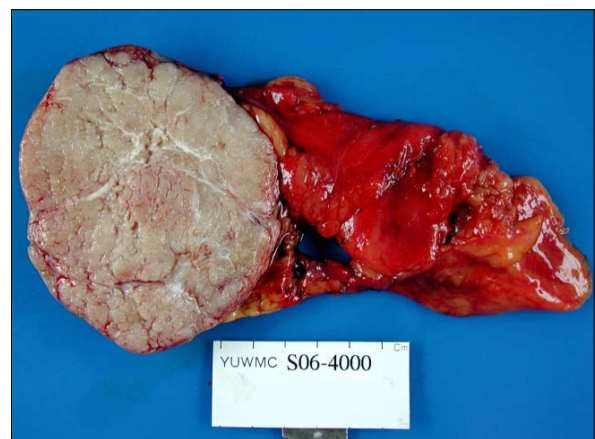


Figure 2. Gross appearance reveals an oval solid mass having homogenous pink-white meaty lobules separated by fibrous band.

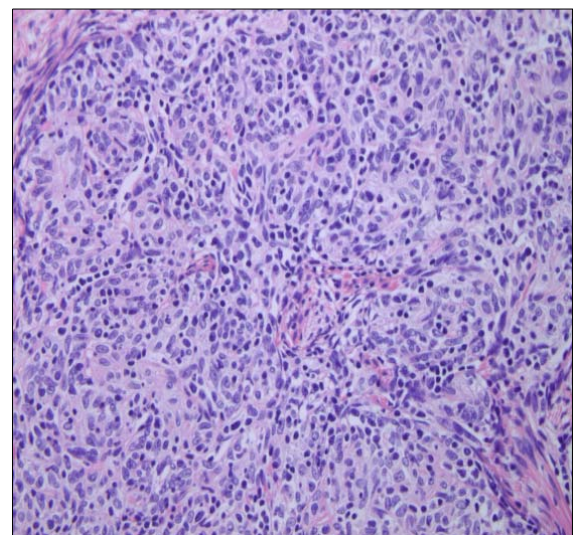


Figure 3. The tumor is composed of epithelioid cells with spindle nuclei and pale chromatin and admixed small lymphocytes (H&E stain, ×400).

9×7×6.5 cm , 가 , T 가 Th2 가 (Figure 8. octreotide 가 CD4 : CD8 가 0.96 type AB (Figure 3), Masaoka 1 , T CD4 : CD8 가 0.50 T CD8 치료 및 경과: 가 T 가 PRCA 16 PRCA parvovirus B19 2 6 11.2 g/dL , 가 , , phenytoin, azathioprine, isoniazid 14.3 g/dL . , , 10. , parvovirus B19 2/3 가 가 1/3 가 3.5 g/dL , 50 13 , 3. , 6.1 g/dL 4 가 7. 5 가 2. , 가 10% 11. PRCA Masaoka 4, 1 76.5% 가 가 , 2 Masaoka 12.5%, 3 12.5% , WHO type B 가 type A AB 12. type C PRCA WHO PRCA PRCA 가 PRCA WHO PRCA (erythroblast) 가 가 PRCA 가 PRCA T Th1/Th2 가 6 3 4 , 11 , 2

3 가 13 16 14 ,
12
가 가 가 PRCA 7 가
가 11.0 g/dL
가
danazol, cyclosporine, anti-thymocyte globulin, azathioprine, cyclophosphamide, androgens, rituximab,
7
PRCA가 가 , 가

요 약

, PRCA
1 6 가 11.0 g/dL
PRCA

참 고 문 헌

1. Duwe BV, Sterman DH, Musani AI. Tumors of the mediastinum. *Chest* 2005;128:2893-909.
2. Verstandig AG, Epstein DM, Miller WT, Aronchik JA, Geffer WB, Miller WT. Thymoma-report of 71 cases and a review. *Crit Rev Diagn Imaging* 1992;33:201-30.
3. Lewis JE, Wick MR, Scheithauer BW, Bernatz PE, Taylor WF. Thymoma. A clinicopathologic review. *Cancer* 1987;60:2727-43.
4. Masaoka A, Hashimoto T, Shibata K, Yamakawa Y, Nakamae K, Iizuka M. Thymoma associated with pure red cell aplasia. Histologic and follow-up studies. *Cancer* 1989;64:1872-8.
5. Böttiger LE, Rausing A. Pure red cell anemia: immunosuppressive treatment. *Ann Intern Med* 1972;76:593-7.
6. al-Mondhiry H, Zanjani ED, Spivack M, Zalusky R, Gordon AS. Pure red cell aplasia and thymoma: loss of serum inhibitor of erythropoiesis following thymectomy. *Blood* 1971;38:576-82.
7. Thompson CA, Steensma DP. Pure red cell aplasia associated with thymoma: clinical insights from a 50-year single-institution experience. *Br J Haematol* 2006;135:405-7.
8. Fujisao S, Tsuda H. Th1/Th2 balance alteration in the clinical course of a patient with pure red cell aplasia and thymoma. *Br J Haematol* 1998;103:308-10.
9. Palmieri G, Lastoria S, Colao A, Vergara E, Varrella P, Biondi E, et al. Successful treatment of a patient with a thymoma and pure red-cell aplasia with octreotide and prednisone. *N Engl J Med* 1997;336:263-5.
10. Fisch P, Handgretinger R, Schaefer HE. Pure red cell aplasia. *Br J Haematol* 2000;111:1010-22.
11. Kuo T, Shih LY. Histologic types of thymoma associated with pure red cell aplasia: a study of five cases including a composite tumor or organoid thymoma associated with an unusual lipofibroadenoma. *Int J Surg Pathol* 2001;9:29-35.
12. Detterbeck FC. Clinical value of the WHO classification system of thymoma. *Ann Thorac Surg* 2006;81:2328-34.
13. Hirst E, Robertson TI. The syndrome of thymoma and erythroblastopenic anemia. A review of 56 cases including 3 case reports. *Medicine (Baltimore)* 1967;46:225-64.
14. Zeok JV, Todd EP, Dillon M, DeSimone P, Utley JR. The role of thymectomy in red cell aplasia. *Ann Thorac Surg* 1979;28:257-60.