

1, 2, 3, 4  
 주진영<sup>1,2</sup>, 조재영<sup>2</sup>, 임정환<sup>1,2</sup>, 조계중<sup>2</sup>, 채동렬<sup>2</sup>, 오인재<sup>1,2</sup>, 김규식<sup>1,2</sup>, 김유일<sup>2</sup>, 임성철<sup>2</sup>, 김영철<sup>1,2</sup>, 송상운<sup>1,3</sup>, 나국주<sup>1,3</sup>,  
 김윤현<sup>1,4</sup>, 김재규<sup>4</sup>

## Two Cases of Fractured and Embolized Implanted Central Venous Chemoports in Lung Cancer

Jin Yung Ju, M.D.<sup>1,2</sup>, Jae Yeong Cho, M.D.<sup>2</sup>, Jung Hwan Lim, M.D.<sup>1,2</sup>, Gye Jung Cho, M.D.<sup>2</sup>,  
 Dong Ryeol Chae, M.D.<sup>2</sup>, In Jae Oh, M.D.<sup>1,2</sup>, Kyu Sik Kim, M.D.<sup>1,2</sup>, Yu Il Kim, M.D.<sup>2</sup>, Sung Chul Lim, M.D.<sup>2</sup>,  
 Young Chul Kim, M.D.<sup>1,2</sup>, Sang Yoon Song, M.D.<sup>1,3</sup>, Kook Ju Na, M.D.<sup>1,3</sup>, Yun Hyun Kim, M.D.<sup>1,4</sup>,  
 Jae Kyu Kim, M.D.<sup>4</sup>

<sup>1</sup>Lung and Esophageal Cancer Clinic, Chonnam National University Hwasun Hospital, Hwasun, Departments of <sup>2</sup>Internal Medicine,  
<sup>3</sup>Thoracic & Cardiovascular Surgery and <sup>4</sup>Diagnostic Radiology, Chonnam National University Medical School, Gwangju, Korea

Totally implanted central venous access devices for chemotherapy (chemoport) are being used increasingly in lung cancer patients. Vascular catheters are associated with various complications including infection, thrombosis as well as spontaneous fractures and embolization of the catheter, which is known as 'pinch-off syndrome'. 'Pinch-off syndrome' refers to the compression of a subclavian central venous catheter between the clavicle and first rib resulting in an intermittent or permanent obstruction, which can lead to tears, transection, or embolization. We report two cases of fractured and embolized implanted subclavian venous catheters in which the fragments were removed percutaneously. A 62-year-old man presented with back pain with a duration of a few weeks. The chest radiograph revealed complete transection and embolization of the catheter into the right atrium. In addition, a 47-year-old woman with a chemoport had a grade 3 pinch-off sign in a chest radiograph demonstrating complete transection and embolization of the catheter into the pulmonary artery. Both cases were managed by retrieving the embolized distal fragment percutaneously and removing the proximal section of the catheter. (*Tuberc Respir Dis* 2007;63:449-453)

**Key Words:** Chemoport, Pinch-off syndrome, Pinch-off sign

### 서 론

2

(chemoport)

가 가

증 례

증례 1

환 자: OO ( , 62 )

주 소:

과거력 및 가족력:

사회력: 80 , 3

현병력: IIIA

1

1 6

2

2006 5

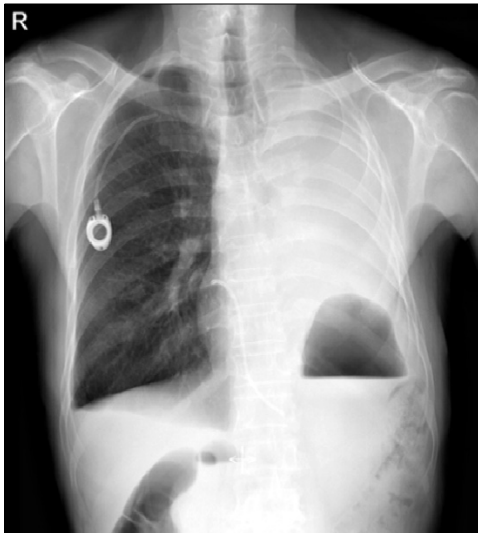
10

Address for correspondence: In Jae Oh, M.D.  
 Lung and Esophageal Cancer Clinic, Chonnam National  
 University Medical School and Hwasun Hospital, 160, IIsim-  
 ri, Hwasun-gun, Jeonnam 519-809, Korea  
 Phone: 82-61-379-7616, Fax: 82-61-379-7628  
 E-mail: droij@chonnam.ac.kr

Received: Jul. 25, 2007

Accepted: Oct. 11, 2007

가 36.3°C .  
 2007 4  
 이학적 소견: ,  
 170/100 mmHg, 68/min, 24/min, ,  
 검사실 소견: 6,100/mm<sup>3</sup>, 11.6 g/dl,  
 35.8%, 254,000/mm<sup>3</sup> ,  
 514 mg/dl, FDP 7.1 ug/dl, D-dimer  
 0.61 mg/L 가 .  
 방사선학적 소견: 1



**Figure 1.** A chest PA illustrates the fractured catheter tip located between the right first rib and the mid-clavicle. The distal fragment is seen in the right atrium.

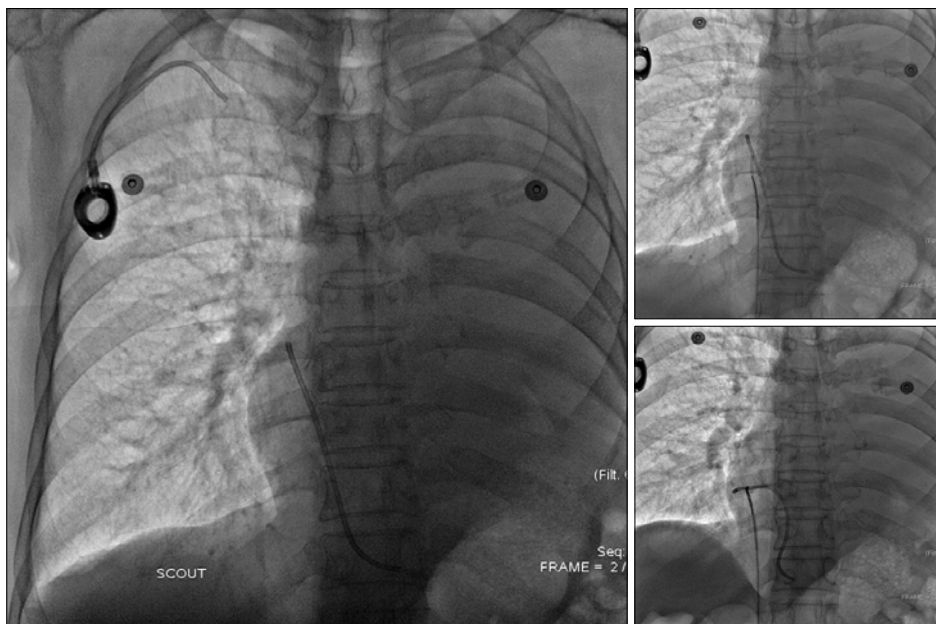
가 ,  
 (Figure 1).  
 임상 경과:  
 , 가  
 (Figure 2),  
 (Figure 3).

## 증례 2

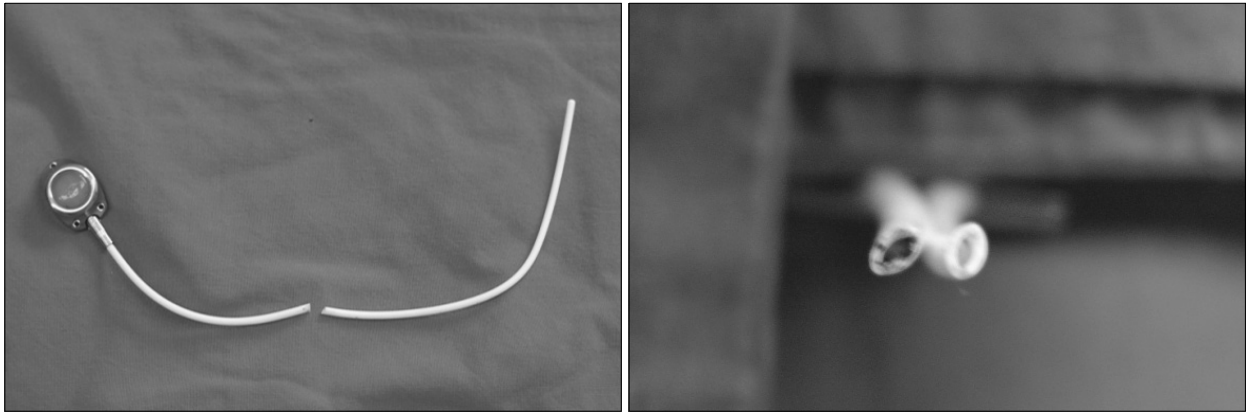
환 자: O O ( , 47 )

주 소: X-

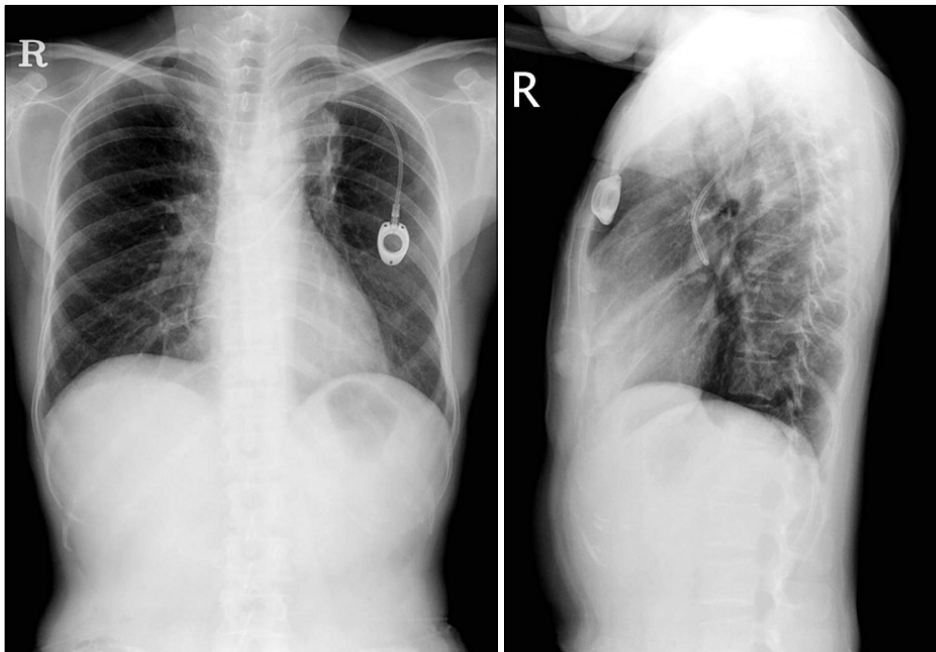
과거력 및 가족력:



**Figure 2.** Inferior Vena Cavography shows a distal fractured fragment in the right atrial area (left). The right femoral vein was punctured and the fractured catheter was removed using a snare wire (right upper and lower).



**Figure 3.** In a cross section, the configuration of the embolized portion of the catheter is not circular, but instead elliptical.



**Figure 4.** A chest PA and lateral films show the fractured chemoport catheter tip located between the left first rib and the mid-portion of the clavicle, and the distal fragment located in the main pulmonary artery.

사회력: . / , 36.8°C . ,  
 현병력: 2005 8 .  
 검사실 소견: 4,700/mm<sup>3</sup>,  
 9.3 g/dl, 29.9%, 305,000/mm<sup>3</sup>  
 etoposide  
 6 2007 4 , ,  
 이학적 소견: 방사선학적 소견: X-  
 110/90 mmHg, 68 / , 24 가 ,

452

가

가

7,10-12

12

가

## 요 약

가 가

## 참 고 문 헌

1. Rauthe G, Altmann C. Complications in connection with venous port systems: prevention and therapy. *Eur J Surg Oncol* 1998;24:192-9.
2. Yildizeli B, Lacin T, Baltacioglu F, Batirel HF, Yuksel M. Approach to fragmented central venous catheters. *Vascular* 2005;13:120-3.
3. Hinke DH, Zandt-Stastny DA, Goodman LR, Quebbeman EJ, Krzywda EA, Andris DA. Pinch off syndrome:

a complication of implantable subclavian venous access devices. *Radiology* 1990;177:353-6.

4. Kim OK, Kim SH, Kim JB, Jeon WS, Jo SH, Lee JH, et al. Transluminal removal of a fractured and embolized indwelling central venous catheter in the pulmonary artery. *Korean J Intern Med* 2006;21:187-90.
5. Coles CE, Whitear WP, Le Vay JH. Spontaneous fracture and embolization of a central venous catheter: prevention and early detection. *Clin Oncol (R Coll Radiol)* 1998;10:412-4.
6. McMenamin EM. Catheter fracture: a complication in venous access devices. *Cancer Nurs* 1993;16:464-7.
7. Andris DA, Krzywda EA, Schulte W, Ausman R, Quebbeman EJ. Pinch-off syndrome: a rare etiology for central venous catheter occlusion. *JPEN J Parenter Enteral Nutr* 1994;18:531-3.
8. Prager D, Hertzberg RW. Spontaneous intravenous catheter fracture and embolization from an implanted venous access port and analysis by scanning electron microscopy. *Cancer* 1987;60:270-3.
9. Lenglinger FX, Hartl P, Kirchgatterer A, Lenglinger GM, Baldinger C. Fracture and embolization of a central venous port catheter without prior compression between the clavicle and the 1st rib. *Wien Klin Wochenschr* 2001;113:134-7.
10. De Graaff JC, Bras LJ, Vos JA. Early transection of a central venous catheter in a sedated ICU patient. *Br J Anaesth* 2006;97:832-4.
11. Mirza B, Vanek VW, Kupensky DT. Pinch off syndrome: case report and collective review of the literature. *Am Surg* 2004;70:635-44.
12. Orsi F, Grasso RF, Arnaldi P, Bonifacio C, Biffi R, Bellomi M, et al. Ultrasound guided versus direct vein puncture in central venous port placement. *J Vasc Access* 2000;1:73-7.