

전방경추융합술 후 발생한 역설상기도폐쇄 및 중추성 수면 무호흡

가톨릭대학교 의과대학 내과학교실, ¹메리놀병원 내과,
이상학, 최영미¹, 박예리, 강지호, 김영균, 김관형, 송정섭, 박성학, 문화식

Paradoxical Upper Airway Obstruction and Central Sleep Apnea Developed After Anterior Cervical Spine Fusion

Sang Haak Lee, M.D., Young Mee Choi, M.D.¹, Ye Ree Park, M.D., Ji Ho Kang, M.D., Young Kyoan Kim, M.D.,
Kwan Hyoung Kim, M.D., Jeong Sup Song, M.D., Sung Hak Park, M.D., Hwa Sik Moon, M.D.

Department of Internal Medicine, The Catholic University of Korea, College of Medicine, Seoul, Korea

¹Department of Internal Medicine, The Maryknoll Hospital, Busan, Korea

We report a case of a 48-year-old man with a paradoxical upper airway obstruction and central sleep apnea that developed after an anterior cervical spinal fusion. Nine months before being admitted to this hospital, he was diagnosed with a herniated intervertebral disc between the 5th and 6th cervical spine, and the first operation was carried out. Two months later, a pseudoarthrosis has developed and a second operation, an anterior interbody fusion of the C5 and C6 using autogenous strut bone graft, was performed. After the second operation, he began to complain of snoring, excessive daytime sleepiness, insomnia, and a bizarre sound heard near the upper airway during breathing. Nasopharyngoscopy and magnetic resonance imaging disclosed a paradoxical narrowing of the nasopharynx during expiration. On the overnight polysomnography, the apnea index was 8.7/h (central apnea, 7.0/h; obstructive apnea, 1.7/h). Nasal continuous positive airway pressure was applied, but he complained of pressure-intolerance, and laser-assisted uvulopalatoplasty was then performed. Two months after surgery, clinical symptoms as well as the apneas had improved markedly. We suggest that this paradoxical upper airway obstruction might be associated with the anterior cervical spinal surgery even though the mechanism is unclear. This case also emphasizes that an upper airway obstruction can contribute to the development of central sleep apnea. (*Tuberc Respir Dis* 2005; 58:294-298)

Key words : Anterior cervical spine surgery, Central sleep apnea, Laser-assisted uvulopalatoplasty, Paradoxical upper airway obstruction

Introduction

Central sleep apnea is much less common than obstructive sleep apnea and it has diverse clinical and pathophysiological manifestations. To this date, few cases have been reported, in which cervical spine surgery resulted in central sleep apnea, in addition, no report is available on central sleep apnea caused by an expiratory upper airway obstruction after anterior cervical spine surgery. This report

details a case of some rarity involving a patient, who had experienced paradoxical upper airway obstruction and central sleep apnea, and was treated by laser-assisted uvulopalatoplasty.

Case Report

A 48-year-old male (height 164.5 cm, weight 78kg, body mass index 28.8 kg/m²) was transferred to our Sleep Disorders Clinic, because of suspected sleep apnea syndrome. Before he came to our hospital, he had undergone two prior operations. Nine months before transfer, he had received an anterior discectomy and interbody fusion using an Orion plate, because of herniated intervertebral disc between the 5th and 6th cervical spine (C5 & C6). However, seven months after the first surgery, the pains re-

Address for correspondence : **Hwa Sik Moon, M.D.**
Division of Pulmonology, Department of Internal
Medicine, St. Paul's Hospital, The Catholic
University of Korea, 620-56, Jeonnon-gong-dong,
Dongdaemoon-gu, Seoul, 130-709, Republic of Korea
Phone : +82-2-958-2463 Fax : +82-2-968-7250
E-mail : hsmoon@catholic.ac.kr
Received : Jan. 17. 2005
Accepted : Mar. 8. 2005

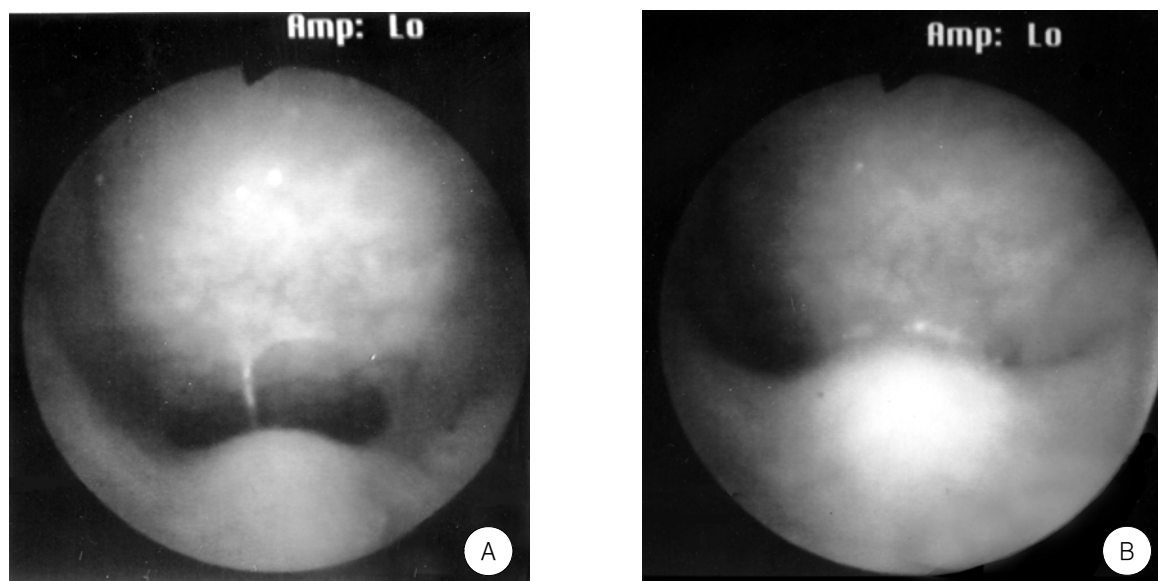


Figure 1. Flexible fiberoptic nasopharyngoscope. A: Patent nasopharyngeal lumen during the inspiratory phase of breathing. B: Note the uvula touching the posterior nasopharyngeal wall during the expiratory phase.

curred and the ensuing diagnosis revealed pseudoarthrosis of C5 and C6. Accordingly, an anterior interbody fusion of C5 and C6 was performed using an autogenous strut bone graft. After the second operation, however, the patient began to complain of snoring, excessive daytime sleepiness, insomnia, and a bizarre sound from the upper airway when breathing, none of which had existed in the preoperative state. He had never taken any drugs which might influence on sleep.

On physical examination, a noise sounding rather like a *krrrrr* was detected during expiration. His lungs and heart were normal. Radiographs of the chest and paranasal sinuses showed no evidence of abnormality and a pulmonary function test showed minimal obstructive ventilatory dysfunction, but interestingly, flexible fiberoptic nasopharyngoscopy (Fig. 1) and magnetic resonance imaging of head and neck (Fig 2), found that the uvula reached the posterior nasopharyngeal wall during the expiratory phase of breathing, which suggested a possible case of the paradoxical upper airway obstruction. Overnight sleep studies were also performed using stand-

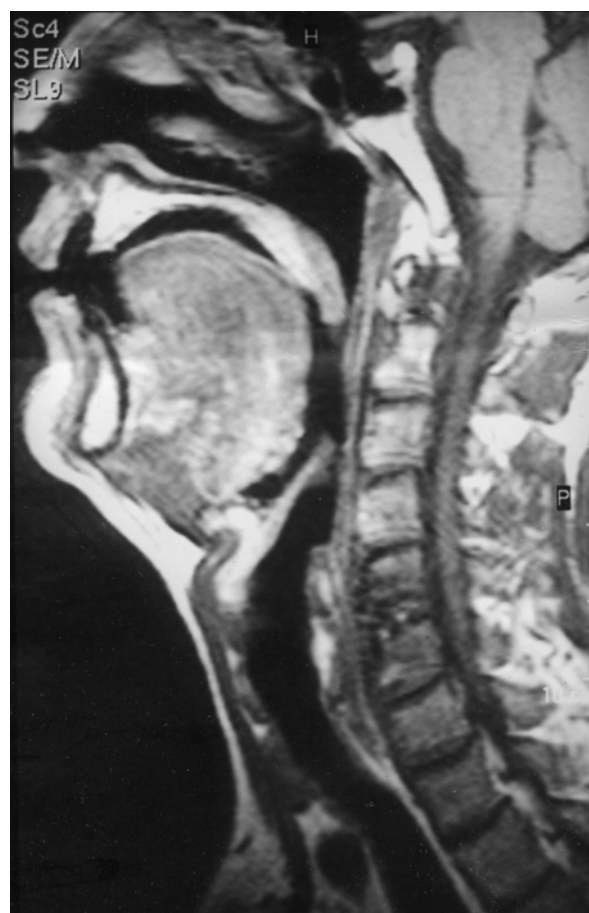


Figure 2. MRI of the head and neck showing that the uvula contacted the posterior nasopharyngeal wall during the expiratory phase of breathing.

and polysomnographic techniques using an Alice 3 polysomnograph (Healthdyne Technologies; Atlanta; GA). Polysomnography data revealed that the patient had an apnea index (AI) of 8.7/h (with central apnea 7.0/h and obstructive apnea 1.7/h), an apnea-hypopnea index (AHI) of 11.7/h, and 82.1% sleep efficiency.

Based on these results, we decided to apply nasal continuous positive airway pressure (CPAP; Healthdyne Technologies; Atlanta; GA) as a therapeutic choice. After a CPAP of 5 cmH₂O had been conducted, an overnight sleep study showed a decline in the AI to 1.3/h; yet sleep efficiency was a mere 37.2% and the patient complained of pressure-intolerance during the treatment. Consequently, as an alternative method, laser-assisted uvulopalatoplasty (LAUP) was performed, which brought about significant improvements in the patient's condition. Two months after the surgery, his symptoms of sleep apnea had disappeared and he no longer heard the strange noise during the expiratory phase. On a follow-up overnight sleep study, no trace of apnea was observed; his AHI had substantially reduced to 0.4/h and sleep efficiency improved to 87.3%.

Discussion

The anterior technique is a widely applied method for removing cervical disk in the treatment of symptomatic herniated disks. Nevertheless, due to the complexities of the anatomic structure surrounding the anterior neck and enormous anatomic variability, the approach requires an accurate knowledge of the anatomy, not to mention meticulous surgical skill. In addition, there have been some reports on obstruction of the upper airway following the anterior procedure on the cervical spine^{1,2} which, in the majority of such cases, calls for immediate reintubation. Soft tissue swelling was determined to have been the leading cause of upper airway obstruction. In the

case of our patient, the uniqueness of the case lies in the fact that the upper airway obstruction that developed after anterior cervical spine surgery was prominently observed during expiration whereas physiological narrowing normally occurs during inspiration, and that he was found to have neither swallowing difficulties nor any evidence signaling nerve injury. The most likely hypothesis is that even a minimal nerve injury involving a localized portion of pharyngeal plexus during surgery may contribute to the occurrence of upper airway obstruction as was observed in our patient. However, the mechanisms underlying the association of paradoxical upper airway obstruction and anterior cervical spine surgery remain to be established.

Another interesting aspect of the present case is the development of central sleep apnea. In previously reported cases³⁻⁵, apneas developed immediately after spinal surgery and required urgent reintubation and positive pressure ventilations. In addition, spinal cord damage was presumed to have been the cause of such complications, and in these cases symptoms of apnea disappeared within several hours or weeks. However, the clinical features of the present case were quite different. The patient had evident symptoms of sleep apnea as was experiencing excessive daytime sleepiness, but they were not serious enough to warrant intubation. When we used the CPAP treatment on this patient, assuming an association between central sleep apnea and upper airway obstruction, the sleep apnea was controlled. However, since the patient could not tolerate the positive airway pressure, we decided to performed LAUP to remove the focus of the upper airway obstruction. This surgical intervention then was able to successfully remove the symptoms of central sleep apnea and prevented the paradoxical blockage in the upper airway that had been manifested by the strange noise during expiration. This suggests that, although

the mechanism of central sleep apnea is complex, abnormal upper airway obstruction may be one of the contributors to the pathogenesis of central sleep apnea, and that this can be reversed by removing the upper airway obstruction.

국 문 초 록

전방경추융합술을 시행한 후 역설상기도폐쇄와 중추성 무호흡이 발생하였던 증례를 경험하여 이를 보고하고자 한다. 환자는 48세 남자로 본원으로 전원되기 9개월 전에 5번과 6번 경추사이의 추간판탈출증으로 수술을 시행받았으며, 내원 2개월 전에는 가성관절증이 발생하여 자가골이식과 함께 전방접근법으로 5번과 6번 경추의 경추융합술을 시행받았다. 이 수술을 시행 후 환자는 코골이와 과도한 주간 졸음증, 불면증 등의 증세가 생겼으며 호흡시에 상기도부위에서 이상한 소리가 발생하였다. 코인두경 및 자기공명영상으로 호기시 코인두부위의 역설적 협착소견을 관찰할 수 있었고, 철야 수면다원검사에서 무호흡지수는 8.7/시간 (중추성 무호흡, 7.0/시간; 폐쇄성 무호흡, 1.7/시간)이었다. 경비적 지속성 기도양압치료를 시작하였

으나 환자가 압력을 못견뎌하여 레이저목젖입천장성형술을 시행하였다. 수술 2개월 경과 후 무호흡과 더불어 임상증세는 현격히 호전되었다. 저자들은 이러한 역설상기도폐쇄가 비록 그 기전이 명확하지는 않지만 전방경추융합술과 관련되어 있다고 추정한다. 또한 이러한 상기도 폐쇄가 중추성 수면 무호흡을 유발할 수 있다는 것을 보여주는 증례라고 생각한다.

References

1. Fujiwara H, Nakayama H, Takahashi H, Shimizu M, Hanaoka K. Postoperative respiratory disturbance after anterior cervical fusion. *Masui* 1998;47:475-8.
2. Francois JM, Castagnera L, Carrat X, Simeon F, Guatterie M, Devars F, et al. A prospective study of ENT complication following surgery of the cervical spine by the anterior approach (preliminary results). *Rev Laryngol Otol Rhinol (Bord)* 1998;119:95-100.
3. Naim-Ur-Rahman. Post-operative central sleep apnoea complicating cervical laminectomy: case report. *Br J Neurosurg* 1994;8:621-5.
4. Fielding JW, Tuul A, Hawkins RJ. "Ondine's curse". A complication of upper cervical-spine surgery. *J Bone Joint Surg Am* 1975;57:1000-1.
5. Vella LM, Hewitt PB, Jones RM, Adams AP. Sleep apnoea following cervical cord surgery. *Anaesthesia* 1984;39:108-12.