

Torsion of an Indirect Hernia Sac Causing Acute Scrotal Swelling in a Child

Jong Kil Nam, Jae Hyun Ahn, Hyeon Woo Kim, Hyun Jun Park, Sang Don Lee, Moon Kee Chung

Department of Urology, Research Institute for Convergence of Biomedical Science and Technology, Pusan National University School of Medicine, Yangsan, Korea

Torsion of a hernia sac is an extremely rare condition that presents as acute scrotum in children. We report a case of a 6-year-old boy who presented with an acute scrotum and was found during surgical exploration to have torsion of an indirect hernia sac associated with hydrocele. Upon scrotal exploration, deterioration of the scrotum due to inflammatory changes was found. A necrotic cyst was recognized within a communicating hydrocele of the scrotum and was twisted at an angle of about 360°. All urologists should be aware of this special condition in the differential diagnosis of acute scrotum.

Key Words: Scrotum; Hernia, inguinal; Torsion abnormality

Acute scrotal swelling and pain in children is a common entity that requires prompt, accurate evaluation and appropriate therapy. The etiologies of these symptoms can range from benign self-limited conditions to more serious organ threatening problems like testicular torsion.¹ A Doppler ultrasound of the testis may be helpful to confirm diagnosis of the acute scrotum. Occasionally, the entity responsible for the acute scrotum cannot be ascertained preoperatively. In such a case, surgical exploration should be performed immediately.

We herein report our case of torsion of an indirect hernia sac misdiagnosed as testicular torsion. This is an extremely rare cause of acute scrotum in children, with this case representing only the ninth case reported in the

English language literature.²⁻⁷

CASE REPORT

A 6-year-old boy presented to the emergency room with acute pain and scrotal swelling in the right hemiscrotum for the past two days. Physical examination elicited mild fever, and the patient was in severe distress. The left testicle felt normal on palpation. The right hemiscrotum was tense and edematous. The right testicle could not be easily palpated. The cremasteric reflex was present bilaterally. Urine analysis, complete blood count, and routine blood chemistry results were unremarkable. A Doppler ultrasound of the testis demonstrated a multiseptated peritesticular cystic mass

Received: Jun 7, 2012; Revised: Jun 27, 2012; Accepted: Jul 4, 2012

Correspondence to: Jong Kil Nam

Department of Urology, Pusan National University Yangsan Hospital, Pusan National University School of Medicine, 20, Geumo-ro, Mulgeum-eup, Yangsan 626-770, Korea.

Tel: +82-55-360-2134, Fax: +82-55-360-2931, E-mail: tuff-kil@hanmail.net

Copyright © 2012 Korean Society for Sexual Medicine and Andrology

This is an Open Access article distributed under the terms of the Creative Commons Attribution Non-Commercial License (<http://creativecommons.org/licenses/by-nc/3.0>) which permits unrestricted non-commercial use, distribution, and reproduction in any medium, provided the original work is properly cited.

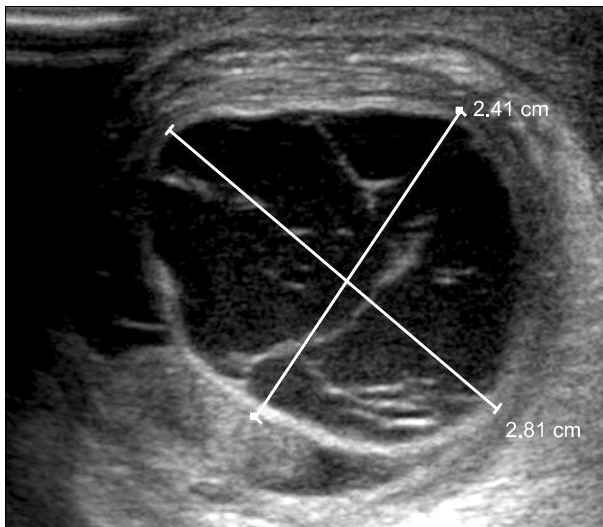


Fig. 1. Ultrasonography revealed a normal right testis with septated paratesticular cystic mass.

with hydrocele in the right side measuring 2.8 cm×2.4 cm×3.0 cm in size (Fig. 1). A scrotal exploration was performed and during surgery, a tense, dark purple, and cystic sac was evident superior to the right testis (Fig. 2). The necrotic cyst consisted of torsion of a hernia sac that communicated directly with the peritoneum, was twisted in an angle of about 360°, and contained no bowel or omentum (Fig. 2). Through a second incision in the inguinal region, the hernia sac was dissected free from the cord, ligated, and excised at the level of the internal ring. The scrotal and inguinal incisions were closed. The pathologic diagnosis was a hernia sac of the peritoneum accompanied by bleeding, congestion, necrosis, and fibrosis. The patient was discharged the following day, and the postoperative course was uneventful.

DISCUSSION

A case of a child with acute scrotal pain, tenderness, or swelling should be viewed as an emergency situation requiring prompt evaluation, differential diagnosis, and frequently requiring exploratory surgery despite sonographic imaging findings. In all cases, it is imperative to rule out testicular torsion. The etiology of acute scrotum has been reported to involve torsion of an appendage in 70% of cases, testicular torsion in 12%, and epididymo-orchitis in 11%.¹ Children with torsion of an appendage

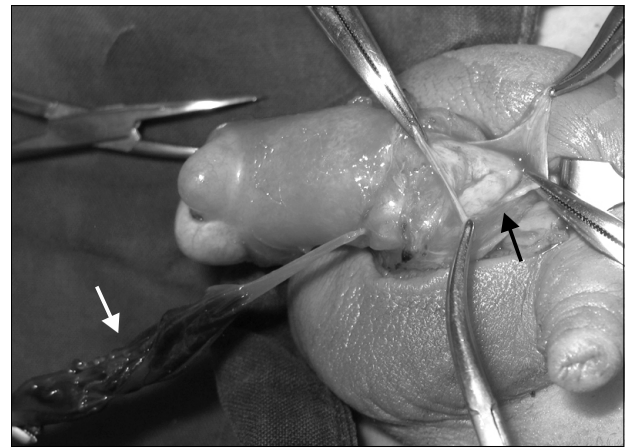


Fig. 2. The hernia sac filled with hemorrhagic fluid (white arrow) was separated from right testis. A hernia sac communicated directly with the peritoneum (black arrow) and was twisted an angle of about 360° and contained no internal contents.

have milder pain of longer duration at presentation. Often the torsion of an appendage can be felt as a tender hard nodule at the upper pole of the testis. For this reason, torsion of an appendage and epididymitis might be difficult to distinguish clinically. Symptoms suggesting a testicular torsion typically present with severe sudden onset of pain and swelling.³ A radionuclide testicular scan or a Doppler ultrasound of the testis may be helpful to confirm diagnosis of the acute scrotum.⁸ Despite improved ultrasound technology, however, surgical exploration may have to be considered to make an accurate diagnosis. When the diagnoses of benign self-limited conditions are confirmed clinically or by imaging, conservative management allows most cases to resolve spontaneously. Occasionally, acute exploration is performed due to suspicion of testicular torsion, or delayed exploration is performed due to failure of spontaneous resolution of the inflammatory changes and discomfort. If it is likely to be testicular torsion, immediate surgical exploration should be done.

Torsion of an inguinal hernia sac is extremely rare in children, with this case representing only the ninth instance reported in the literature.²⁻⁷ Of those cases, the mean age was 5.7 ± 3.2 years (range, 2~10 years) and the right: left ratio of the region was 7 : 2. All of the children presented with an acutely swollen hemiscrotum and underwent exploratory surgery because of indeterminate and uncertain sonographic findings suggesting complex

cystic peritesticular masses. Scrotal exploration was then undertaken with the finding of a twisted indirect hernia sac. In our case, hemiscrotal pain and swelling of the right side presented and was associated with hydrocele. Torsion of a hernia sac is indeed a rare entity, and its true incidence is unknown respective of etiology.⁵ The differential diagnosis includes scrotal lymphangioma,⁹ cystic teratoma, and infected hydrocele, which have very similar sonographic findings. Although advances in sonographic imaging have greatly narrowed our differential diagnosis of the acutely swollen scrotum, imaging fails to clearly diagnose this unusual phenomenon. Though rare, torsion of an indirect hernia sac is a possible cause of acute scrotal pain and swelling in children that cannot be reliably diagnosed by ultrasound but can be cured by surgical intervention. All urologists should be aware of this entity and include it in the differential diagnosis in cases of boys who present with acute scrotum.

ACKNOWLEDGEMENTS

This study was supported by the Research Institute for Convergence of Biomedical Science and Technology, Pusan National University Yangsan Hospital.

REFERENCES

1. McAndrew HF, Pemberton R, Kikiros CS, Gollow I. The incidence and investigation of acute scrotal problems in children. *Pediatr Surg Int* 2002;18:435-7
2. Esho JO, Vitko RJ, Cass A. Protrusion and torsion of an inguinal hernia sac inside a hydrocele of the scrotum. *J Pediatr Surg* 1974;9:423
3. Motta J, Bagli DJ, Savage JV, Khoury AE, McLorie G, Salle JP. Torsion of an indirect hernia sac: an unusual cause of acute scrotal swelling in children. *Urology* 1997;50:432-5
4. Perez LM, Manibo JF, Netto JM, Joseph DB. Torsion of an indirect inguinal hernia sac within a long-standing ipsilateral hydrocele in an 8-year-old boy. *BJU Int* 1999;84:731-2
5. Myers JB, Lovell MA, Lee RS, Furness PD 3rd, Koyle M. Torsion of an indirect hernia sac causing acute scrotum. *J Pediatr Surg* 2004;39:122-3
6. Matsumoto A, Nagatomi Y, Sakai M, Oshi M. Torsion of the hernia sac within a hydrocele of the scrotum in a child. *Int J Urol* 2004;11:789-91
7. Tillett JW, Elmore J, Smith EA. Torsion of an indirect hernia sac within a hydrocele causing acute scrotum: case report and review of the literature. *Pediatr Surg Int* 2006;22:1025-7
8. Pavlica P, Barozzi L. Imaging of the acute scrotum. *Eur Radiol* 2001;11:220-8
9. Hamada Y, Yagi K, Tanano A, Kato Y, Takada K, Sato M, et al. Cystic lymphangioma of the scrotum. *Pediatr Surg Int* 1998;13:42-4