

Necrosis of intact premolar caused by an adjacent apical infection: a case report

Saeed Asgary^{1*},
Laleh Alim Marvasti²

¹Iranian Center for Endodontic Research, Research Institute of Dental Sciences, Shahid Beheshti University of Medical Sciences, Tehran, Iran

²Dental Research Center, Research Institute of Dental Sciences, Shahid Beheshti University of Medical Sciences, Tehran, Iran

Although periapical inflammatory lesions are usually resulted by infection in the root canal system, this rare case showed that a periapical lesion related to an infected tooth may cause pulpal necrosis in adjacent intact tooth, with no history or clinical signs of caries, disease, trauma or developmental anomaly. This case also suggests that the periapical lesion can be treated conservatively, without surgical intervention. Furthermore, this case highlights the importance of prompt treatment of apical periodontitis before the lesion becomes extensive as well as follows up of large lesions. (*Restor Dent Endod* 2013;38(2):90-92)

Key words: Apical Periodontitis; Dental Pulp Necrosis; Endodontic

Received February 7, 2013;
Revised March 6, 2013;
Accepted April 6, 2013.

¹Asgary S, Iranian Center for Endodontic Research, Research Institute of Dental Sciences, Shahid Beheshti University of Medical Sciences, Tehran, Iran

²Alim Marvasti L, Dental Research Center, Research Institute of Dental Sciences, Shahid Beheshti University of Medical Sciences, Tehran, Iran

*Correspondence to

Prof. Saeed Asgary, DDS, MS.
Professor, Iranian Center for Endodontic Research, Shahid Beheshti University of Medical Sciences, Velenjak Str., Shahid Chamran Highway, Tehran, Iran
TEL, +98-21-22-41-38-97; FAX, +98-21-22-42-77-53; E-mail, saasgary@yahoo.com

Introduction

Apical periodontitis (AP) that persists after root canal therapy (RCT) presents a more complex etiological and therapeutic situation than AP affecting teeth that have not undergone RCT.¹ Microbiological contamination of root canal system is an important etiological factor of AP; therefore treatment protocol consists of either eliminating or considerably reducing bacteria and their byproducts and preventing reinfection by 3-dimensional root canal obturation.^{2,3} If RCT is performed correctly, healing of the periapical lesion gradually occurs with bone infill and therefore reduction of the size of radiolucency on review radiographs. However, the lesion may persist when RCT is inadequate. Such cases are referred to as endodontic failures.

AP persists when RCTs have not reached an acceptable standard for the removal of infection. Inadequate aseptic control, poor access cavity design, missed canals, insufficient instrumentation and obturation, and leaking temporary or permanent restorations are common reasons that have been documented past and present to cause persistent AP.^{1,4} Residual bacteria in the apical portion of the root canals are the main reason of AP persisting postoperatively both in poorly and properly endodontically treated cases.

Bacteria/bacterial products are the main culprits of pulpal diseases though other factors like iatrogenic trauma can also cause inflammation/infection in the pulp. Exposure of dentine/cementum, severe tooth surface loss, local malignant neoplasms, aggressive cysts/benign tumors as well as systemic factors i.e. hereditary hypophosphatemia may also cause necrosis.⁵ Historically it was reported that long-acting occlusal trauma could lead to pulp damage due to compression of the pulp vasculature.⁶ However, there have been few reports described a periapical lesion related to infected tooth may cause pulpal necrosis in an intact adjacent tooth.^{7,8}

It is well known that pulpal death of intact teeth seldom occurs without history or evidence of trauma, caries, physical/chemical irritants, and/or local and systemic diseases. Therefore, this article aimed to report this perplexing case of pulpal necrosis of intact second lower premolar adjacent to a large periradicular lesion of adjacent failed endodontically treated first molar.

Case report

A 38-year-old Caucasian male patient presented to our dental office with a 1 year history of recurrent swelling on the buccal aspect of lower right mandibular region. He reported pain/tenderness on chewing over the past year. Medical history was unremarkable and there was no contraindication to dental treatment. There was no history of trauma to the teeth and jaw; a previous dental root treatment in the lower right region was reported.

Clinical examination revealed that the first right lower molar was tender to percussion and had a large coronal restoration; the adjacent premolar and molar teeth were vital and intact with no signs of caries or anomalies such as occlusal tubercle. The buccal soft tissue of lower molar teeth was normal. The probing depths were within normal limits. The molar tooth had no mobility. Radiographic examination showed a large circumscribed radiolucency at the apex the mesial root of first mandibular molar (Figure 1a). However, lamina dura surrounding the root of second

premolar was apparent circumferentially. Further history revealed that the molar tooth had been endodontically treated 5 years ago and restored with an amalgam restoration. The obturation was deemed inadequate and a diagnosis of persistent AP due to inadequate root canal filling of lower right first molar was ascertained. After full explanation the patient consented to nonsurgical endodontic retreatment, followed by coronal restoration with amalgam.

First, patient was asked to rinse with 0.2% chlorhexidine mouthwash. After administering local anesthesia, and isolation with rubber dam, the amalgam restoration was removed using a water-cooled high-speed fissure bur and straight line access to the root canals was made. Working length was determined radiographically, confirmed by electronic apex locator and using hybrid instrumentation (mixed technique) the canals were shaped and cleaned; copious irrigation with 5.25% NaOCl solution was carried out. Canals were dried and obturated by lateral condensation technique with gutta-percha and endodontic sealer (Roth's Grossman Type 801, Roth International LTD., Chicago, IL, USA). Post-treatment occlusal reduction and adjustment did not carry out and access cavity was temporized with Cavit (Figure 1b). Next day the patient suffered from severe pain/swelling and analgesics/antibiotics were prescribed. The patient was asymptomatic after one week and the tooth was permanently restored with amalgam.

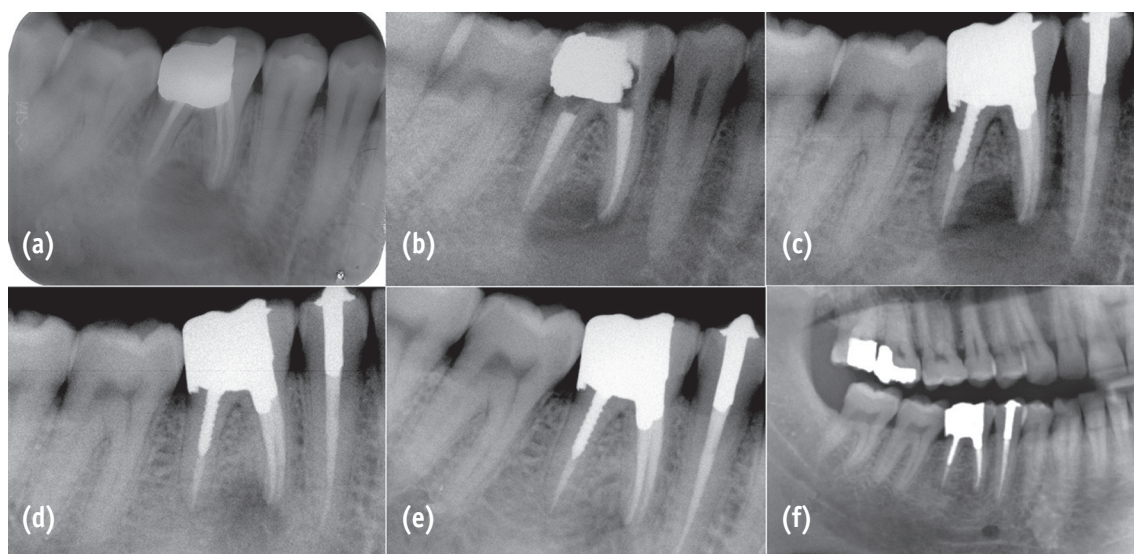


Figure 1. (a) Preoperative radiograph showing a large periapical lesion with loss of lamina dura surrounding the mesial root of lower first molar; (b) Nonsurgical endodontic retreatment was carried out for involved molar but sign/symptoms did not resolve; (c) Pulp Vitality test revealed that the intact adjacent premolar was nonvital and nonsurgical endodontic treatment was carried out; (d, e) Six- and 12-month follow-up radiographs showing gradual bone healing; (f) Two-year follow-up radiograph reveals complete bone healing.

The patient returned 6 weeks later complaining of episodes of pain and local buccal abscess particularly in the last three weeks. Clinical examination revealed that the buccal soft tissue of mandibular right region was inflamed/swelled and tender to palpation. After investigation with thermal and electrical tests, the pulp of lower right second premolar was deemed nonvital. A test cavity in the absence of local anesthesia confirmed dental pulp death. One-visit nonsurgical endodontic treatment was carried out similar to the previous case (Figure 1c). Antibiotics were not prescribed. At the 7-day follow-up, signs and symptoms completely resolved.

Radiographic examination at the 6-month recall demonstrated gradual reduction of the periradicular radiolucency (Figure 1d). At the 12-month recall examination, the tooth was asymptomatic, and the region of periapical radiolucency was remarkably reduced (Figure 1e). Two-year follow-up revealed healthy periodontal tissue with normal probing depths, no signs or symptoms of inflammation and infection. Radiographically, the periapical lesion was completely healed (Figure 1f), signifying endodontic treatment success.

Discussion

This report presents a case of persistent AP in which nonsurgical endodontic retreatment of an involved molar had failed to resolve symptoms and signs. Conventional RCT of an intact but nonvital premolar achieved clinical and radiographic success. Dental caries (bacteria and their byproducts) is the most common cause of dental pulp devitalization; however, other factors such as trauma, physical and chemical irritants, or systemic diseases may play a role on the occurrence of pulpal necrosis. In addition, trauma from aberrant occlusion has been indicted as a cause of pulp degeneration,⁶ but such findings was not demonstrated in this case, i.e. post-treatment occlusal reduction did not carry out. The etiology of the adjacent premolar pulp necrosis can be due to several reasons. It is likely that the pulp necrosis was caused by an adjacent large periradicular lesion. There are scarce reports of this rare finding; however, they have often been surgically treated.^{7,8}

Whether endodontic lesions are infected or not is still controversial. Many previous studies conducted decades ago have demonstrated the presence of live bacteria beyond the apices of endodontically treated teeth.⁹ Researchers suggested that whilst bacterial infection may not be present in all periapical lesions, it is more likely that it will be present in symptomatic apical lesions or in cases of

persistent AP. We can postulate that either the root canal of the premolar was non-vitalized by the inflammatory mediators, bacterial byproducts and/or bacteria in the lesion, perhaps through the main apex or apical and lateral deltas.

Conclusions

It should be born in mind that more than one tooth can be involved with large apical lesions and that straightforward etiology may be elusive. Moreover, from this study we can see that follow-up appointments after root canal treatment are essential. This case demonstrates that cases with well defined radiolucencies can be conservatively treated without endodontic surgery.

Conflict of Interest: No potential conflict of interest relevant to this article was reported.

References

1. Nair PN. On the causes of persistent apical periodontitis: a review. *Int Endod J* 2006;39:249-281.
2. Kakehashi S, Stanley HR, Fitzgerald RJ. The effects of surgical exposures of dental pulps in germ free and conventional laboratory rats. *Oral Surg Oral Med Oral Pathol* 1965;20:340-349.
3. Carrotte P. Endodontics: Part 1. The modern concept of root canal treatment. *Br Dent J* 2004;197:181-183.
4. Sundqvist G, Figdor D. Endodontic treatment of apical periodontitis. In: Ørstavik D, Pitt Ford TR, eds. *Essential Endodontology*. London: Blackwell; 1998. p242-277.
5. Holland GR, Davis SB. Pulpal Pathosis. In: *Ingle's Endodontics*, 6th ed. Ontario: BC Decker Inc.; 2008. p468-493.
6. Johansen JR, Karlsen K. The effect of denervation on trauma from occlusion. *J Oral Rehabil* 1979;6:27-34.
7. Komabayashi T, Jiang J, Zhu Q. Apical infection spreading to adjacent teeth: a case report. *Oral Surg Oral Med Oral Pathol Oral Radiol Endod* 2011;111:e15-e20.
8. Chaniotis AM, Tzanetakis GN, Kontakiotis EG, Tosios KI. Combined endodontic and surgical management of a mandibular lateral incisor with a rare type of dens invaginatus. *J Endod* 2008;34:1255-1260.
9. Iwu C, MacFarlane TW, MacKenzie D, Stenhouse D. The microbiology of periapical granulomas. *Oral Surg Oral Med Oral Pathol* 1990;69:502-505.