

# 불완전 가와사키병 급성기에 면역글로불린 치료에 반응하지 않는 유증상 심근염

손 영 수 · 김 여 향

경북대학교 의과대학 소아과학교실

## Intravenous Immunoglobulin Nonresponsive Symptomatic Myocarditis during the Acute Stage of Incomplete Kawasaki Disease

Youngsoo Sohn, Yeo Hyang Kim

Department of Pediatrics, Kyungpook National University School of Medicine, Daegu, Korea

We report the case of a 7-year-old boy who showed treatment-nonresponsive hypotension (59/29 mmHg) and decreased left ventricular systolic function (fractional shortening 22%) in the acute stage of Kawasaki disease (KD). The present case serves to highlight that methylprednisolone pulse therapy should be considered in patients with intravenous immunoglobulin nonresponsive symptomatic myocarditis during the acute stage of KD.

**Key Words:** Kawasaki disease, Corticosteroids, Myocarditis

### Introduction

The cause of Kawasaki disease (KD) is unknown. However, it is suspected that a child with inherent genetic factors infected with any agent contracts KD by hypersensitivity or abnormal immune reaction<sup>1)</sup>. Patients with KD sometimes have cardiac complications such as coronary arteritis, myocarditis, pericardial effusion, arrhythmias, and valvular regurgitation<sup>2)</sup>. Although myo-

carditis with KD is usually asymptomatic, symptomatic myocarditis may occur<sup>2)</sup>. We report our experience of managing treatment-nonresponsive symptomatic myocarditis with hypotension in a patient with KD.

### Case report

A 7-year-old boy (height, 115 cm; body weight, 20 kg) was admitted because of 3 days of persistent fever, right cervical lymphadenopathy, decreased activity, and abdominal pain. He was brought to a primary physician and was given antibiotics. Despite the antibiotic medication, the fever and lymph node swelling persisted. He had no specific medical history and had been usually well.

On the day of admission, his heart rate (HR) was 127

**Received:** 30 July 2015

**Revised:** 10 September 2015

**Accepted:** 10 September 2015

**Correspondence:** Yeo Hyang Kim

Department of Pediatrics, Kyungpook National University School of Medicine, Daegu, Korea

Tel: +82-53-200-5720, Fax: +82-53-425-6683

E-mail: kimyumd@knu.ac.kr

beats per minute, and blood pressure (BP) was 106/58 mmHg. The results of laboratory tests were as follows: white blood cell (WBC), 17,870/ $\mu$ L (95% polymorphs and 2% lymphocytes); erythrocyte sedimentation rate (ESR), 50 mm/h; C-reactive protein (CRP, normal range <0.5 mg/dL), 23.6 mg/dL (Fig. 1); aspartate aminotransferase (AST), 87 IU/L; alanine aminotransferase (ALT), 37 IU/L. Bacterial infection-induced cervical lymphadenitis was suspected, and intravenous antibiotic therapy (cefazolin 100 mg/kg/24hr) was started.

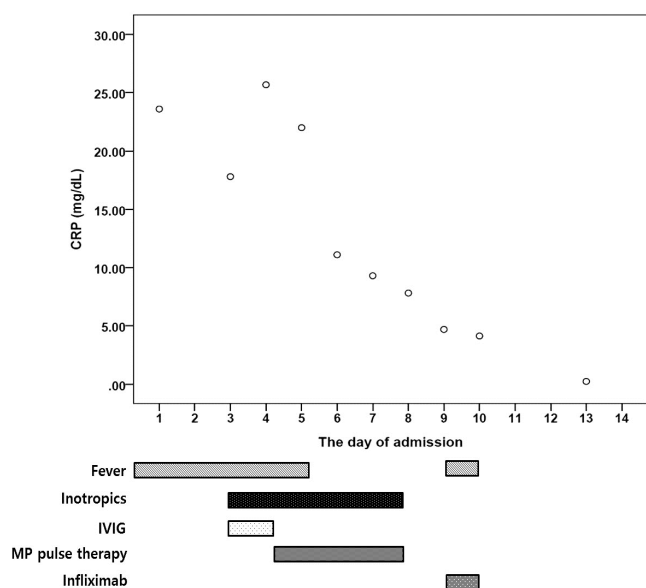
On the third day of admission, his fever persisted, and bilateral conjunctival congestion and lip redness developed. In addition, hypotension and tachycardia developed (BP 59/29 mmHg and HR 153/min), and inotropic medication was started. The brain natriuretic protein (BNP, normal range <250 pg/mL) level was 27,955 pg/mL. Echocardiography was performed, and fractional shortening (FS) and ejection fraction (EF) were decreased to 23% and 47%, respectively (Fig. 2). However, the left ventricular dimension was normal (left ventricle internal diameter in diastole Z score=0.27 and in systole Z score=0.91). The sizes of both coronary arteries were normal (left main 2.43 mm, Z score=0.0; right, 2.49 mm, Z score=1.5). Although he had only four features of KD, he was diagnosed with incomplete

KD, and treatment with intravenous immunoglobulin (IVIG, 2 g/kg for 12 hr) and oral aspirin (100 mg/[kg · day]) were started. The BP was 73/37 mmHg with continuous inotropic medication (dopamine 20  $\mu$ g/[kg · min], dobutamine 20  $\mu$ g/[kg · min], and epinephrine 1  $\mu$ g/[kg · min]).

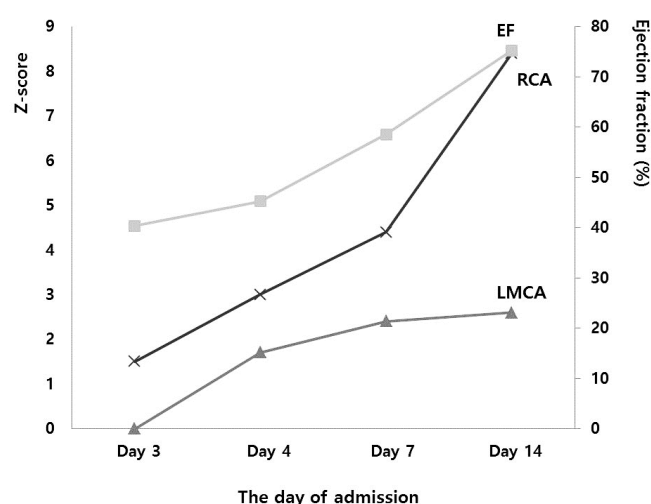
On the fourth day of admission, fever (38.4°C), hypotension, and decreased left ventricular systolic function (FS 22% and EF 45%) persisted despite IVIG and inotropic treatments. We decided to give him methylprednisolone pulse therapy (30 mg/[kg · day]) for 3 days.

On the 5th day of admission, after second dose of methylprednisolone pulse therapy, his BP elevated (98/71 mmHg) and HR decreased (112 beats per minute). On the 7th day of admission, all inotropic medications were discontinued. He was afebrile, and his condition was good. After pulse therapy, two-dimensional echocardiography (the 7th day of admission) showed normal left ventricular systolic function by using the M mode (FS 31% and EF 59%), but coronary arterial dilatation progressed (left main 3.4 mm, Z score=2.4; left anterior descending 2.6 mm, Z score=1.9; left circumflex 2.0 mm, Z score=0.1; right proximal 2.8 mm, Z score=1.5; right middle 3.7 mm, Z score=4.4).

On the 9th day of admission, fever redeveloped



**Fig. 1. Clinical course of the patient.** CRP, C-reactive protein; IVIG, intravenous immunoglobulin; MP, methylprednisolone.



**Fig. 2. Change of ejection fraction (%), Z score of maximum diameter of right coronary artery (x), and Z score of diameter of left main coronary artery (▲) according to the day of admission.**

(38.2°C), and he complained of joint pain in the right ankle. Although his condition was improved and his CRP level was decreased (Fig. 1), he received infliximab therapy because of fever and general weakness including arthralgia. Re-developed fever went down on the next day of infliximab therapy and arthralgia persisted during 3 days. On the 14th day of admission, he received warfarin and aspirin medications, and was discharged. Two-dimensional echocardiography at the time of discharge showed normal left ventricular systolic function by using the M mode (FS 43% and EF 75%), and dilated coronary arteries (left main 3.5 mm, Z score=2.6; left anterior descending 3.3 mm, Z score=3.8; left circumflex 2.4 mm, Z score=1.4; right proximal 3.8 mm, Z score=3.9; right middle 5.4 mm, Z score=8.4).

After 2 months, on follow-up echocardiography, dilatation of the left main coronary artery was improved (2.1 mm, Z score=-0.8). However, aneurysm formation in the right coronary artery persisted (proximal 3.7 mm, Z score=3.7; middle 5.5 mm, Z score=8.6).

## Discussion

The affected age of KD ranges from 6 months to 5 years. In South Korea, the mean annual incidence of age younger than 5 years was 134.4 per 100,000 and that of age older than 5 years was about 16.8 per 100,000<sup>3)</sup>. The prognosis of KD was worse in those older than 5 years than in those younger than 5 years<sup>4)</sup>.

Of the cardiac complications of KD, myocarditis is the most common, with a prevalence of at least 50% of patients with KD, and it is usually subclinical and asymptomatic<sup>2)</sup>. In comparison, symptomatic myocarditis with congestive heart failure and inotropic treatment has been reported<sup>5-7)</sup>. It is known that IVIG treatment reduced the prevalence of coronary disease and improved myocardial function in patients with KD to accompany myocarditis with clinical or subclinical left ventricular dysfunction<sup>6,7)</sup>. Although IVIG therapy improved myocardial function, it may sometimes induce hypotension<sup>8)</sup>.

In comparison with the previous reports<sup>6,7)</sup>, our case had symptomatic myocarditis with inotropic and IVIG nonresponsive hypotension. Because these were not responsive to fluid, inotropic, and IVIG therapy, the patient received methylprednisolone pulse therapy. Methylprednisolone pulse therapy is an alternative treatment of refractory KD, and case reports indicated that methylprednisolone pulse therapy was effective for KD with symptomatic myocarditis<sup>5,9)</sup>. Corticosteroid is the important drug for most cases of inflammatory vasculitis, and KD is typically acquired due to vasculitis in childhood.

Infliximab is a monoclonal antibody that binds to and inhibits tumor necrosis factor- $\alpha$  (TNF- $\alpha$ ). Infliximab can reduce the disease associated inflammation in patients with KD, thus it is a treatment option for patients with IVIG nonresponsive or resistant KD<sup>10)</sup>. We thought that our patient may have uncontrolled or partially controlled inflammation because he had re-developed fever, arthralgia, and general weakness after IVIG and methylprednisolone pulse therapy and tried infliximab to patient for control of inflammation according to guideline.

The following are the common findings between our case and other patients with myocarditis<sup>5,6)</sup>: 1) the patients with symptomatic myocarditis were older than 6 years, and 2) cervical lymphadenopathy and fever were the only initial features of KD.

Patients with cervical lymphadenopathy and fever as the only initial features of KD on the admission day, so called node-first presentation of KD, were older than the other KD patients and showed greater abnormalities in the markers of systemic inflammation and required additional IVIG treatment<sup>11)</sup>. The presence of cervical lymphadenopathy in KD may reveal the presence of more severe inflammation, which may result in symptomatic left ventricular dysfunction. Because corticosteroid has a strong anti-inflammatory effect, it is useful for left ventricular dysfunction and hypotension from severe inflammation.

In conclusion, the present case serves to highlight that methylprednisolone pulse therapy should be considered in patients with IVIG nonresponsive symptomatic

myocarditis during the acute stage of KD.

## References

1. Falcini F, Capannini S, Rigante D. Kawasaki syndrome: an intriguing disease with numerous unsolved dilemmas. *Pediatr Rheumatol Online J* 2011;9:17.
2. Newburger JW, Fulton DR. Kawasaki disease. *Curr Opin Pediatr* 2004;16:508-14.
3. Kim GB, Han JW, Park YW, Song MS, Hong YM, Cha SH, et al. Epidemiologic features of Kawasaki disease in South Korea: data from nationwide survey, 2009-2011. *Pediatr Infect Dis J* 2014;33:24-7.
4. Kuwabara M, Yashiro M, Kotani K, Tsuboi S, Ae R, Nakamura Y, et al. Cardiac lesions and initial laboratory data in Kawasaki disease: a nationwide survey in Japan. *J Epidemiol* 2015;25:189-93.
5. Aggarwal P, Suri D, Narula N, Manojkumar R, Singh S. Symptomatic myocarditis in Kawasaki disease. *Indian J Pediatr* 2012;79:813-4.
6. Yoshikawa H, Nomura Y, Masuda K, Hazeki D, Yotsumoto K, Arata M, et al. Four cases of Kawasaki syndrome complicated with myocarditis. *Circ J* 2006;70:202-5.
7. Schultheiss HP, Kühl U, Cooper LT. The management of myocarditis. *Eur Heart J* 2011;32:2616-25.
8. Rosenfeld EA, Shulman ST, Corydon KE, Mason W, Takahashi M, Kuroda C. Comparative safety and efficacy of two immune globulin products in Kawasaki disease. *J Pediatr* 1995;26:1000-3.
9. Singh S, Rohit M, Gupta A, Suri D, Rawat A. Late symptomatic myocarditis in Kawasaki disease: an unusual manifestation. *Indian J Pediatr* 2014;81:404-5.
10. Saneeymehri S, Baker K, So TY. Overview of pharmacological treatment options for pediatric patients with refractory kawasaki disease. *J Pediatr Pharmacol Ther* 2015;20:163-77.
11. Fan PC, Chiu CH, Yen MH, Huang YC, Li CC, Lin TY. School-aged children with Kawasaki disease: high incidence of cervical lymphadenopathy and coronary artery involvement. *J Paediatr Child Health* 2003;39:55-7.

## 요약

저자들은 가와사키병 급성기에 치료에 반응하지 않은 저혈압(수축기 혈압 59 mmHg와 이완기 혈압 29 mmHg)과 수축기 심실 기능 부전(단축분획 22%)이 있던 7세 남아를 치료한 경험을 보고한다. 이 증례를 통해 가와사키병 급성기에 동반될 수 있는 유증상 심근염은 면역 글로블린 치료로 증상이 호전되지 않는 경우 스테로이드 펄스 요법이 필요함을 알 수 있다.