

Case Report

Ileal Fecaloma Presenting with Small Bowel Obstruction

Ha Yeong Yoo, Hye Won Park, Seong-Hwan Chang*, and Sun Hwan Bae

*Departments of Pediatrics and *Surgery, Konkuk University Medical Center, Konkuk University School of Medicine, Seoul, Korea*

A fecaloma refers to a mass of accumulated feces that is much harder than a mass associated with fecal impaction. Fecalomas are usually found in the rectosigmoid area. A 10-year-old male with chronic constipation was admitted because of increasing abdominal pain. An abdominal computed tomography scan and a simple abdominal x-ray revealed rapidly evolving mechanical obstruction in the small intestine. Most of the fecalomas are successfully treated by conservative methods such as laxatives, enemas and rectal evacuation. When conservative treatments have failed, surgical intervention may be needed. In this case, an emergency operation was performed and a 4×3×2.5 cm fecaloma was found in the distal ileum. We thus report a case of ileal fecaloma inducing small bowel obstruction in a patient with chronic constipation, who required surgical intervention. When symptoms of acute small intestinal obstruction develop in a patient with chronic constipation, a fecaloma should be considered in differential diagnosis.

Key Words: Feces, Abdominal pain, Intestinal obstruction

INTRODUCTION

A fecaloma is a laminated mass of accumulated feces that is much harder in consistency than a fecal impaction [1]. Fecalomas are usually located in the sigmoid colon or rectum, but rarely in the cecum [2,3]. Most fecalomas are successfully treated by conservative procedures such as laxatives, enemas, and rectal evacuation [2]. However, when conservative treatments fail, surgical intervention may be needed [4]. We report an ileal fecaloma in a 10-year-old male; the fecaloma induced small bowel obstruction and required surgical intervention. To

our knowledge, this is the first report of such a case in the English literature.

CASE REPORT

A 10-year-old male was admitted because of rapidly developing abdominal pain which, with fever, vomiting and diarrhea, had commenced 1 week prior. He had a history of chronic constipation with about 2 bowel movements per week and hard stool for few years. And medication for constipation was done randomly. He appeared pale; however, his vital signs were stable. His abdomen was distended and

Received : January 15, 2015, Revised : March 5, 2015, Accepted : March 9, 2015

Corresponding author: Sun Hwan Bae, Department of Pediatrics, Konkuk University Medical Center, Konkuk University School of Medicine, 120-1 Neungdong-ro, Gwangjin-gu, Seoul 05030, Korea. Tel: +82-2-2030-7554, Fax: +82-2-2030-7748, E-mail: baedori@hanafos.com

Copyright © 2015 by The Korean Society of Pediatric Gastroenterology, Hepatology and Nutrition

This is an open-access article distributed under the terms of the Creative Commons Attribution Non-Commercial License (<http://creativecommons.org/licenses/by-nc/4.0/>) which permits unrestricted non-commercial use, distribution, and reproduction in any medium, provided the original work is properly cited.

bowel sounds were increased. Tenderness was evident over the whole abdomen, but none of rebound tenderness, guarding, or rigidity was evident. Blood test data were as follows: hemoglobin, 7.1 g/dL; hematocrit, 28%; mean corpuscular volume, 54.4 fL; serum iron, 13 μ g/dL; total iron-binding capacity, 394 μ g/dL; ferritin, 3.21 ng/mL; white blood cell count, 7,680 cells/mm³ (neutrophils, 71%); blood urea nitrogen, 15.3 mg/dL; creatinine, 0.8 mg/dL; sodium, 132 mmol/L; potassium, 4.1 mmol/L; chloride, 98 mmol/L; total CO₂, 15 mmol/L; and C-reactive protein, 0.05 mg/dL. Other data were not remarkable. A simple abdominal x-ray revealed mul-

tifocal air-fluid at the mid-abdominal level, and distended small bowel loops (Fig. 1). An abdominal pelvic computed tomography (CT) scan taken on the second hospital day revealed mechanical small bowel obstruction at the distal ileum, with a transition zone (Fig. 2). In this obstructed area, we delineated hypodense mass structure; however, we couldn't identify what it was. The abdominal pain was not relieved, and bilious vomiting continued, upon application of nasogastric tube drainage. An abdominal x-ray performed on the third hospital day showed that the mechanical ileus had become increasingly aggravated.

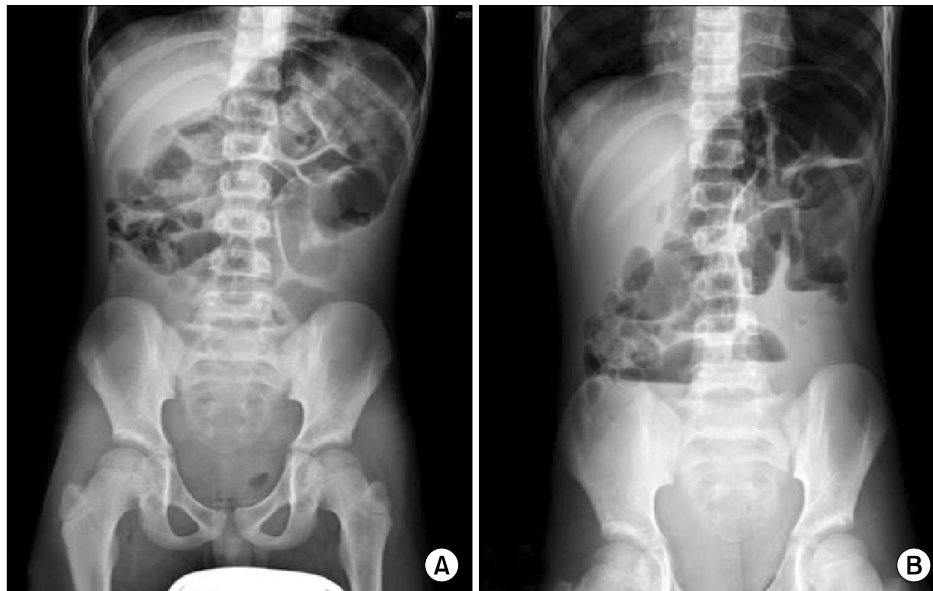

Fig. 1. A plain x-ray of the abdomen (A: supine view, B: erect view) showing a mechanical small bowel obstruction with 'step-ladder' air-fluid pattern in the erect film.

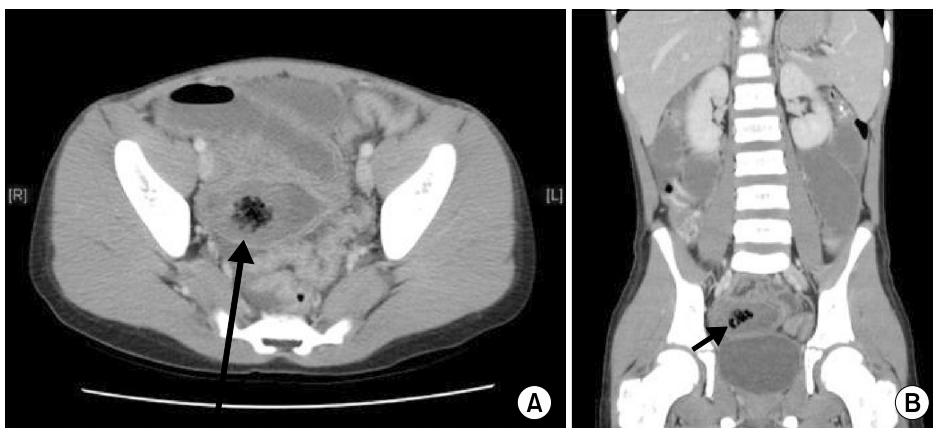

Fig. 2. Abdominopelvic computed tomography scan (A: axial view, B: coronal view) showing the 1.8 cm-sized round intraluminal hypodense mass (black arrows) with a 'mottled gas' pattern in the lumen of distal ileum.

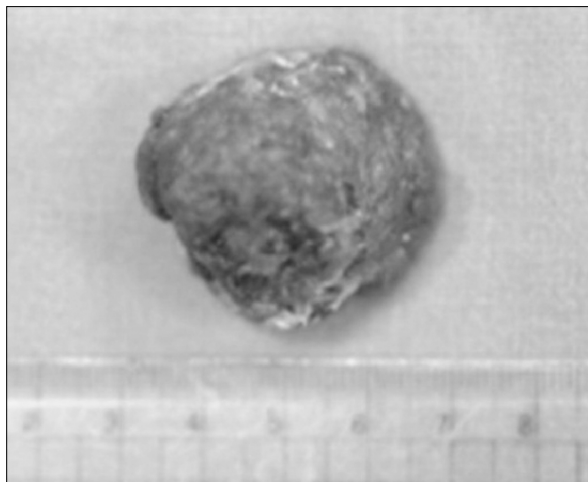


Fig. 3. The fecaloma. A 4×3×2.5 cm-sized fecaloma was found in the distal ileum at 65 cm proximal to the ileocecal valve, and removed through enterotomy.

Emergency surgery was performed on the same day, and a 4×3×2.5 cm fecaloma (Fig. 3) was found in the lumen of the distal ileum 65 cm proximal to the ileocecal valve and any other anatomical lesions (e.g., ileal atresia, ileal stenosis) were not found in operative finding. The small intestine proximal to the fecaloma obstruction was markedly distended. After the removal of the fecaloma via enterotomy, all symptoms of mechanical intestinal obstruction resolved completely. After discharge, he was treated for constipation over 6 months without complications, including fecaloma.

DISCUSSION

Although fecal impaction is common and disturbing, fecaloma is an extremely rare form of impaction, referring to an accumulation of fecal material that forms a mass separate from other bowel contents [1]. Fecalomas have been described in patients suffering from chronic constipation, Hirschsprung's disease, Chagas' disease, inflammatory diseases, neoplastic diseases, and psychiatric diseases [5]. Our present patient complained of chronic constipation, but the underlying cause was unclear.

Fecalomas occur most commonly in the recto-

sigmoid area; the small bowel is a most unusual site [2]. This may be explained by the fact that stools in the left colon are firmer than those in other regions, because the colon diameter is narrower on the left than the right [4,6]. In our present case, the fecaloma developed in the distal small intestine, provoking rapidly progressing mechanical obstruction of small intestine. However, we couldn't find any underlying small intestinal lesion related to fecaloma. To our knowledge, this report is the first in the English literature to describe an ileal fecaloma inducing mechanical small bowel obstruction, requiring surgical intervention.

The symptoms of fecaloma are usually nonspecific, including the "overflow" type of diarrhea, constipation, weight loss, and vague abdominal discomfort after meals [7]. Fecaloma diagnosis is usually made radiologically when the characteristic intraluminal mass is noted on plain x-rays, barium enema, or abdominal CT [2]. Such masses have smooth margins and are not attached to the mucosal surface, thus moving within the bowel lumen [8]. Serious complications may result; these include colonic obstruction, perforation, sciatica, ureter obstruction, secondary hydronephrosis, and deep vein thrombosis [9]. Commonly, fecalomas can be treated using conservative methods such as laxatives, enemas, and digital evacuation. However, surgical intervention may be required for fecaloma removal in some intractable cases like this patient [9].

A fecaloma in the small intestine is extremely rare. However, this should be considered in differential diagnosis when symptoms of acute mechanical small intestinal obstruction develop in a child with constipation.

REFERENCES

1. Garisto JD, Campillo L, Edwards E, Harbour M, Ermocilla R. Giant fecaloma in a 12-year-old-boy: a case report. *Cases J* 2009;2:127.
2. Cid AA, Pietruk T, Bidari CZ, Ehrinpreis MN. Cecal fecaloma mimicking colonic neoplasm. *Dig Dis Sci* 1981; 26:1134-7.

3. Gilbert RF. Cecal infarction secondary to a distal obstructing fecaloma: association with drug abuse. *South Med J* 1980;73:1296-7.
4. Sakai E, Inokuchi Y, Inamori M, Uchiyama T, Iida H, Takahashi H, et al. Rectal fecaloma: successful treatment using endoscopic removal. *Digestion* 2007;75:198.
5. Park JS, Park TJ, Hwa JS, Seo JH, Park CH, Youn HS. Acute urinary retention in a 47-month-old girl caused by the giant fecaloma. *Pediatr Gastroenterol Hepatol Nutr* 2013;16:200-5.
6. Yucel AF, Akdogan RA, Gucer H. A giant abdominal mass: fecaloma. *Clin Gastroenterol Hepatol* 2012;10:e9-10.
7. Sonnenberg A, Koch TR. Physician visits in the United States for constipation: 1958 to 1986. *Dig Dis Sci* 1989;34:606-11.
8. Kim SM, Ryu KH, Kim YS, Lee TH, Im EH, Huh KC, et al. Cecal fecaloma due to intestinal tuberculosis: endoscopic treatment. *Clin Endosc* 2012;45:174-6.
9. Rajagopal A, Martin J. Giant fecaloma with idiopathic sigmoid megacolon: report of a case and review of the literature. *Dis Colon Rectum* 2002;45:833-5.