

A Smart Setup for Craniospinal Irradiation

Jennifer L. Peterson*, Laura A. Vallow*, Siyong Kim[†], Henry E. Casale*, Katherine S. Tzou*

*Department of Radiation Oncology, Mayo Clinic, Jacksonville, Florida,

[†]Department of Radiation Oncology, Virginia Commonwealth University, Richmond, Virginia, USA

Our purpose is to present a novel technique for delivering craniospinal irradiation in the supine position using a perfect match, field-in-field (FIF) intrafractional feathering, and simple forward-optimization technique. To achieve this purpose, computed tomography simulation was performed with patients in the supine position. Half-beam, blocked, opposed, lateral, cranial fields with a collimator rotation were matched to the divergence of the superior border of an upper-spinal field. Fixed field parameters were used, and the isocenter of the upper-spinal field was placed at the same source-to-axis distance (SAD), 20 cm inferior to the cranial isocenter. For a lower-spinal field, the isocenter was placed 40 cm inferior to the cranial isocenter at a constant SAD. Both gantry and couch rotations for the lower-spinal field were used to achieve perfect divergence match with the inferior border of the upper-spinal field. A FIF technique was used to feather the craniospinal and spinal-spinal junction daily by varying the match line over 2 cm. The dose throughout the target volume was modulated using the FIF simple forward optimization technique to obtain homogenous coverage. Daily, image-guided therapy was used to assure and verify the setup. This supine-position, perfect match craniospinal irradiation technique with FIF intrafractional feathering and dose modulation provides a simple and safe way to deliver treatment while minimizing dose inhomogeneity.

Key Words: Dose modulation, Field matching, Intrafractional feathering, Daily feathering

INTRODUCTION

Craniospinal irradiation (CSI) is a technically challenging treatment for radiation oncologists. Historically, CSI was delivered with patients in the prone position by opposed, lateral, cranial fields matched to posterior spine fields. Prone positioning allows direct visualization of the field junctions between craniospinal and spinal-spinal fields. However, the prone position can be uncomfortable for many patients, particularly elderly and deconditioned patients. In addition, pediatric patients require general anesthesia for CSI, and setting up patients under anesthesia in the prone position is not only difficult but also less secure.

Recent advances in the delivery of CSI include techniques for treating patients in the supine position.¹⁻³⁾ Supine positioning offers several advantages, including a comfortable, stable, and reproducible position for treatment and improved ability to deliver general anesthesia. We report a novel technique for CSI in the supine position using a perfect match and simple forward-optimization field-in-field (FIF) technique to feather the junctions daily and to create homogenous coverage of the target volume.

MATERIALS AND METHODS

Computed tomography (CT) simulation was performed with the patient in the supine position. Immobilization was achieved using an all-in-one body immobilization system with an indexable carbon-fiber baseplate underneath the full length of the patient. A head support with a cranial stop was placed over a wedge, with the heel oriented inferiorly; this allowed maximal extension of the neck and minimized the exit dose through the mandible from the posterior upper-spinal field. Thermoplastic

2013 Mayo Foundation for Medical Education and Research.
Siyong Kim, PhD, owns interests of Medical Tool and Technology, LLC. The other authors have no conflicts of interest to disclose.
Submitted November, 27, 2013, Accepted December, 6, 2013
Corresponding Author: Jennifer L. Peterson, Department of Radiation Oncology, Mayo Clinic, 4500 San Pablo Rd, Jacksonville, FL 32224, USA
Tel: +1-904-953-1003
E-mail: Peterson.jennifer2@mayo.edu

molds were positioned for immobilization—one over the head and neck, another over the thorax and upper abdomen. The lower extremities were elevated (using an indexable knee and leg positioning system) to the angle that maximally flattened the spine. Anterior-posterior (AP) images were obtained to confirm the alignment of the spine, and lateral scout CT images were obtained to verify flattening of the spine against the tabletop and maximum extension of the neck.

After the patient was properly positioned, a CT scan from the cranial aspect of the skull through the pelvis was obtained. Images were transferred to a virtual simulation workstation. The clinical target volume was defined as the whole brain and spinal axis to the caudal aspect of the thecal sac. This volume was outlined on each CT image. A postoperative magnetic resonance image was coregistered with the simulation CT scan to help define the lower border of the thecal sac.

The brain field was designed with opposed lateral beams with an asymmetric, half-beam block at the isocenter to provide a nondivergent beam edge at the match line of the upper-spinal field. The isocenter was placed at midplane and midline at the level of the cervical spine. The superior-inferior (SI) placement of the isocenter was chosen at a point within the cervical spine that allowed full coverage of the target within 20 cm (ie, the asymmetric half of the maximal field in the y-axis) while avoiding entrance of the beams through the shoulders or exit of the beam through the mandible. A collimator rotation of 11° was used to match the divergence of the upper-spinal field.

The upper-spinal field isocenter was placed 20 cm distal to the brain field isocenter, at the same source-to-axis distance (SAD). The superior portion of the upper-spinal field was always 20 cm, which allowed a consistent collimator rotation of 11° for the brain field. If a lower-spinal field was required to cover the target volume, the isocenter of the lower-spinal field was placed 40 cm distal to the brain field isocenter at the same SAD (ie, 20 cm distal to the upper-spinal isocenter at the same SAD). A 90° couch rotation with an 11° gantry rotation (actual gantry angle was 169° on the International Electrotechnical Commission scale) for the lower-spinal field allowed a perfect match of the divergence from both the upper- and lower-spinal fields. Obtaining a nondivergent match between spinal fields reduced the risk of overdosing the spinal cord and

underdosing the target. The inferior border of the lower-spinal field was placed at the caudal end of the thecal sac. By achieving maximal flattening of the spine during simulation, a constant SAD could be used, with the isocenter of each field at an appropriate AP distance to allow for dose calculation. Using the same SAD for every isocenter required only longitudinal movement of the couch during treatment, thereby reducing the risk of error as well as keeping efficiency in patient positioning.

The width of the brain fields was adjusted to obtain full target coverage, and multileaf collimators were used to shape the field around the base of skull, avoiding critical, nontargeted structures. The width of the spine fields was adjusted to cover the lateral processes of the vertebral bodies and the dorsal foramina of the sacrum by using multileaf collimators.

A 3-dimensional (3D) treatment planning system with 6-MV photons was used to generate treatment plans. Junctions were feathered daily with multileaf collimators using a FIF technique. This technique involved opening the inferior border of the brain fields and superior border of the lower-spinal field by 1 cm daily, for a total of 2 cm. At the same time, the upper-spinal field was reduced superiorly and inferiorly to match the edge of the cranial and lower-spinal fields. This technique eliminated the need to physically move the patient to feather the junction, thereby removing another potential source of error. With conventional CSI planning, the cervical spine and thecal sac may be underdosed or overdosed because of curvature of the spine or varying body thickness, respectively. To avoid potential underdosing, we used the FIF technique to modulate the dose in this area to improve homogenous coverage of the target volume.

Daily imaging was used to verify the treatment position. Daily, opposed, lateral, kilovoltage (kV) images confirmed the accuracy of the brain field isocenter, and daily AP and lateral kV images verified the isocenter of the upper-spinal field. For the lower-spinal field, AP and lateral kV images were taken before the couch rotation to confirm the correct position of the patient, and a posterior-anterior (PA) megavoltage portal image verified the isocenter after rotation. Variance of more than 3 mm was not accepted.

RESULTS

The technique described above was performed with a 42-year-old man with a multifocal germinoma and abnormal cerebral spinal fluid findings requiring CSI treatment. Fig. 1 shows the patient on the treatment planning table, with maximal head extension and flattened spine. Also shown are the direction of daily feathering and the nondivergent matching of each field. Fig. 2 illustrates the couch and gantry rotation used to match the divergence of the upper- and lower-spinal fields. The FIF technique was used to safely match the craniospinal and spi-

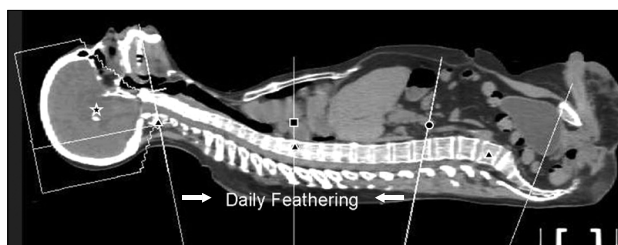


Fig. 1. Sagittal representation of the cranial field, upper-spinal field, and lower-spinal field, with each isocenter at a constant source-to-axis distance (illustrated by the star, square, and circle, respectively). Calculation points for each field are indicated by triangles.

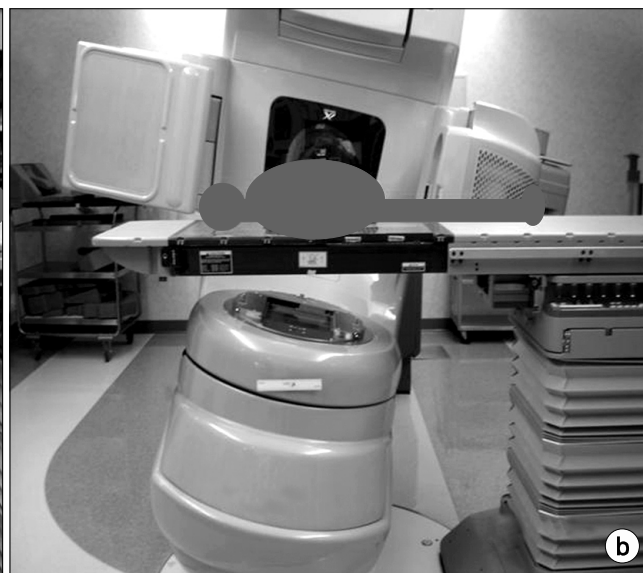
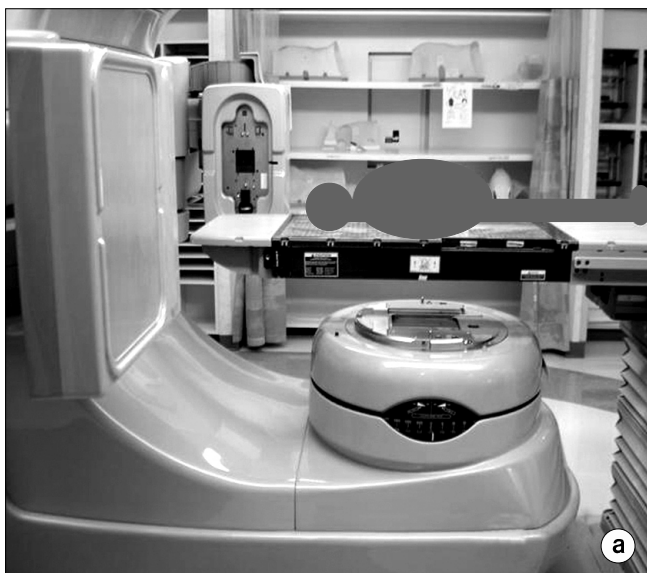
Fig. 2. Couch and gantry rotation for the spinal fields. (a) Upper spine (couch, 0° ; gantry, 180°). (b) Lower spine (couch, 270° ; gantry, 191°).

nal-spinal junctions daily (Fig. 3, 4a-c, 5). The caudal edge of the cranial field was extended 1 cm per field (total, 2 cm), whereas the cranial edge of the upper-spinal field was lowered 1 cm per field (total, 2 cm) during each treatment. A similar FIF adjustment was made at the junction between the upper- and lower-spinal fields. Two additional upper-spinal fields are shown in Fig. 4d and e; this dose modulation was made to avoid “hot” (overdosed) and “cold” (underdosed) areas within the target volume. Fig. 6 shows the treatment plan without modulation and with the FIF technique. Improvement in homogeneity across the craniospinal and spinal-spinal junctions and throughout the target volume is seen.

DISCUSSION

CSI is a technically complex treatment to design and implement. Multiple matched fields are required to treat the craniospinal axis, which entails the difficult task of avoiding underdosing and overdosing at the junction of each field. In addition, obtaining homogeneous coverage of the entire craniospinal axis is difficult because of variation in depth of the target volume along the length of the treatment field.

Historically, patients were treated in the prone position for CSI. Prone positioning facilitates visualization of the junctions

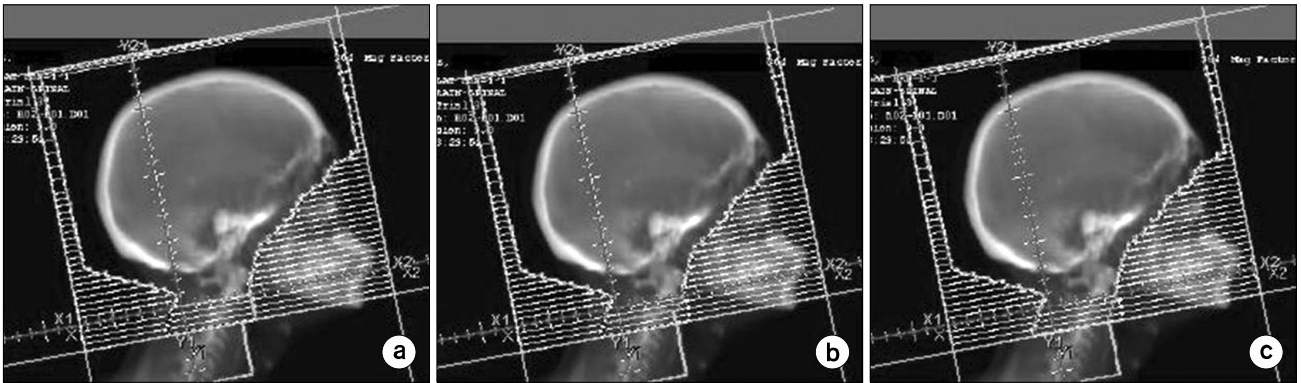


Fig. 3. (a) Cranial treatment field. (b) and (c), Illustration of the field-in-field technique used to feather the match of the craniospinal junction.

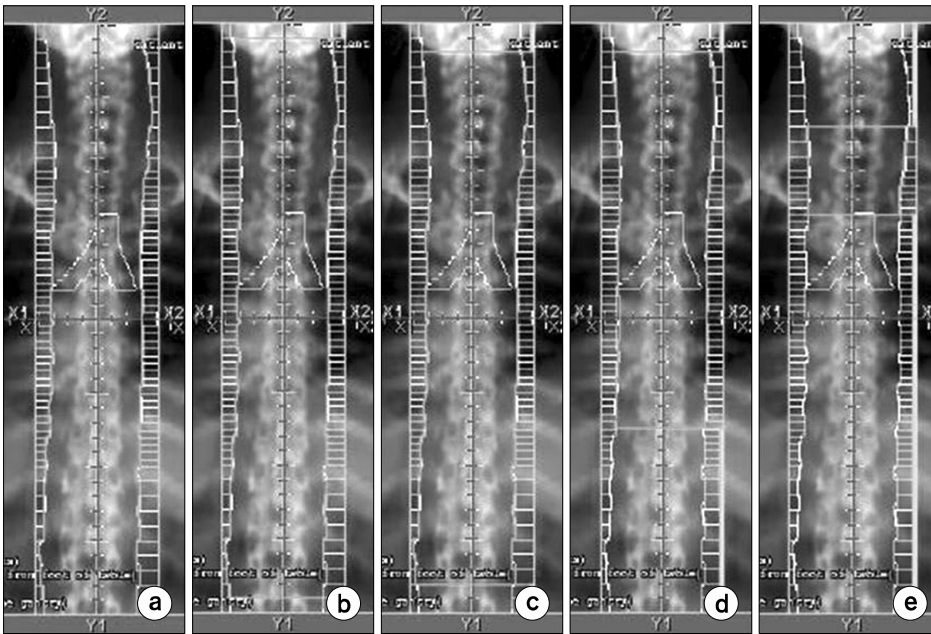


Fig. 4. (a) Upper-spinal treatment field. (b) and (c), Illustration of the field-in-field technique used to feather the match of the cranio-spinal junction superiorly and the spinal-spinal junction inferiorly. (d) and (e) Illustration of the field-in-field technique used to modulate the dose throughout the upper-spinal field.

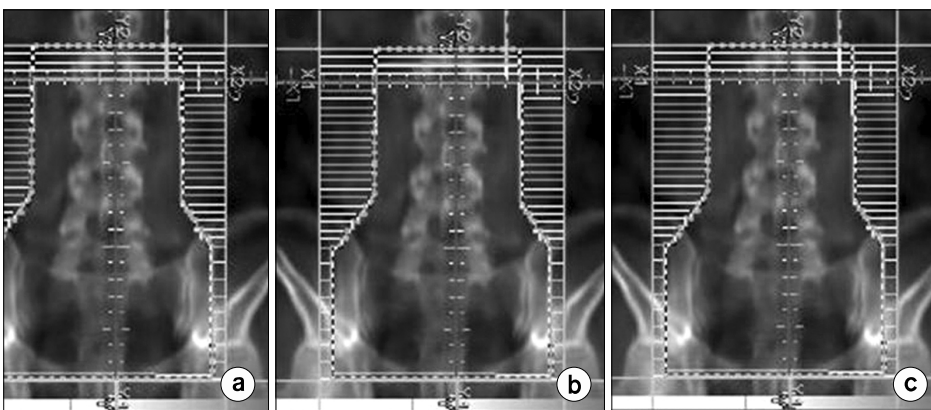


Fig. 5. (a) Lower-spinal treatment field. (b) and (c), Illustration of the field-in-field technique used to feather the match of the spinal-spinal junction.

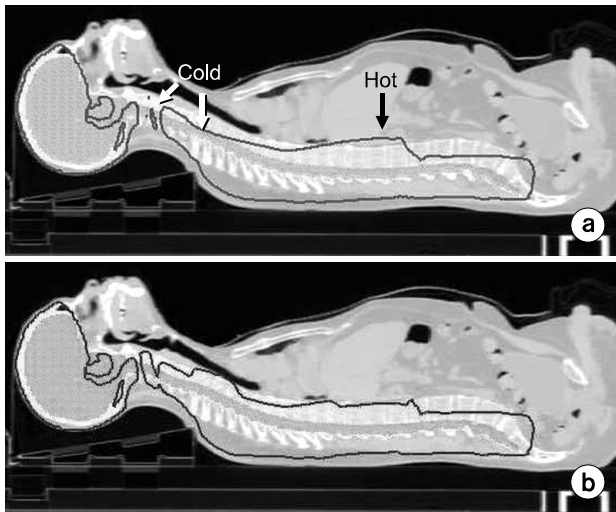


Fig. 6. Sagittal reconstruction of dose distribution. (a) Without dose modulation. (b) With field-in-field dose modulation. Target volume is green, 100% isodose line is red.

between each field, which is a critical part of the planning and verification process for accurate delivery of CSI in the past, especially when image guidance technique was not mature. However, the prone position is uncomfortable for patients. Therefore, supine positioning for CSI has become an attractive option to increase patient comfort and enhance stability and reproducibility of the treatment position. For pediatric patients, delivery of general anesthesia is easier in the supine position than the prone position.

Techniques for CSI in the supine position, using both conventional fluoroscopic and CT simulators, are described in the literature.¹⁻⁴⁾ The fluoroscopic simulation techniques are cumbersome and limit the radiation oncologist's ability to delineate and visualize coverage of the target volume in 3 dimensions. In contrast, CT simulation can be relatively simple.

Parker and Freeman¹⁾ described a technique for CSI in the supine position that is similar to our technique; they used fixed field positions, half-beam blocked cranial fields, and constant SADs between each field, requiring only longitudinal movement of the couch. However, if a second spinal field was needed, the 2 spinal fields were matched at the depth of the posterior surface of the vertebral body, resulting in inhomogeneity of the dose at the match line. Although an additional couch rotation is required, an advantage of our technique is a nondivergent match line for the upper- and lower-spinal fields.

By combining a couch and gantry rotation, the lower-spinal field matches the divergence of the caudal border of the upper-spinal field with no overlap, resulting in less inhomogeneity. However, the combination of the couch and gantry rotation creates more divergence inferiorly, which can increase the dose to the testes and therefore may not be appropriate for young males or requires proper shielding.

The most commonly described method for feathering junctions consists of shifting the SI limits of each field 2 or 3 times during the course of treatment, which often requires translational movement of the patient. Our method uses a FIF technique for intrafractional feathering of both the craniospinal and spinal-spinal junction. FIF intrafractional feathering varies the junction of each field daily, thereby reducing the risk of overlap or gaps between daily matched fields and negating the need for patient movement. Additionally, FIF feathering can minimize dose inhomogeneity at the field junctions. The advantages are increased safety for patients and improved dose coverage of the treatment volume. South et al.⁴⁾ described using FIF intrafractional feathering with their supine position CSI technique. Twenty-three patients were treated with a FIF technique (3~4 FIF modulations at each junction) to feather the dose. At a follow-up of 20.2 months, no failures occurred at the junctions and no radiation myelitis was documented.

The FIF technique can also modulate the dose throughout the craniospinal axis. Due to the curvature of the spine and variation in depth of the spinal cord, hot and cold spots can occur along the length of the target volume, commonly in the lower cervical spine and thecal sac. With our technique, we used FIF technology to obtain a homogeneous dose distribution throughout the target volume. A similar technique in patients treated in the prone position has been described by Yom et al.⁵⁾ In 5 patients treated with 7 to 10 reduction fields, the thecal sac volume receiving at least 110% of the prescribed dose ranged from 1% to 30% with FIF modulation and 39% to 75% without FIF modulation. In addition, the volume of the thecal sac receiving at least 120% of the prescribed dose was 0% with modulation and 6% to 36% without modulation.

Inverse-planned, intensity-modulated radiotherapy (IMRT) is often used to modulate dose, and a few reports of IMRT for CSI have recently been published.⁶⁻⁸⁾ Parker et al.⁷⁾ compared treatment plans for a 2-dimensional (2D) technique, a 3D tech-

nique, and an inverse-planned IMRT technique (using 5 beams) in 3 separate patients. The target volume coverage and dose homogeneity improved with the IMRT technique. The target volume receiving 95% of the prescription dose was 98% for 2D treatment; 96% for 3D treatment, and 100% for IMRT. The volume receiving 107% of the prescription dose was 37% for 2D treatment; 38% for 3D treatment; and 3% for IMRT. IMRT also improved the dose to organs at risk for volumes receiving 10 Gy, 15 Gy, and 20 Gy; however, IMRT resulted in higher integral dose for the volumes receiving 5 Gy or less. Kusters et al.⁸⁾ compared IMRT and 3D conventional planning in 5 patients. With IMRT, daily intrafractionally modulated junctions were generated and 5 coplanar beams were used. The volumes receiving less than 95% and greater than 107% of the prescribed dose at the craniospinal and spinal-spinal junctions were 3 to 9 cm³ and 26 to 43 cm³, respectively, for 3D treatment planning; in comparison, IMRT had volumes less than 1 cm³ for both end points. Thus, IMRT provided a more homogeneous dose across the field junctions. Pai Panandiker et al.⁶⁾ described a technique using inverse-planned IMRT for spine treatment through 1 PA field. The target volume used for optimization was a 2-cm lateral margin on each side of the spinal canal, and modulation of dose occurred in the SI and lateral directions only. When compared with a traditional PA field, IMRT improved the percentage of the target volume receiving greater than 95% and less than 107% of the prescribed dose, but it also delivered an increased dose to the paraspinal muscles.

Although IMRT offers improvement in target volume coverage, dose homogeneity, and avoidance of organs at risk, concerns remain about implementation of IMRT for CSI. IMRT results in increased integral dose with multiple beams and requires increased monitor units for treatment; both factors are a concern with pediatric patients. In addition, use of IMRT requires accurate delineation of the target volume, which has not been described or validated with outcomes data using IMRT.

Verification of the field junction between craniospinal fields and spinal-spinal fields is a concern for supine positioning because visualization of the light field on the patient is no longer applicable. Chang et al.⁹⁾ described 2 verification techniques for the supine position. Daily verification required placement of a wire over the patient's chin to mark the inferior border of

the light field from the cranial field, followed by a PA portal image of the spinal field to verify the approximate gap at the craniospinal junction, which was planned at 0.3 cm separation. The second technique, performed before the first treatment and at junction shifts, used a custom-designed film holder to fold the film at 90°, allowing exposure of both fields on one film, assuring no overlap occurred. Other authors described use of verification films placed near the patient for daily verification of the junction fields.^{10,11)} We used daily kV imaging to verify the position of the cranial and upper-spinal field isocenter. Because the kV imager is not operational with couch rotations, we took a kV image of the lower-spinal field before couch rotation to verify the isocenter; after couch rotation, we obtained a megavoltage portal image. Our verification technique using electronic portal imaging is less cumbersome and requires less therapist time in the treatment room than previously described verification techniques.

With optimization of CSI treatment techniques in the supine position, confirmation of comparable outcomes among patients treated in the prone and supine positions is necessary. Huang et al.¹²⁾ described similar outcomes and toxicity after a median follow-up of 32.4 months for 14 patients with medulloblastoma treated in the supine position. Similarly, South et al.⁴⁾ reported 5 treatment failures among 23 patients after 20.2 months of follow-up in patients who underwent supine-position radiotherapy for various cancers. Additional data likely are forthcoming as supine-positioning techniques are adopted by more radiation oncologists.

The technique reported in this study, we believe, is relatively simple to implement and accurate treatment can be efficiently made. For instance, it took on average 25 to 30 minutes for the patient treatment. It was little longer on the first day (mainly due to extra cautionary steps taken) but went down to about 15 minutes when all the staff got fully familiar with the procedure.

CONCLUSION

CSI is a technically challenging treatment to implement and deliver. FIF intrafractional feathering, dose modulation, and perfect match in conjunction with our supine positioning CSI technique, provided a simple and safe way to deliver treatment

while minimizing dose inhomogeneity.

REFERENCES

1. **Parker WA, Freeman CR:** A simple technique for craniospinal radiotherapy in the supine position. *Radiother Oncol* 78(2):217–222. (2006) Epub 2005 Dec 5
2. **Munshi A, Jalali R:** A simple technique of supine craniospinal irradiation. *Med Dosim* 33(1):1–5 (2008)
3. **Hawkins RB:** A simple method of radiation treatment of craniospinal fields with patient supine. *Int J Radiat Oncol Biol Phys* 49(1):261–264 (2001)
4. **South M, Chiu JK, Teh BS, Bloch C, Schroeder TM, Paulino AC:** Supine craniospinal irradiation using intrafractional junction shifts and field-in-field dose shaping: early experience at Methodist Hospital. *Int J Radiat Oncol Biol Phys* 71(2):477–483 (2008). Epub 2007 Dec 31
5. **Yom SS, Frija EK, Mahajan A, et al:** Field-in-field technique with intrafractionally modulated junction shifts for craniospinal irradiation. *Int J Radiat Oncol Biol Phys* 69(4):1193–1198 (2007)
6. **Pai Panandiker A, Ning H, Likhacheva A, et al:** Craniospinal irradiation with spinal IMRT to improve target homogeneity. *Int J Radiat Oncol Biol Phys* 68(5):1402–1409 (2007) Epub 2007 Apr 30
7. **Parker W, Filion E, Roberge D, Freeman CR:** Intensity-modulated radiotherapy for craniospinal irradiation: target volume considerations, dose constraints, and competing risks. *Int J Radiat Oncol Biol Phys* 69(1):251–257 (2007)
8. **Kusters JM, Louwe RJ, van Kollenburg PG, et al:** Optimal normal tissue sparing in craniospinal axis irradiation using IMRT with daily intrafractionally modulated junction(s). *Int J Radiat Oncol Biol Phys* 81(5):1405–1414 (2011)
9. **Chang EL, Wong PF, Forster KM, Petru MD, Kowalski AV, Maor MH:** Verification techniques and dose distribution for computed tomographic planned supine craniospinal radiation therapy. *Med Dosim* 28(2):127–131 (2003)
10. **Rades D, Baumann R, Bremer M, Leuwer M, Karstens JH:** Application of a new verification technique allowing craniospinal irradiation in supine position. *Radiother Oncol* 58(2):215–217 (2001)
11. **Liu AK, Thornton D, Backus J, Dzingle W, Stoeher S, Newman F:** Supine craniospinal irradiation setup with two spine fields. *Med Dosim* 34(3):214–216 (2009) Epub 2008 Oct 7
12. **Huang F, Parker W, Freeman CR:** Feasibility and early outcomes of supine-position craniospinal irradiation. *Pediatr Blood Cancer* 54(2):322–325 (2010)