



An unusual presentation of ovarian dermoid cyst: a case report and review of literature

Mohamed Amine Azami¹, Iliass Elalami², Abderrahim Siati³, Najjat Lamalmi¹

¹Department of Pathology, Child Hospital, ²Department of Oncology, Mohamed V Military Hospital, ³Department of Gynecology and Obstetrics, Mohammed V University, Rabat, Morocco

Dermoid cysts or mature cystic teratoma are the most common type of ovarian germ cell tumor. It may be complicated by torsion, rupture, chemical peritonitis and malignant change but is rarely complicated by infection. We present a case of an ovarian dermoid cyst with super-infection caused by *Schistosoma haematobium* (*S. haematobium*). We present here a case of incidental finding of *S. haematobium* eggs in an infected cystic teratoma of the ovary because of the rare occurrence of this lesion. A 45-year-old Moroccan woman admitted to the gynecological department because of abdominal pain and fever. Gynecological examination, ultrasonography, and abdominopelvic computed tomography scan revealed an ovarian mass thought to be a dermoid cyst. The pathological evaluation suggested infected ovarian dermoid cyst with the presence of adult worm in the tumor, contains same eggs of *S. haematobium*. Super-infection of an ovarian dermoid cyst is a rare event, and the association with *S. haematobium* is extremely rare in the literature.

Keywords: Dermoid cyst; Ovary; Infection; *Schistosoma haematobium*

Introduction

Schistosomiasis is a water-borne parasitic disease caused by infection with trematode worms of the genus *Schistosoma*. The disease was originally described in Egypt by Theodor Bilharz in 1851 and today can be found throughout Africa, South America, and Asia [1].

The analysis of case reports and case series shows that every female genital organ (vulva, vagina, uterine cervix, uterine body, fallopian tubes, and ovaries) can be affected by schistosomiasis and the majority is caused by *Schistosoma haematobium* (*S. haematobium*) [2].

The presence of *Schistosoma* eggs or worms in a teratoma of the ovary is a very rare occurrence. To our knowledge; only 5 cases appear to have been documented in the world literature [3-7].

Mature cystic teratoma may be complicated by torsion, rupture, and malignant change, but is rarely complicated by infection [8]. We present here a case of incidental finding of *S. haematobium* eggs in an infected cystic teratoma of the ovary because of its rarity.

Case report

She is a 45-year-old Moroccan patient. She was followed for Parkinson's disease for 8 years. Intrauterine device (IUD) set up 2 years ago. The patient was gravida 8 and para 7 and 1 abortion.

She was admitted to gynecological emergencies for fever with acute pelvic pain. The clinical examination revealed a localized defense at the level of the right iliac fossa. Her temperature was 39.8°C. The gynecological examination shows the presence of yellowish fetid leucorrhea, a normal aspect of

Received: 2017.07.04. Revised: 2017.08.07. Accepted: 2017.08.14.
Corresponding author: Mohamed Amine Azami
Department of Pathology, Child Hospital, Mohammed V
University, Rabat 10000, Morocco
E-mail: dr.azamiamine.aa@gmail.com
<https://orcid.org/0000-0002-8794-8069>

Articles published in Obstet Gynecol Sci are open-access, distributed under the terms of the Creative Commons Attribution Non-Commercial License (<http://creativecommons.org/licenses/by-nc/3.0/>) which permits unrestricted non-commercial use, distribution, and reproduction in any medium, provided the original work is properly cited.

Copyright © 2018 Korean Society of Obstetrics and Gynecology

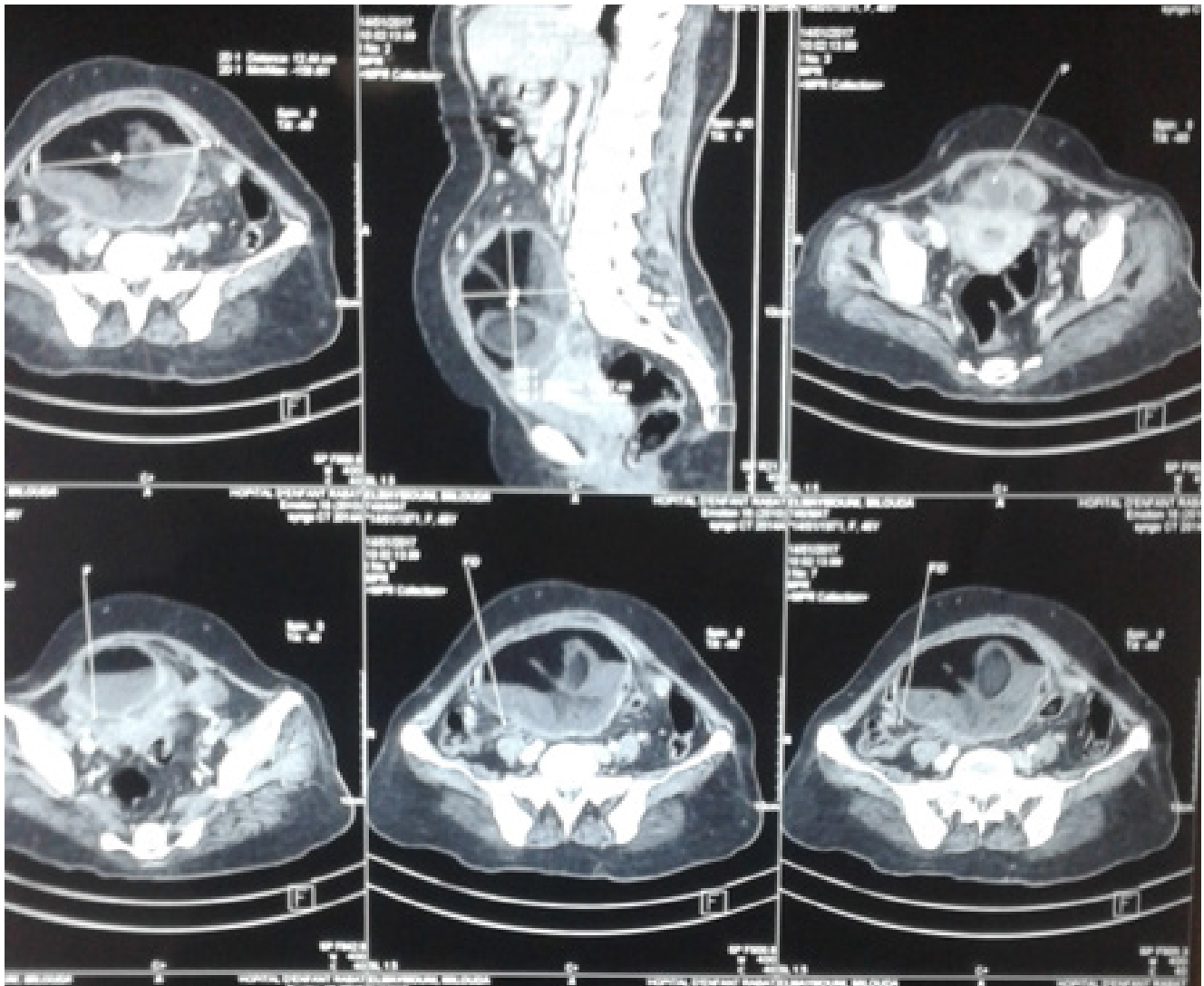


Fig. 1. Abdominal-pelvic computed tomography shows the presence of a triple component mass related to a right dermoid cyst with homolateral pyosalpinx.

the cervix, an IUD wire in place, no bleeding, with the presence of a mobile lateral-uterine mass. Cervical motion, uterine, and lower abdominal tenderness may also be present. Unilateral adnexal tenderness may suggest the presence of a tubo-ovarian abscess.

The blood cell count was normal and C-reactive protein at 290 mg/L. Bacteriological examination of IUD and vaginal specimen reveals the presence of *Escherichia coli*.

Pelvic ultrasound revealed a lateral uterine partially echogenic mass with posterior sound attenuation contained hyperechoic material consistent measuring 11×10 cm evoking first a dermoid cyst.

Pelvic computed tomography shows a large dermoid cyst

in relation to the right ovary measuring 11.4×11.6×8.6 cm of anterior abdominal-pelvic seat with image of homolateral pyosalpinx continues to the level of the right iliac fossa without appendicular extension (Fig. 1).

Laparotomy finds a voluminous right dermoid cyst (presence of hairs, teeth) superinfected with more than 500 mL of pus (sterile to bacteriological examination).

A cystectomy, bilateral adnexectomy, appendectomy of principle and ablation of a part of the necrotic epiploon with abundant saline wash were performed.

On macroscopic examination, the right adnexectomy showed a unilocular cystic appearance containing grayish putty like material entangled with plenty of hair. The inner

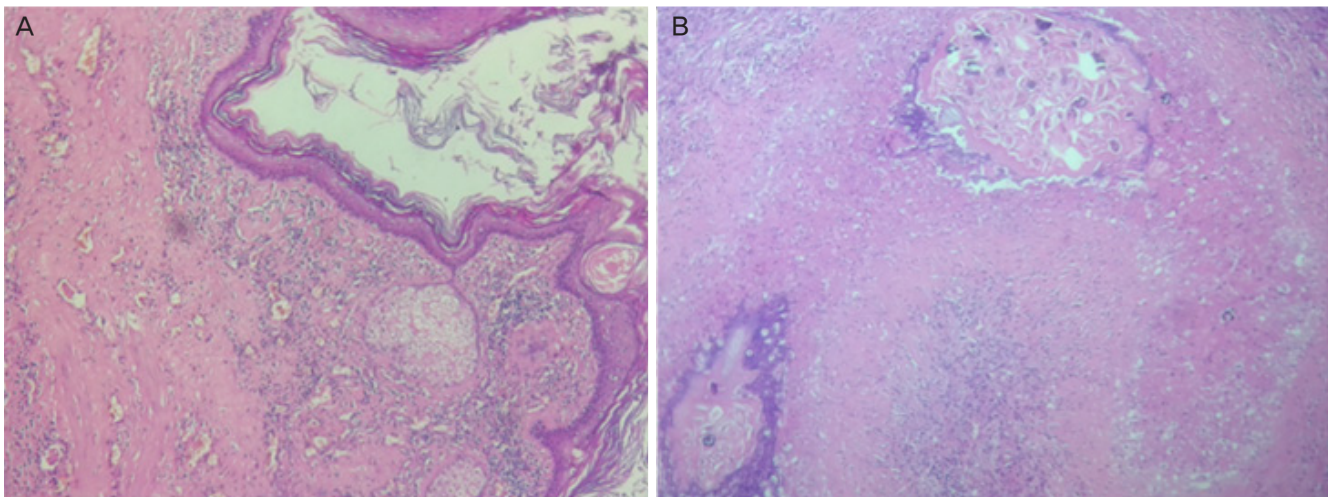


Fig. 1. (A) Section showing ovarian mature cystic teratoma surrounded by a large polymorphic inflammatory reaction of altered and non-altered neutrophil polynuclear cells, lymphocytes, plasma cells, and macrophages. (B) High power view showing an adult worm with *Schistosoma haematobium* egg surrounded by granulomatous inflammatory infiltrate (hematoxylin and eosin 40×).

surface of the cyst wall was rough, grayish brown with hair protruding at places measuring 11×10 cm, the ovary was covered by false membranes and pus.

The histological examination shows a mature dermoid cyst surrounded by a large polymorphic inflammatory reaction of altered and non-altered neutrophil polynuclear cells, lymphocytes, plasma cells, and macrophages (Fig. 2A).

On the other hand, we noticed a presence of a cluster of eggs on the periphery of the cyst with a lateral spur inside an adult worm surrounded by a granulomatous reaction with giant cells. The diagnosis of *S. haematobium* was confirmed by parasitologist (Fig. 2B).

The patient received a single dose of praziquantel (40 mg/kg). The search for Bilharziasis eggs in feces and urine returned negative. The postoperative evolution was favorable with clinical and biological improvement. The patient is under surveillance.

Discussion

Mature cystic teratomas commonly called dermoid cysts, are the most common benign germ cell tumors of ovary, comprising up to 30% of all ovarian tumors [9].

Mature cystic teratoma is rarely complicated by infection. Infection occurs in approximately 1% of mature cystic teratoma, the infecting organism most likely being coliforms, actinomycosis, brucella, salmonella. The schistosomiasis is rarely

reported [10].

Schistosomiasis is an important parasitosis in view of its high prevalence worldwide and few descriptions of schistosomiasis affecting the ovary are found in the international literature [11].

Ovarian or tubal adnexal masses associated with *S. haematobium*, *Schistosoma mansoni* or *Schistosoma japonicum* infections have rarely been reported in the literature. Various types of adnexal tumors associated with schistosomiasis have been described such as teratoma, arrhenoblastoma, cystadenoma, ovarian carcinoma, ovarian Brenner cell tumor, ovarian thecoma, carcinoma of the fallopian tube, mucinous cystadenocarcinoma, and papillary serous carcinoma [2].

There are a few reports of *S. haematobium* being found in a teratoma of the ovary. In all these cases the finding of *Schistosoma* eggs was considered as incidental finding than as causative finding [7]. There is no evidence so far to say that schistosomiasis can be a pathogenic factor in the development of teratoma of the ovary.

Histologically, the tissue around both viable and dead *S. haematobium* eggs has increased vascularity and a high density of macrophages, lymphocytes, foreign body giant cells, eosinophils, neutrophils, plasma cells, Langerhans cells, fibroblasts, and multinucleate histiocytes [12,13]. These lesions can be responsible for infection of ovary dermoid cyst.

During our review of the literature, we encountered a few reported cases of infected dermoid cysts. The only reported case of an infected dermoid cyst by *Schistosoma* are de-

scribed by Melato et al. [6] from Italy in 1987. The other cases reported in the literature describe only an association of the dermoid cyst with the schistosomiasis without infectious or inflammatory signs.

The pathological alterations due to the presence of schistosome eggs in the genitalia of women have been defined as a particular entity called female genital schistosomiasis and we know that it can affect all of the genital tract with serious health implication [2].

In terms of disease management, the current gold standard to treat schistosomiasis is a single dose of 40 mg/kg of praziquantel according to the World Health Organization recommendation (2016).

Incidental findings like in the present case should alert the community health worker to think and to know this entity for a better therapeutic management in order to minimize the damage of this public health problem.

The presence of unusual findings like fever, intermittent abdominal pain, and other signs can lead to consider a possible super infection of benign pelvic masses like dermoid cysts by the physician.

In conclusion, studies on the association between schistosomiasis and ovarian dermoid cyst are sparse in the literature; therefore, further studies should be conducted in endemic areas to provide further information on this association and on treatment in order to improve the current situation.

Conflict of interest

No potential conflict of interest relevant to this article was reported.

References

1. Colley DG, Bustinduy AL, Secor WE, King CH. Human schistosomiasis. *Lancet* 2014;383:2253-64.
2. Christinet V, Lazdins-Helds JK, Stothard JR, Reinhard-Rupp J. Female genital schistosomiasis (FGS): from case reports to a call for concerted action against this neglected gynecological disease. *Int J Parasitol* 2016;46:395-404.
3. Abu Zikry AM, Fahmy K. Bilharziasis in a dermoid cyst of the ovary. *J Obstet Gynaecol Br Commonw* 1963;70:891-3.
4. Paradinas FJ. Schistosomiasis in a cystic teratoma of the ovary. *J Pathol* 1972;106:123-6.
5. Sunder-Raj S. Cystic teratoma of ovary associated with schistosomiasis. *East Afr Med J* 1976;53:111-4.
6. Melato M, Muuse MM, Hussein AM, Falconieri G. Schistosomiasis in a cystic teratoma of the ovary. *Clin Exp Obstet Gynecol* 1987;14:57-9.
7. Sarma NH, Agnihotri S, Jeebun N. Incidental schistosomiasis in a dermoid cyst of the ovary: a case report. *Internet J Parasit Dis* 2007;3.
8. Hasanzadeh M, Tabare S, Mirzaean S. Ovarian dermoid cyst. *Professional Med J* 2010;17:512-5.
9. Ayhan A, Bukulmez O, Genc C, Karamursel BS, Ayhan A. Mature cystic teratomas of the ovary: case series from one institution over 34 years. *Eur J Obstet Gynecol Reprod Biol* 2000;88:153-7.
10. Pradhan P, Thapa M. Dermoid cyst and its bizarre presentation. *JNMA J Nepal Med Assoc* 2014;52:837-44.
11. Chambô Filho A, Neves Ferreira R, Gusmão CB, Saade FT, Dalvi IR, Leo TC. Genital schistosomiasis: mucinous cystadenocarcinoma of the ovary containing schistosoma mansoni eggs. *J Trop Med Parasitol* 2010;33:36-40.
12. Jourdan PM, Roald B, Poggensee G, Gundersen SG, Kjetland EF. Increased vascularity in cervicovaginal mucosa with *Schistosoma haematobium* infection. *PLoS Negl Trop Dis* 2011;5:e1170.
13. Helling-Giese G, Sjaastad A, Poggensee G, Kjetland EF, Richter J, Chitsulo L, et al. Female genital schistosomiasis (FGS): relationship between gynecological and histopathological findings. *Acta Trop* 1996;62:257-67.