



An extremely rare case of hand prolapse with preterm premature rupture in the membrane of one twin

Minji Kim, Hye-Joo Lee, Suk-Joo Choi, Soo-young Oh, Cheong-Rae Roh, Jong-Hwa Kim

Department of Obstetrics and Gynecology, Samsung Medical Center, Sungkyunkwan University School of Medicine, Seoul, Korea

The latency in preterm premature rupture of membranes (PPROM) can last for weeks. We describe an extremely rare case of hand prolapse with PPRM that was exposed for 23 days before delivery. The patient had spontaneous PPRM of twin A at 21.4 weeks of gestation with shoulder presentation. The right arm of the fetus eventually protruded out the vagina and the hand was exposed for extended period of time of 23 days until delivery. Daily dressing by applying collagen to dry skin and silicone to keep moisture was done to the protruding hand to prevent dehydration and desquamation of the skin. Prophylactic antibiotics were used and the patient underwent emergent cesarean section due to uncontrolled preterm labor at 25.2 weeks. To the best of our knowledge, this is the first case of hand prolapse of one twin with extended period of latency before delivery.

Keywords: Preterm premature rupture of fetal membranes; Twin pregnancy; Fetal malpresentation

Introduction

Preterm premature rupture of membranes (PPROM) before the threshold of viability occurs in below 1% of pregnancies. At present, the most common management of PPRM before 34 weeks of gestation is expectant management to prolong latency. Recommendation with PPRM in less than 24 weeks of gestation is patient counseling and prophylactic antibiotics in cases of both expectant management and induction of labor. Latency is defined as the duration from PPRM until delivery and is known to be longer in rupture occurring at earlier gestational age [1]. The possibility of adverse neonatal outcomes related to PPRM decrease with longer expectant management [2]. This is based on the perspective that the gestational age at delivery is the main component affecting neonatal outcomes [3].

There are scarce literature regarding PPRM in compound presentations and even less is available with fetal parts protruding out the vagina. One case reported a severe neonatal compartment syndrome of the right lower extremity after PPRM at 29 weeks of gestation in transverse lie [4]. Another case reports a forearm injury associated with hand presentation during full-term labor with complete recovery after postpartum day 10 [5]. Delivery occurs most commonly within 7 days of PPRM and there is no significant difference in

latency between cephalic and noncephalic presentations [6]. However, noncephalic pregnancies are prone to adverse outcomes such as placental abruption, umbilical cord prolapse, low 5-minute Apgar scores, low cord pH, intrauterine fetal death, and infections [6,7]. Here, we report an extremely rare case of hand prolapse with PPRM in one twin that had extended time of latency.

Case report

A 34-year-old, nulliparous woman became pregnant with dichorionic-diamniotic twins by *in vitro* fertilization-embryo

Received: 2017.05.04. Revised: 2017.07.17. Accepted: 2017.07.28.

Corresponding author: Soo-young Oh

Department of Obstetrics and Gynecology, Samsung Medical Center, Sungkyunkwan University School of Medicine, 81 Irwon-ro, Gangnam-gu, Seoul 06351, Korea

E-mail: ohsymd@skku.edu

<https://orcid.org/0000-0003-3002-0048>

Articles published in Obstet Gynecol Sci are open-access, distributed under the terms of the Creative Commons Attribution Non-Commercial License (<http://creativecommons.org/licenses/by-nc/3.0/>) which permits unrestricted non-commercial use, distribution, and reproduction in any medium, provided the original work is properly cited.

Copyright © 2018 Korean Society of Obstetrics and Gynecology

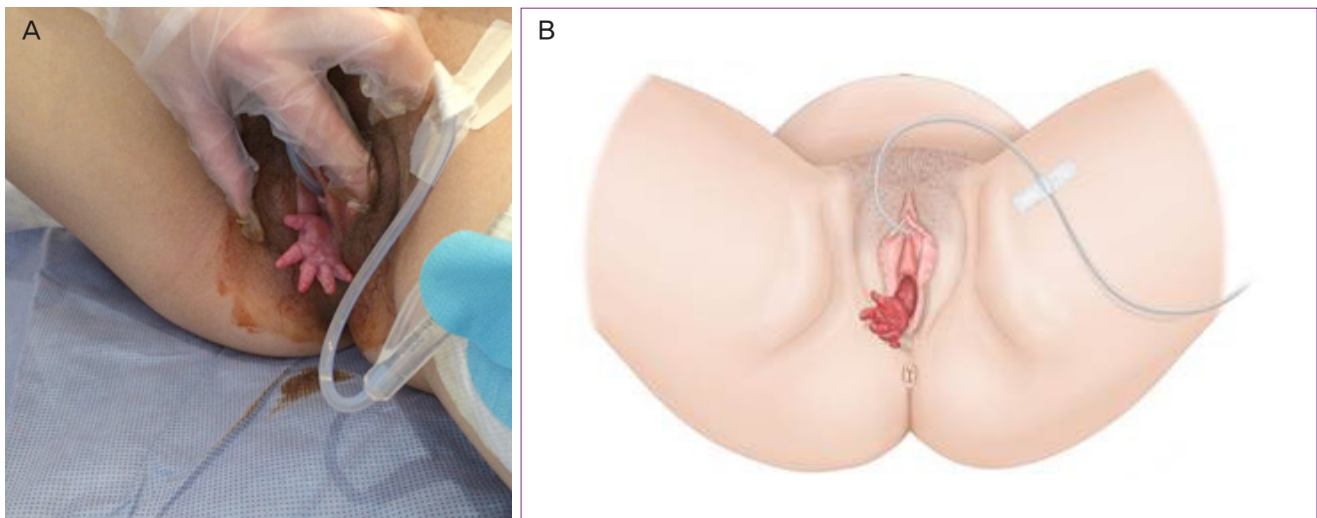


Fig. 1. (A) Photography of the hand prolapse with preterm premature rupture in the membrane of one twin. (B) Illustration of the hand prolapse with preterm premature rupture in the membrane of one twin.

transfer. At 21.4 weeks of gestation, the patient visited a tertiary hospital for watery vaginal discharge with no evident symptoms. She was diagnosed of spontaneous PPROM of twin A with shoulder presentation. At 22.0 weeks, the patient was transferred and admitted to our institution for further management. The right arm of twin A was protruding from the cervix into the vagina on initial speculum examination. Patient counseling was done considering the risk of both termination and expectant management. The patient expressed strong will to keep the pregnancy until twin B reaches the threshold of viability even at the cost of twin A. The next day, the wrist of twin A could be seen outside the vagina as depicted in Fig. 1. The medical team decided expectant management utmost to prolong gestational age at delivery of both twins so far as prolapsed hand of twin A was complicated with evident circulatory disturbance. Upon admission, intramuscular (IM) injection of 12 mg betamethasone every 24 hours for 2 days was given to the patient for fetal lung maturation. Initial C-reactive protein (CRP) level was slightly increased (1.31 mg/dL) and 7 days of prophylactic antibiotics with intravenous (IV) ceftriaxone 2 g every 24 hours, IV metronidazole 500 mg every 8 hours, oral clarithromycin 500 mg every 12 hours were given upon admission. The level of CRP decreased to 0.11 after one week of antibiotics and IV antibiotics were stopped, followed by oral clarithromycin 500 mg every 12 hours until delivery at 25.2 weeks.

The next day after hospitalization, the color changes in fingers were noted with desquamation of the skin. The change

aggravated as time passed and daily dressing was done until delivery. Cleansing the hand with normal saline and applying collagen (Healoderm; Genewel, Seongnam, Korea) to dry skin and keeping moisture with silicone contact layer (Mepitel; Mölnlycke, Gothenburg, Sweden) was done on a daily basis. At 25.2 weeks, the patient received an emergent cesarean section due to uncontrolled preterm labor despite tocolysis. Since given 3 weeks prior, a rescue betamethasone (12 mg IM) was covered before delivery. Twin A was a male and had a birthweight of 810 g with an Apgar score of 1 and 5 at 1 and 5 minutes. Twin B was a male and had a birthweight of 750 g with an Apgar score of 5 and 8 at 1 and 5 minutes. Upon birth, both were admitted to the neonatal intensive care unit (NICU). The patient showed no signs or symptoms of postpartum infection and was discharged 3 days after delivery.

Twin B was under mechanical ventilation for 5 days, continuous positive airway pressure (CPAP) for 33 days. Initial brain ultrasonography showed grade 2 intraventricular hemorrhage (IVH) which subsided on the last ultrasonography. Two doses of surfactant were given due to respiratory distress syndrome (RDS). He showed stage 1 neonatal enterocolitis (NEC) and was treated with antibiotics. He reached full enteral feeding in 14 days and was discharged 111 days after birth with a body weight of 3,299 g. On the last outpatient clinic follow up, twin B's corrected age was 8 months with normal neuro-development. Twin A was in the PPROM state for 23 days before birth with the right-hand protruding outside the vagina. At birth, the right upper extremity was externally rotated with

edema, redness, and desquamation up to the shoulder level. No other medical treatment was instituted other than normal saline irrigation with gentle handling and careful drying of the skin. The skin lesions improved in 3 days with no limitation in the range of motion of the right arm. Twin A was under mechanical ventilation for 52 days, CPAP for 144 days, and nasal cannula for 30 days. The initial brain ultrasonography showed grade 2 IVH and the last ultrasonography showed no specific findings. Three doses of surfactant were given due to RDS. He had no NEC but the blood culture revealed growth of *Serratia marcescens* and total 15 days of antibiotics were used. He reached full enteral feeding in 194 days and was discharged 218 days after birth with a body weight of 5,130 g. On the last outpatient clinic follow up, twin A's corrected ages was 17 months with questionable developmental delay according to the Denver Developmental Screening Test [8] and is scheduled to follow up at the corrected age of 2 years for Bayley Scale of Infant Development.

Discussion

In most cases of PPROM in multiple gestations, rupture of the membrane occurs in the presenting sac and is easily diagnosed by observing pooling of amniotic fluid and positive nitrazine testing [9]. PPROM in twin pregnancy is more difficult to treat than in singleton pregnancy because of the different clinical situation where one amniotic sac is broken and the other intact. This can lead to discordant risk of infection in case of prolonged latency. However, there is no significant difference in infection between the twins [10]. PPROM itself does not lead to difference in inflammation and does not seem to cause adverse outcome suggesting expectant management of twin pregnancies in PPROM.

The current recommendation in PPROM before 34 weeks of gestation is expectant management regardless of the fetal presentation. There is no difference in the duration of latency between cephalic and noncephalic presentations. However, PPROM with noncephalic presentation are more prone to adverse outcomes such as decreased amniotic fluid volume, placenta abruption, and intrauterine infections [6]. Similarly, there is increased risk for umbilical cord prolapse, lower Apgar scores, and lower cord pH levels in PPROM patients with noncephalic presentations [7].

Broad spectrum antibiotics are known to prolong latency

and prevent infections that may cause adverse outcomes [1,11]. A combination of IV ampicillin and erythromycin for 1 week followed by oral amoxicillin and erythromycin is recommended in women with PPROM undergoing expectant management [12]. Although our institution use cefazolin and clarithromycin in cases of PPROM, the medical team decided to use ceftriaxone and metronidazole with clarithromycin in concern of increased possibility of infection due to the protruding extremity.

Management of PPROM in multiple gestations before the threshold of viability is less constant compared to singleton pregnancies. Options include termination of both twins, selective reduction of the presenting PPROM twin with tocolysis to retain the other fetus [9]. Cerclage and tocolysis after vaginal delivery of the PPROM fetus is a similar option [13]. In some cases, selective feticide of the PPROM twin was performed to stop the amniotic fluid leakage to attempt improved neonatal outcome of the remaining fetus [14].

There is limited information regarding the management of the protruded fetal part in case of PPROM especially occurring before the threshold of viability with extended latency. In this case, the medical team consulted the pediatrician and the wound care team for proper management. Most effort was put to prevent infection and to keep moisture of the developing epidermis. Daily cleansing with normal saline and applying collagen to parts of dry skin and silicone to keep moisture was done until delivery. Upon admission to the NICU, hand of twin A improved in 3 days by gentle handling, and careful drying after cleansing with normal saline.

In conclusion, we report an extremely rare case of hand prolapse with PPROM in one twin that had extended period of latency. To the best of our knowledge, this is the first case of hand prolapse with extended period of latency. Furthermore, there was no maternal morbidity and the long-term outcome was favorable in both twins. This report is meaningful in that this gives an insight for future studies about the management of PPROM in one twin.

Conflict of interest

No potential conflict of interest relevant to this article was reported.

References

1. American College of Obstetricians and Gynecologists' Committee on Practice Bulletins—Obstetrics. Practice bulletin no. 172: premature rupture of membranes. *Obstet Gynecol* 2016;128:e165-77.
2. Manuck TA, Eller AG, Esplin MS, Stoddard GJ, Varner MW, Silver RM. Outcomes of expectantly managed preterm premature rupture of membranes occurring before 24 weeks of gestation. *Obstet Gynecol* 2009;114:29-37.
3. Peaceman AM, Lai Y, Rouse DJ, Spong CY, Mercer BM, Varner MW, et al. Length of latency with preterm premature rupture of membranes before 32 weeks' gestation. *Am J Perinatol* 2015;32:57-62.
4. Van der Kaay DC, Horsch S, Duvekot JJ. Severe neonatal complication of transverse lie after preterm premature rupture of membranes. *BMJ Case Rep* 2013;2013:bcr2012008399.
5. Kwok CS, Judkins CL, Sherratt M. Forearm injury associated with compound presentation and prolonged labour. *J Neonatal Surg* 2015;4:40.
6. Goodman JR, Lambert AE, Peck JD, Sutton KM, Deschamps DR. Outcomes in cephalic vs noncephalic presentation in the setting of preterm premature rupture of membranes. *Am J Obstet Gynecol* 2013;208:231.e1-8.
7. Lewis DF, Robichaux AG, Jaekle RK, Salas A, Canzonieri BJ, Horton K, et al. Expectant management of preterm premature rupture of membranes and nonvertex presentation: what are the risks? *Am J Obstet Gynecol* 2007;196:566.e1-7.
8. Frankenburg WK, Dodds J, Archer P, Shapiro H, Bresnick B. The Denver II: a major revision and restandardization of the Denver Developmental Screening Test. *Pediatrics* 1992;89:91-7.
9. Graham GM 3rd, Gaddipati S. Diagnosis and management of obstetrical complications unique to multiple gestations. *Semin Perinatol* 2005;29:282-95.
10. Mercer BM, Crocker LG, Pierce WF, Sibai BM. Clinical characteristics and outcome of twin gestation complicated by preterm premature rupture of the membranes. *Am J Obstet Gynecol* 1993;168:1467-73.
11. Kenyon SL, Taylor DJ, Tarnow-Mordi W; ORACLE Collaborative Group. Broad-spectrum antibiotics for preterm, prelabour rupture of fetal membranes: the ORACLE I randomised trial. ORACLE Collaborative Group. *Lancet* 2001;357:979-88.
12. Kenyon S, Boulvain M, Neilson JP. Antibiotics for preterm rupture of membranes. *Cochrane Database Syst Rev* 2010;CD001058.
13. Arias F. Delayed delivery of multifetal pregnancies with premature rupture of membranes in the second trimester. *Am J Obstet Gynecol* 1994;170:1233-7.
14. Keselman L, Perlitz Y, Younis J, Ben-Ami M. Nonconventional approach to twin pregnancies complicated by extremely preterm premature rupture of membranes of one twin. *Am J Perinatol* 2008;25:161-2.