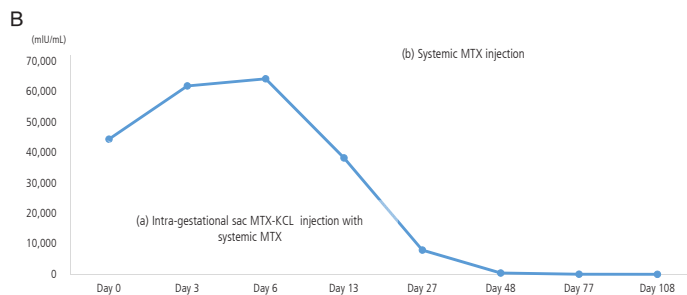
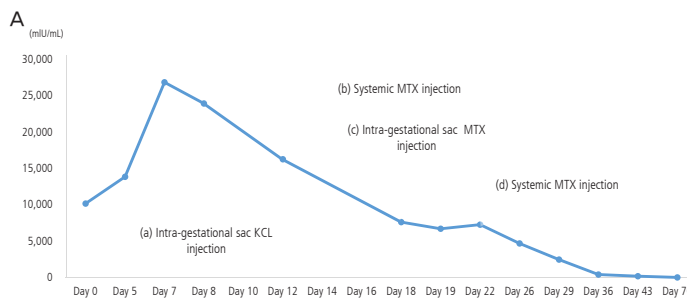


## Figure Correction

In the published article by Lee JH et al. entitled "Concomitant ultrasound-guided intra-gestational sac methotrexate-potassium chloride and systemic methotrexate injection in the recurrent cesarean scar pregnancy" (Obstet Gynecol Sci 2016;59(3):245-248. doi: <http://dx.doi.org/10.5468/ogs.2016.59.3.245>), the Figure 2 is given incorrectly. The Editorial Office would like to correct the Figure 2 and apologizes for any inconvenience that it may have caused.



The Figure 2 should be corrected as follows.

