

Case Report

Grain founder in a male camel (*Camelus dromedarius*)

Narendra K. Sharma*, Sunanda Sharma

Animal Husbandry Department, Veterinary Hospital, Jetpur, Bikaner-334001 (Rajasthan), India

A rare case of laminitis was recorded in an adult camel that was kept in confinement without giving any exercise and fed daily with considerable quantity of pearl millet grains (*Pennisetum typhoideus*) for more than five months.

Key words: *Camelus dromedarius*, grain founder, laminitis

Laminitis, which results into severe lameness, has been reported commonly in equine, bovine, caprine, and porcine [2,4]. There isn't any report on laminitis in dromedary. This paper reports on the case of laminitis in a male camel, which was confined in stall and fed daily with pearl millet grains (*Pennisetum typhoideus*).

About six year old medium sized male camel was presented at the hospital for treatment of severe lameness. On clinical examination enormous onyx enlargement was observed in both forelimbs (Fig. 1, 2 and 3.), and left hind limb (Fig. 4.) but onyx of right hindlimb was normal. The digital veins of affected limbs were engorged (Fig. 2, 3 and 4). On progression animal was walking with short strides and putting weight on heels with leaning on left side.

The onyx of left forelimb turned from anterior border of toe towards ventro-caudal direction and occupied 1/4th of cranial solar surface (Fig. 1 and 2.); in right forelimb it turned from cranial border toward ventro-medial direction (Fig. 3), whereas, in left hindlimb the onyx growth from cranial border was turning towards ventral direction (Fig. 4.). Anamnesis revealed that due to scarcity of roughage during the famine period, the animal was kept under confinement and fed with pearl millet grains without the roughage as daily ration for more than five months.

The animal was sedated with xylazine (0.1 mg/kg, IM) and restrained in lateral recumbancy. The onyxes were trimmed at the level of cranial border of the toe. The pain was not resolved even at 24 hrs. after the nail trimming. Non steroid anti inflammatory drug, phenylbutazone sodium (5 mg/kg, IM) was administered for 7 days and feeding

schedule was changed to incorporate the roughage in daily ration of the animal. Though continuous improvement in gait was observed on consecutive days but the draught capability of the animal was re-attained after about ten days.

Onyx enlargement is a common feature in canine and felines that warrants trimming at regular interval. Enormous hoof enlargement in bovine, caprine, equine and porcine species has been reported due to laminitis [1,3,4]. Present findings resembles the grain founders in bovine and equine

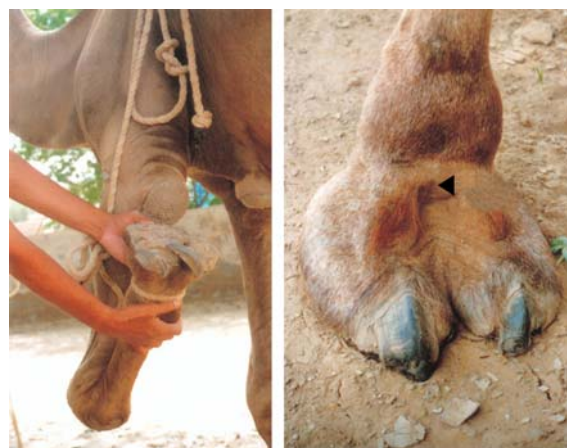

Fig. 1. Left forelimb (Palmer view). **Fig. 2.** Left forelimb (Dorsal view).

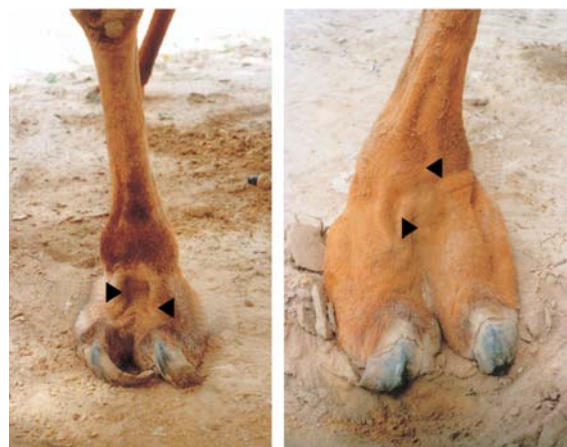


Fig. 3. Right forelimb.

Fig. 4. Left hindlimb.

*Corresponding author

Tel: +91-151-2529201, Fax: +91-151-22084094

E-mail: naren21761@sancharnet.in, naren 21761@hotmail.com

where eating of considerable quantities of grains as a daily ration alters the bacterial balance resulting in increased lactic acid producing bacteria, primarily lactobacillus and streptococcus. The lactic acidosis even in mild form may be a major factor in the development of acute laminitis [6]. The increased lactic acid and decreased pH causes lyses of cell wall of Gram-negative bacteria with resultant release of endotoxins, these events ultimately contribute to the onset of laminitis [4]. In present case enlarged onyces and engorged digital veins were similar to elongated hooves, engorgement of digital veins and walking with short strides as reported in the early stages of bovine and equine laminitis [2,4]. Non-steroid anti-inflammatory drugs administered at early stage of laminitis have been reported to resolve the condition [4], similar results were observed in present case. Rotation of distal phalanx associated with chronic laminitis in bovine [2,5] and equine [4] was not found in present case probably

due to earlier detection and therapeutic measures taken for resolving the lameness.

References

1. **Frank ER.** Veterinary Surgery. 1st Indian ed. pp. 211-212, CBS Publishers & Distributors, Delhi, 1981
2. **Greenough PR, MacCallum FJ, Weaver AD.** Lameness in Cattle. 2nd ed. pp. 219-227, John Wright & Sons, Bristol, 1981.
3. **Oehme FW, Prier JE.** Text Book of Large Animal Surgery. pp. 205-208, Williams & Wilkins, Baltimore, 1974.
4. **Stashak TS.** Adam's Lameness in Horses. 4th ed. pp. 486-498, Lea & Febiger, Philadelphia, 1987.
5. **Tyagi RPS, Singh J.** Ruminant Surgery. pp. 163-164, CBS Publishers and Distributors, Delhi, 1993.
6. **Weaver AD.** The prevention of bovine laminitis. Bovine Pract 1979, **15**, 70.