

Case Report

Surgical removal of stones in the stomach of a tiger shovelnose catfish

Hun-Young Yoon¹, Soon-Wuk Jeong^{1*}, Young-Min Choi², Man-bok Jeong¹, Joon-Young Kim¹, Hyun-Jung Han¹, Min-Hwang¹, Byung-Kuk No¹, Sang-Hyuk Park¹

¹Department of Veterinary Surgery, College of Veterinary Medicine, Konkuk University, Seoul 143-701, Korea

²Dae-in Animal Clinic, Seoul 137-810, Korea

A seven months old, tiger shovelnose catfish was referred to the veterinary medical teaching hospital of the college of veterinary medicine, Konkuk university because of suspecting a foreign body in the stomach. By physical and radiologic examinations, the catfish revealed abdominal enlargement, vomiting, inactivity and radiopaque foreign bodies in the stomach. Under general anesthesia with dilute isoflurane solution, celiotomy was performed. Stomach was atonic, and three foreign bodies were palpated in the stomach. In this process, three stones came out through mouth. Abdominal muscles were closed with a simple continuous suture pattern, and skin was closed with a simple mattress suture pattern. Sutured site was covered with glue and mucous taken from allogenic skin. On the second day after surgery, the patient recovered to normal condition, showing increased appetite and activity.

Key words: Foreign body, stomach, tiger shovelnose catfish, celiotomy

There are catfishes that swallow stones on making a nest by mistake in spawning period, or catfishes swallow stones habitually because they are omnivorous [6]. Furthermore, it often happens because catfishes live on the bottom of water [6].

In differing from canine, catfishes easily vomit, but sometimes catfish eat too many stones to vomit, or too large stone to vomit. In that case, as time goes on, stomach becomes atonic, and it is harder to vomit stones. Gastrotomy must be taken to remove stones for this case.

Also in the case of swallowing a sharp foreign body such as a fishing hook, surgery must be chosen to remove a foreign body.

History and Physical findings

A seven months old, tiger shovelnose catfish was referred

to the veterinary medical teaching hospital of the college of veterinary medicine of Konkuk university, because of suspecting a foreign body in stomach. The catfish had a history of anorexia, depression for 15 days, which of those has been getting worse since three days ago. On observing the fish in vat, the fish vomited a mudfish. In physical examination, eyes looked dull, and activity of swimming was very depressed and abdomen was enlarged (Fig. 1). Intermittently, the fish showed flinch of cranial abdomen, which looked painful.

Radiological findings

Dorsoventral radiographic view of abdomen revealed three foreign bodies in stomach that were suspected as stones (Fig. 2a). One of those was round, and the others were narrow and angled. Round thing looked to be in inner part in section of swim bladder margin, and the others looked to be in outer part in section of swim bladder margin. However, only one of narrow and angled foreign bodies looked to be in outer part in section of swim bladder margin in left lateral view (Fig. 2b). Cranial two foreign bodies pressed liver cranioventrally in both dorsoventral and left lateral view, and caudal foreign body pressed spleen dorsally in both dorsoventral and left lateral view (Fig. 2).



Fig. 1. An enlarged abdomen silhouette.

*Corresponding author

Phone: 82-2-450-3670; Fax: 82-2-444-4396

E-mail: swjeong@konkuk.ac.kr

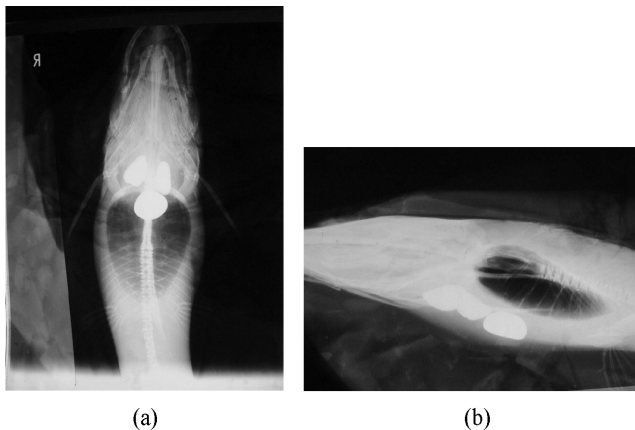


Fig. 2. Radiologic features before operation. Three foreign bodies are shown in both dorsoventral (a) and lateral views (b), and placed in ventral part of the spleen and dorsal part of the liver.

Surgical treatment and findings

Anesthesia: Before surgery, oxygen was given (8.4 mg/kg) to patient, and water in vat was warmed by heater at 24°C temperature for stabilizing and increasing immune function [2,4]. Anesthesia was induced in large vat of water. Isoflurane was used at a rate of 2.5 ml in one gallon of water [1,3]. After induction, the patient was weighed (570 g). Once the fish was induced, it was transferred to the table, where three tubes for maintaining anesthesia were placed in both mouth and gills. The water with isoflurane used in induction anesthesia was also used in maintaining anesthesia with diluting to one ml isoflurane per gallon of water with isoflurane and was pumped up from the vat to the fish's oral cavity, over the gills and backed through the tabletop to the bucket again [1,3]. This process was repeated during anesthesia.

Operation: The patient was placed on a fish surgery table that had a draining hole to bucket and positioned in dorsal recumbency. Wet clothes were placed in the both sides to keep the skin moisten. Water was poured over wet clothes, skin, and surface. A cup was used to pour water over the upper gill arch which was sometimes hard to keep wet. Three tubes for maintaining anesthesia were placed in its mouth and gills. The water with isoflurane was pumped up from the vat to the oral cavity, and over the gill. Incision was performed through a ventral midline. Incision was made from 10 cm anterior to the anal opening, extending forward to the level required for visualization. After initial skin and muscle incision were made, connective tissues were gently opened with blunt dissection.

Separating tissues created exposure of abdomen, and provided visualization of the liver, stomach and bowel. With manipulation the stomach and spleen were located and exteriorized. Three separated hard masses were touched by fingers. When the stomach was manipulated to find incision site, it was felt that three masses were getting out of stomach



Fig. 3. After celiotomy, stomach is manipulated by Addison tissue forceps.



Fig. 4. Enlarged abdomen silhouette is disappeared after operation.

(Fig. 3). Three stones were found in mouth and removed. Muscles were sutured with 5-0 safil® (polyglycolic acid) by a simple interrupted pattern, and skin was sutured with 5-0 dafilon® (polyamide thread) by a simple horizontal mattress pattern [4]. It took about 30 minutes from anesthesia to skin closure. Incision line was sealed against water ingress with cyanomethacrylate (super glue®), which prevents belly from infection. After sealing, incision line was covered with mucus taken from allogenic skin to reinforce the function of water proof and to prevent infection.

Postoperative care and evaluation

The patient was monitored postoperatively for awakening from anesthesia, and gastrointestinal track function with patients motion (activity, respiration, vomiting, abdominal pain) in recovering vat in which oxygen was provided for 1 day and water was warmed by heater at 24°C. Antibiotic (enrofloxacin, Bayer, 2.5 mg/kg, I.M. q24) was administered for ten days [1,5]. Day two morning, activity was increased, and enlarged abdomen silhouette is disappeared (Fig. 4). Day two evening, no more painful action was found, so that mudfish was given and appetite was good. Day three, the patient did not vomit mudfish and activity was much better. Day ten, we could not find any more clinical sings.

Some catfishes have a habit of swallowing stones, or they swallow stones by mistakes to carry stones used for oviposition period [6]. In addition, because they live on the

bottom of water, they have more chances to face stones [6]. Generally, catfishes swallowing stones vomit them, and they do not have any clinical signs such as vomiting, anorexia, lethargy. However, some catfishes swallowing stones could die, showing vomiting, anorexia, inactivity, because they can not vomit stones. So, gastrotomy must be chosen to remove stone. In this case, the fish had not vomitted stones for 15 days, showing anorexia, vomiting, depression. So, gastrotomy was chosen to remove stones, however, stones came out through mouth only by manipulating stones. We need to consider that temporal irritation of stomach could be the way of removing foreign body, whether it is a mechanical way or increasing stomach activity.

References

1. **Carpenter JW.** Exotic Animal Formulary. 2nd ed. pp. 3-21, Saunders, Philadelphia, 2001.
2. **Edward JN.** Fish Disease. pp. 55-62, Mosby, St. Louis, 1996.
3. **Muir WW.** Handbook of Veterinary Anesthesia. 3rd ed. pp. 391-393, Mosby, St. Louis, 2000.
4. **Stoskopf MK.** Fish Medicine. pp. 79-97, Saunders, Philadelphia, 1993.
5. **Treves-Brown KM.** Applied Fish Pharmacology. pp. 137-138, Kluwer Academic Publishers, Amsterdam, 2000.
6. **Tucker CS.** Channel Catfish Culture. pp. 1-5. pp. 21-24, Elsevier Science Publishers, Amsterdam, 1985.