

## Original Article



# Evaluating traumatic brain injury using conventional magnetic resonance imaging and susceptibility-weighted imaging in dogs

Daji Noh <sup>1</sup>, Sooyoung Choi <sup>2</sup>, Hojung Choi<sup>3</sup>, Youngwon Lee<sup>3</sup>, Kija Lee <sup>1,\*</sup>

<sup>1</sup>College of Veterinary Medicine, Kyungpook National University, Daegu 41566, Korea

<sup>2</sup>College of Veterinary Medicine, Kangwon National University, Chuncheon 24341, Korea

<sup>3</sup>College of Veterinary Medicine, Chungnam National University, Daejeon 34134, Korea

## OPEN ACCESS

**Received:** Oct 5, 2018

**Revised:** Dec 10, 2018

**Accepted:** Jan 25, 2019

### \*Corresponding author:

Kija Lee

College of Veterinary Medicine, Kyungpook National University, 80 Daehak-ro, Buk-gu, Daegu 41566, Korea.

E-mail: leekj@knu.ac.kr


© 2019 The Korean Society of Veterinary Science

This is an Open Access article distributed under the terms of the Creative Commons Attribution Non-Commercial License (<https://creativecommons.org/licenses/by-nc/4.0>) which permits unrestricted non-commercial use, distribution, and reproduction in any medium, provided the original work is properly cited.

### ORCID iDs

Daji Noh 

<https://orcid.org/0000-0002-1447-2194>

Sooyoung Choi 

<https://orcid.org/0000-0002-7973-4714>

Kija Lee 

<https://orcid.org/0000-0002-4649-809X>

### Conflict of Interest

The authors declare no conflicts of interest.

### Author Contributions

Conceptualization: Noh D, Choi S, Lee K; Data curation: Choi S, Lee K; Formal analysis: Noh D; Investigation: Noh D; Methodology: Noh D, Lee K; Supervision: Choi S, Choi H, Lee Y, Lee K; Validation: Noh D, Choi S, Choi H, Lee Y, Lee K; Writing - original draft: Noh D; Writing - review & editing: Lee K.

## ABSTRACT

Susceptibility-weighted imaging (SWI) is a magnetic resonance imaging (MRI) sequence used for evaluating traumatic brain injury (TBI). Although SWI is being increasingly used in veterinary medicine, there are no systematic studies regarding its use. We aimed to evaluate TBI lesions by using conventional MRI and SWI in 11 dogs and determine the correlation between clinical status and conventional MRI or SWI findings. The modified Glasgow coma scale (MGCS) at presentation and a previously used MRI grading system (MRGr; grades 1–6) were used to evaluate the brain lesions, and correlations between MGCS score and each MRGr were assessed. Conventional MRI revealed 23 lesions in 11 dogs with variable MGCS scores (range: 11–17). SWI showed comparable findings for all of the lesions except for subdural hemorrhage, and it revealed additional lesions in four dogs. The median MRGr was 2 on both conventional MRI and SWI. The MRGr of the conventional MRI assessments and the MGCS scores showed a significant negative correlation ( $r = -0.685$ ). In conclusion, SWI had better TBI lesion-detection ability, but conventional MRI had a better correlation with early clinical status and subdural hemorrhage. Thus, a combination of conventional MRI and SWI examinations can improve TBI diagnosis in dogs.

**Keywords:** Dogs; magnetic resonance imaging; susceptibility-weighted imaging; brain injuries; traumatic brain injury

## INTRODUCTION

Traumatic brain injury (TBI) is one of the most common neurological conditions and is associated with mortality in dogs [1-6]. Since accurate assessment of TBI patient can facilitate appropriate treatment and yield better outcomes with prognostic information, various clinical assessment methods for TBI have been studied in humans and dogs [1,3,7-15]. Diagnostic imaging modalities such as computed tomography (CT) and magnetic resonance imaging (MRI) are widely used in TBI patients because they can identify treatable injuries to prevent secondary damage and provide useful prognostic information [1,2,7,8,11,15,16]. In human medicine, CT is the modality of initial choice for acute TBI patients because it is a rapid, widely available, and highly accurate method for the detection of intracranial hemorrhage or skull fracture [7,8,10-12]. However, in the subacute and chronic phase of TBI, MRI is preferred over CT because of its superiority in detecting non-hemorrhagic lesions, brainstem injury, edema, and diffuse axonal injury [7,8,10,11,16].

Susceptibility-weighted imaging (SWI), a relatively new MRI sequence, has recently gained prominence due to the increasing need for accurate diagnosis in TBI patients. Previous studies have reported that this new sequence type is more sensitive in detecting traumatic lesions than CT or conventional MRI, especially in cases involving cerebral microbleeds [7,10,12,14,16]. In veterinary medicine, there is a study elucidating the correlation between conventional MRI results and clinical status or prognosis in dogs with TBI [1]. However, to the best of the authors' knowledge, there are no reports on the use of SWI in dogs with TBI or on comparisons of conventional MRI and SWI, even though the use of SWI has been apparently increasing. The aims of this study were 1) to describe conventional MRI and SWI results for TBI lesion evaluation, and 2) to determine correlations between clinical status and conventional MRI or SWI results. Consequently, our study aimed to identify the appropriate MRI sequences to use in the assessment of dogs with TBI.

## MATERIALS AND METHODS

The medical records of all dogs presenting between April 2013 and May 2015 were reviewed. Inclusion criteria were as follows: 1) TBI based on clinical history, 2) no known history of intracranial central nervous system disease unrelated to the TBI, 3) was presented at the animal clinic center within 24 h of TBI, 4) Modified Glasgow coma scale (MGCS) score [5] recorded at presentation, 5) hospitalized for at least 3 days after the TBI, 6) 1.5 Tesla MRI performed in the first 5 days after TBI, and 7) at least four MRI sequences obtained, *i.e.*, T1-weighted (T1W), T2-weighted (T2W), fluid-attenuated inversion recovery (FLAIR), and SWI. All animals were treated with a general treatment protocol in accordance with ethical requirements.

MRI scans were performed with a 1.5-Tesla magnet (Siemens, Germany). For MRI examinations, anesthesia was induced in each patient with intravenous propofol (Myungmoon Pharm. Co., Korea) at a dose of 8 mg/kg body weight and maintained with isoflurane (Hana Pharm. Co., Korea) and oxygen. An extremity matrix coil was used, and the patients were placed in ventral recumbency. The T1W, T2W, FLAIR, and SWI sequences were acquired in transverse planes on each patient (**Table 1**).

All images included in this study were uploaded to a DICOM-viewing station (Infinit Healthco., Korea). Location, intensity of the lesion on T1W, T2W, and FLAIR, existence of median shift, and skull fracture were assessed by two clinicians experienced in veterinary diagnostic imaging (D. Noh and K. Lee) on the basis of consensus. Lesion locations were categorized as 1) subdural; 2) frontal, temporal, parietal, or occipital lobe; 3) thalamus; 4) cerebellum; and 5) brainstem. Signal intensity in comparison to the adjacent brain tissue was evaluated as hypointense, isointense, or hyperintense on T1W, T2W, and FLAIR, respectively.

**Table 1.** Imaging parameters of the magnetic resonance imaging sequences

Parameters	T1W	T2W	FLAIR	SWI
TR/TE	450/15	4000–5000/77	7000–8000/87	50/40
Flip angle (°)	90	150	150	15
Section thickness (mm)	2.5–3.0	2.5–3.0	2.5–3.0	1.6
Slice gap (mm)	0.25–0.9	0.25–0.9	0.25–0.9	0

T1W, T1-weighted; T2W, T2-weighted; FLAIR, fluid-attenuated inversion recovery; SWI, susceptibility-weighted imaging; TR, time to repeat; TE, time to echo.

All lesions detected on conventional MRI and SWI were evaluated based on a previously reported modified MRI grading system (MRGr; Grade 1, normal brain parenchyma; Grade 2, lesions only affect the cerebral hemisphere, cerebellar parenchyma, or both without median shift; Grade 3, same as Grade 2 but with median shift; Grade 4, lesions affecting the corpus callosum, thalamus, or basal nuclei with or without lesions of a lower grade; Grade 5, unilateral brain lesions in the brainstem with or without lesions of a lower grade; Grade 6, bilateral brain lesions in the brainstem with or without lesions of a lower grade) [1,17].

Statistical analyses were performed using commercial software (IBM SPSS statistics, USA). Spearman correlation analysis was used to assess the correlation of MGCS with MRGr on conventional MRI, and MGCS with MRGr on SWI. The *p* values lower than 0.05 were considered statistically significant.

## RESULTS

Eleven dogs met the inclusion criteria. Patient history and signalment are summarized in **Table 2**. All dogs were small-breed, including seven Maltese and one each of Dachshund, Pomeranian, Toy Poodle, and Yorkshire terrier. The median age at presentation was 4 years (range, 1–7 years). The most common cause of TBI was a fall in five dogs, followed by blunt trauma in four dogs and motor vehicle accident in two dogs. The clinical signs were recumbency (*n* = 7), semicomatose condition (*n* = 5), seizure (*n* = 4), head tilt (*n* = 3), nystagmus (*n* = 3), circling (*n* = 2), ataxia (*n* = 1), and hemiparesis (*n* = 1). All dogs were hospitalized and received standard treatment to obtain stabilization after TBI. Follow-up assessments were performed by telephone for eight dogs. Seven dogs recovered over time and three showed full recovery on follow-up examinations (**Table 2**). Dogs with a higher MGCS score and a lower MRGr showed a tendency to recover quickly, while one dog with an MGCS score of 12 and MRGr 5 was euthanized because of its severe clinical signs.

Conventional MRI revealed 23 lesions in 11 dogs. The locations of the lesions are summarized in **Table 3**. On T2W, these lesions were hyperintense (21/23), isointense (1/23), and hypointense (1/23). On T1W, the lesions were hypointense (16/23), hypo- to isointense (5/23), and hyperintense (2/23). On FLAIR, the lesions were hyperintense (20/23), iso- to hyperintense (1/23), isointense (1/23), and hypointense (1/23). Three lesions showed a central lesion that was hypo- to isointense on T2W, hypointense (2/3) or hyperintense (1/3) on T1W,

**Table 2.** Signalment and information in 11 dogs with traumatic brain injury

No.	Breed/Sex/Age	Trauma	MGCS	Clinical signs	Follow-up (day)
1	Maltese/MC/4y	MVA	11	Recumbent, Nystagmus, Seizure, Semicomatose	Tetraparesis (3) Semicomatose (7)
2	Maltese/F/1y	Fall	16	Circling, Ataxia	Normal (7)
3	Maltese/F/2y	MVA	11	Recumbent, Semicomatose	No data
4	Y. Terrier/MC/3y	Fall	17	Hemiparesis	Normal (3)
5	Dachshund/MC/2y	BT	14	Recumbent, Nystagmus, Seizure	Hemiparesis (30)
6	Maltese/F/1y	BT	13	Recumbent, Seizure, Semicomatose	Hemiparesis (30)
7	Pomeranian/MC/6y	Fall	12	Recumbent, Head tilt, Nystagmus, Semicomatose	No data
8	Poodle/F/2y	Fall	17	Head tilt, Seizure	Normal (7)
9	Maltese/MC/2y	Fall	16	Head tilt, Circling	Head tilt (7)
10	Maltese/MC/5y	BT	15	Recumbent	No data
11	Maltese/FS/7y	BT	12	Recumbent, Semicomatose	Euthanized (7)

MGCS, Modified Glasgow coma scale; MC, castrated male; M, male; FS, spayed female; F, female; MVA, motor vehicle accident; BT, blunt trauma.

**Table 3.** Location of lesions and MRGr on conventional MRI and SWI in 11 dogs with traumatic brain injury

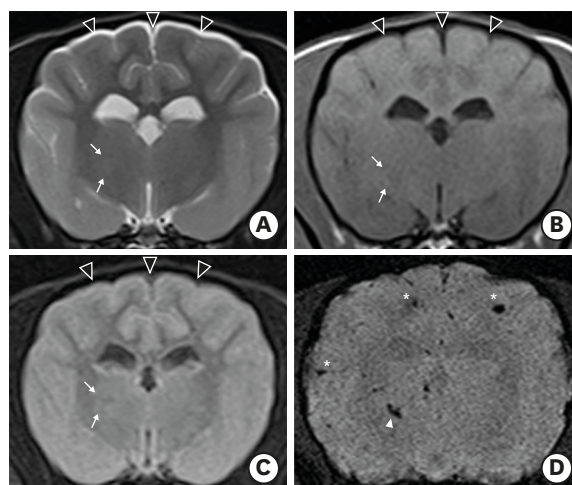
No.	MRI scan day	Conventional MRI		SWI	
		Location of lesions	MRGr	Location of additional lesions	MRGr
1*	2	R frontal, R temporal, R occipital	4	ND	4
2	1	R thalamus, Subdural	1	L caudate nucleus, R & L frontal, R & L parietal, R & L occipital, R & L temporal, R & L cerebellum	4
3†	1	R frontal, R temporal, R & L parietal	3	L internal capsule	4
4	1	R occipital	2	R cerebellum	2
5	4	L frontal, R & L cerebellum	2	ND	2
6	3	L frontal, L caudate nucleus	4	ND	4
7	1	L temporal	2	ND	2
8	1	L frontal	2	ND	2
9	2	L frontal	2	ND	2
10‡	1	R & L parietal	2	ND	2
11	1	R pons, R & L cerebellum	5	R occipital, L temporal	5

MRGr, MRI grading system; MRI, magnetic resonance imaging; SWI, susceptibility-weighted imaging; ND, not detected.

\*Temporal bone fracture was identified; †Frontal and parietal bone fracture was identified; ‡Parietal bone fracture was identified.

and hypo- to isointense on FLAIR. SWI showed comparable findings for all 23 lesions, but it also detected numerous additional lesions in four dogs (**Table 3**). In particular, in one dog, conventional MRI revealed only one ambiguous thalamic lesion whereas SWI showed multifocal lesions throughout the brain parenchyma, including the cerebral lobe, cerebellum, and caudate nucleus. However, subdural hemorrhage was only detected on conventional MRI, not on SWI (**Fig. 1**). Skull fractures were detected in three dogs (**Table 3**).

The median MRGr was 2 both on conventional MRI and SWI (range, 2–5; respectively). There was a significant negative correlation between MRGr on conventional MRI and MGCS score ( $r = -0.685$ ,  $p < 0.05$ ). However, there was no significant correlation between MRGr on SWI and MGCS score.



**Fig. 1.** T2W (A), T1W (B), FLAIR (C), and SWI (D) in Dog 2. The lesion on the right thalamus (arrows) appears ambiguous on conventional MRI (A, B, and C). On SWI (D), the same lesion is apparent (white arrowhead), and additional multiple brain punctate lesions (\*marking a representative lesion) can be detected. Subdural hemorrhage is detected on conventional MRI but not on SWI (black arrowheads).

## DISCUSSION

We described the use of conventional MRI and SWI for the evaluation of TBI lesions in dogs; this is the first veterinary study using SWI in dogs with TBI. According to previous MRI studies in humans, the T2W sequence can detect edema, contusions, and lesions near the skull base and at the under surface of the cerebral lobe [8,10]. It also can be used to estimate the age of hemorrhage although it shows low sensitivity for intraparenchymal hemorrhage [10]. FLAIR is superior to T2W for detection of periventricular and superficial cortical lesions and diffuse axonal injury, even though it requires a long acquisition time [8,10,11]. The T2<sup>\*</sup>-weighted gradient-echo MRI sequence can depict paramagnetic deoxyhemoglobin, methemoglobin, or hemosiderin in lesions and some calcifications. However, it cannot distinguish between hemorrhage and calcification [18]. In contrast to these scenarios, SWI, a fully velocity-compensated high-resolution three-dimensional gradient-echo sequence, allows improved detection of paramagnetic blood products, extravascular deoxyhemoglobin, and methemoglobin, based on differences in their magnetic susceptibility [8,12,16,18-20]. It can also distinguish a paramagnetic substance from calcification and aids in the detection of small brain parenchymal hemorrhage with a well visualized venous structure, showing higher detectability than that of T2<sup>\*</sup>-weighted gradient-echo sequences [4,10,12,18,21]. Because of its characteristics, SWI has been used widely in human clinical assessments involving head trauma patients.

In this study, similar to the findings in human patients, SWI showed a superior ability to detect brain parenchymal TBI lesions with more clarity and less ambiguous aspects than that from conventional MRI. The detection of lesions only on SWI may be attributable to the above-mentioned superiority of SWI for detecting small brain parenchymal hemorrhage, which is categorized as a punctate hemorrhagic lesion (< 10 mm) in human patients, and it may indicate the presence of axonal injury [10,12,21]. Furthermore, one dog with only one ambiguous thalamic lesion on conventional MRI showed multifocal lesions throughout the brain parenchyma on SWI. This result may further indicate the usefulness of SWI in dogs with TBI, especially in cases that are unexplainable on conventional MRI.

Even though the SWI is purported to be the most sensitive sequence for detecting hemorrhagic lesions, subdural hemorrhage was only detected on conventional MRI, not on SWI [10]. The subdural region is the narrow space interposed between the arachnoid and pia mater and adjacent to skull bone. Because of its anatomical structure, this region may show magnetic susceptibility artifacts due to the skull base–air interface on SWI, resulting in an undetected lesion. However, on conventional MRI, the presence of this anatomical structure may not affect the detection due to the superior ability of this technique to distinguish lesion from bone. This assumption is consistent with that in previous human study that showed the ability of T2W to detect lesions near the skull base [8,10]. That study was also in agreement with an earlier study that showed better detection of central brain areas than peripheral brain areas on SWI [22]. These results support the necessity and superiority of conventional MRI in cases of TBI patients with subdural hemorrhage.

In this study, the MRGr for conventional MRI was negatively correlated with MGCS scores, and dogs with a lower MRGr tended to recover quickly. The MGCS, which evaluates clinical status, including motor activity, brainstem reflexes, and consciousness, has served as a useful prognostic index for dogs with TBI [1,3,5]. Although the Glasgow coma outcome scale was not analyzed in our study, the results suggest that conventional MRI could be

used for predicting a prognosis, which is in agreement with other reports in dogs and humans [1]. However, there was no correlation between the MRGr on SWI and MGCS score. There are several possible reasons for this result: 1) Early clinical status was unaffected by the additionally detected small lesions, 2) MRGr was an incongruent method to adjust on SWI, and 3) only a small number of dogs with a narrow range of MRGr were included in this study. Previous human studies have shown a correlation between Glasgow coma scale scores and SWI findings by using the number of punctate lesions on SWI [10,14]. This implies that SWI can reflect the early clinical status whereas our results could not. Our result may be attributed to the narrow range within the MRGr, even though it has been used as an evaluation method for head injury. We also could not exclude the possibility that the MRGr may not be an appropriate method for evaluating punctate lesions. To elucidate a possible correlation between clinical status and SWI findings, further studies using variable methods and a large number of dogs are needed.

This study showed the superiority of SWI in detecting brain parenchymal TBI lesions, even though the clinical relevance of SWI was debatable. Nevertheless, SWI was still thought to play a meaningful role in predicting a prognosis because of its superior lesion-detection ability. Several studies have shown that the actual lesion site has prognostic value in TBI, especially for lesions in the brainstem, frontal lobe, temporal lobe, basal ganglia, and corpus callosum [7,8,12,23]. Since the additional lesions detected on SWI in this study were present in these sites, except the corpus callosum, SWI is thought to also have prognostic value and should be considered useful in dogs with TBI.

In summary, this is the first report describing the use of conventional MRI and SWI for the evaluation of TBI lesions in dogs. While the severity of early clinical status was not correlated with SWI results, this type of sequence showed superior ability to detect brain parenchymal TBI lesions in comparison with that of conventional MRI. Because of its characteristics, SWI provides valuable diagnostic information in dogs with TBI, especially in cases that are unexplainable by conventional MRI results. However, conventional MRI also shows superiority for detecting peripheral brain hemorrhage, and its correlation with early clinical signs can help in prognosis prediction. Therefore, examinations that combine conventional MRI and SWI are suggested for dogs with TBI.

## REFERENCES

1. Beltran E, Platt SR, McConnell JF, Dennis R, Keys DA, De Risio L. Prognostic value of early magnetic resonance imaging in dogs after traumatic brain injury: 50 cases. *J Vet Intern Med* 2014;28:1256-1262. [PUBMED](#) | [CROSSREF](#)
2. Platt S, Freeman C, Beltran E. Canine head trauma: an update. *In Pract* 2016;38:3-8. [CROSSREF](#)
3. Platt SR, Radaelli ST, McDonnell JJ. The prognostic value of the modified Glasgow Coma Scale in head trauma in dogs. *J Vet Intern Med* 2001;15:581-584. [PUBMED](#) | [CROSSREF](#)
4. Shams S, Martola J, Cavallin L, Granberg T, Shams M, Aspelin P, Wahlund LO, Kristoffersen-Wiberg M. SWI or T2\*: which MRI sequence to use in the detection of cerebral microbleeds? The Karolinska Imaging Dementia Study. *AJNR Am J Neuroradiol* 2015;36:1089-1095. [PUBMED](#) | [CROSSREF](#)
5. Shores A. Craniocerebral trauma. In: Kirk RW, editor. *Current Veterinary Therapy X*. Philadelphia, PA: WB Saunders; 1983, 847-854.



6. Simpson SA, Syring R, Otto CM. Severe blunt trauma in dogs: 235 cases (1997–2003). *J Vet Emerg Crit Care (San Antonio)* 2009;19:588-602.  
[PUBMED](#) | [CROSSREF](#)
7. Beauchamp MH, Ditchfield M, Babl FE, Kean M, Catroppa C, Yeates KO, Anderson V. Detecting traumatic brain lesions in children: CT versus MRI versus susceptibility weighted imaging (SWI). *J Neurotrauma* 2011;28:915-927.  
[PUBMED](#) | [CROSSREF](#)
8. Chastain CA, Oyoyo UE, Zipperman M, Joo E, Ashwal S, Shutter LA, Tong KA. Predicting outcomes of traumatic brain injury by imaging modality and injury distribution. *J Neurotrauma* 2009;26:1183-1196.  
[PUBMED](#) | [CROSSREF](#)
9. Cremer OL, Moons KG, van Dijk GW, van Balen P, Kalkman CJ. Prognosis following severe head injury: development and validation of a model for prediction of death, disability, and functional recovery. *J Trauma* 2006;61:1484-1491.  
[PUBMED](#) | [CROSSREF](#)
10. Geurts BH, Andriessen TM, Goraj BM, Vos PE. The reliability of magnetic resonance imaging in traumatic brain injury lesion detection. *Brain Inj* 2012;26:1439-1450.  
[PUBMED](#) | [CROSSREF](#)
11. Le TH, Gean AD. Neuroimaging of traumatic brain injury. *Mt Sinai J Med* 2009;76:145-162.  
[PUBMED](#) | [CROSSREF](#)
12. Mittal S, Wu Z, Neelavalli J, Haacke EM. Susceptibility-weighted imaging: technical aspects and clinical applications, part 2. *AJNR Am J Neuroradiol* 2009;30:232-252.  
[PUBMED](#) | [CROSSREF](#)
13. Pace MC, Ciccirella G, Barbato E, Maisto M, Passavanti MB, Gazzerri G, Barbarisi M, Aurilio C. Severe traumatic brain injury: management and prognosis. *Minerva Anestesiol* 2006;72:235-242.  
[PUBMED](#)
14. Park JH, Park SW, Kang SH, Nam TK, Min BK, Hwang SN. Detection of traumatic cerebral microbleeds by susceptibility-weighted image of MRI. *J Korean Neurosurg Soc* 2009;46:365-369.  
[PUBMED](#) | [CROSSREF](#)
15. Tamura S, Tamura Y, Tsuka T, Uchida K. Sequential magnetic resonance imaging of an intracranial hematoma in a dog. *Vet Radiol Ultrasound* 2006;47:142-144.  
[PUBMED](#) | [CROSSREF](#)
16. Thomas B, Somasundaram S, Thamburaj K, Kesavadas C, Gupta AK, Bodhey NK, Kapilamoorthy TR. Clinical applications of susceptibility weighted MR imaging of the brain - a pictorial review. *Neuroradiology* 2008;50:105-116.  
[PUBMED](#) | [CROSSREF](#)
17. Firsching R, Woischneck D, Klein S, Reissberg S, Döhring W, Peters B. Classification of severe head injury based on magnetic resonance imaging. *Acta Neurochir (Wien)* 2001;143:263-271.  
[PUBMED](#) | [CROSSREF](#)
18. Chavhan GB, Babyn PS, Thomas B, Shroff MM, Haacke EM. Principles, techniques, and applications of T2\*-based MR imaging and its special applications. *Radiographics* 2009;29:1433-1449.  
[PUBMED](#) | [CROSSREF](#)
19. Haacke EM, Xu Y, Cheng YC, Reichenbach JR. Susceptibility weighted imaging (SWI). *Magn Reson Med* 2004;52:612-618.  
[PUBMED](#) | [CROSSREF](#)
20. Tong KA, Ashwal S, Obenaus A, Nickerson JP, Kido D, Haacke EM. Susceptibility-weighted MR imaging: a review of clinical applications in children. *AJNR Am J Neuroradiol* 2008;29:9-17.  
[PUBMED](#) | [CROSSREF](#)
21. Tao JJ, Zhang WJ, Wang D, Jiang CJ, Wang H, Li W, Ji WY, Wang Q. Susceptibility weighted imaging in the evaluation of hemorrhagic diffuse axonal injury. *Neural Regen Res* 2015;10:1879-1881.  
[PUBMED](#) | [CROSSREF](#)
22. Verma RK, Kottke R, Anderegg L, Weisstanner C, Zubler C, Gralla J, Kiefer C, Slotboom J, Wiest R, Schroth G, Ozdoba C, El-Koussy M. Detecting subarachnoid hemorrhage: comparison of combined FLAIR/SWI versus CT. *Eur J Radiol* 2013;82:1539-1545.  
[PUBMED](#) | [CROSSREF](#)
23. Hoelper BM, Soldner F, Choné L, Wallenfang T. Effect of intracerebral lesions detected in early MRI on outcome after acute brain injury. *Acta Neurochir Suppl (Wien)* 2000;76:265-267.  
[PUBMED](#)