



Cytoplasmic Anti-Neutrophil Cytoplasmic Antibody Positive Diffuse Alveolar Hemorrhage Associated with Methimazole

Han Seok Ryu¹, Joo Hun Park¹, Seung Soo Sheen¹, Tae Hwan Kim¹, Sung Dam Han¹, Ju-Yang Jung², Chang-Hee Suh², Sung Chul Hwang¹

Departments of ¹Pulmonary and Critical Care Medicine, and ²Rheumatology, Ajou University School of Medicine, Suwon, Korea

Diffuse alveolar hemorrhage (DAH) is a life-threatening condition associated with many disorders. Here, we report a case of 59-year-old female who had diffuse alveolar hemorrhage associated with methimazole. She had been treated with methimazole for two weeks due to the recurrence of Grave's disease, before visiting the emergency room. She had to be intubated on the 3rd day of hospitalization because of unabated massive hemoptysis and rapid progression of diffuse alveolar infiltration on chest radiographs. Since her clinical condition improved substantially after cessation of methimazole and steroid pulse therapy, she was extubated on the 9th day of hospitalization and then discharged. After discharge, DAH did not recur with cessation of steroid and she had radioactive iodine therapy for her Grave's disease. This was a rare and interesting case of life-threatening DAH associated with cytoplasmic-antineutrophil cytoplasmic antibody and methimazole. (*J Rheum Dis* 2017;24:236-240)

Key Words. Diffuse alveolar hemorrhage, Methimazole, Antineutrophil cytoplasmic antibody

INTRODUCTION

Diffuse alveolar hemorrhage (DAH) is an unusual lethal condition characterized by anemia, hemoptysis, acute respiratory failure, and diffuse alveolar infiltrates on chest radiographs [1-4]. DAH is caused by various groups of heterogeneous disorders including autoimmune diseases, pulmonary infections, cardiac disorders, malignancy, etc. [1,4,5]. DAH due to methimazole is a rare occurrence, although propylthiouracil has been reported to induce DAH [6,7]. According to Gunton et al.'s [7] report, anti-neutrophil cytoplasmic antibody (ANCA)-positive vasculitis occurred in 15% to 37% of patients on propylthiouracil and only 0% to 3% of patients on methimazole developed ANCA-positive vasculitis. Since we recently experienced a patient of DAH associated with methimazole, we report here the presentation and our management of this case.

CASE REPORT

Clinical history

A 59-year-old female patient visited the emergency department of Ajou University Hospital, presenting with massive hemoptysis. Fever and respiratory symptoms such as cough and sputum started 2 days before emergency room visit and dyspnea began 1 day prior to emergency room visit. She had been diagnosed with Grave's disease seven years ago. She stopped anti-thyroid medication for three years because her thyroid function had normalized. One year ago, she started being treated with propylthiouracil again due to the recurrence of Grave's disease. However, anti-thyroid therapy was changed to methimazole because pancytopenia developed after propylthiouracil treatment for five months. She had been treated with methimazole for the previous two weeks before visiting our emergency room.

Received : October 6, 2016, **Revised :** (1st) December 5, 2016, (2nd) December 21, 2016, **Accepted :** December 24, 2016

Corresponding to : Joo Hun Park, Department of Pulmonary and Critical Care Medicine, Ajou University School of Medicine, 164 WorldCup-ro, Yeongtong-gu, Suwon 16499, Korea. E-mail : jhpamc@hanmail.net

Copyright © 2017 by The Korean College of Rheumatology. All rights reserved.

This is a Open Access article, which permits unrestricted non-commercial use, distribution, and reproduction in any medium, provided the original work is properly cited.

Physical examination

She appeared acutely ill. Her temperature was 36.7°C, the blood pressure 113/72 mmHg, the pulse rate 105 beats per minute, and the respiratory rate 26 breaths per minute. Inspiratory crackles were audible on chest physical examination. The skin was pale, warm, and dry. The abdomen was soft and nontender, and the remainder of the examination was normal.

Laboratory data

Initial laboratory investigation showed anemia with hemoglobin 7.0 g/dL (normal range, 10.7~15.3 g/dL), but the counts for white blood cells (9,900/mm³) and platelets (321,000/mm³) were normal. C-reactive protein (10.04 mg/dL; normal range, 0.00~0.30 mg/dL) was higher and coagulation tests such as prothrombin time (12.5 sec; normal range, 9.0~12.0 sec), activated partial thromboplastin time (27 sec; normal range, 27~40 sec) were normal. Renal function tests (serum BUN 13.2 mg/dL and serum creatinine 0.6 mg/dL) and hepatic function tests (serum albumin 3.9 g/dL, total bilirubin 1.4 mg/dL, aspartate transaminase 30 U/L, alanine transaminase 19 U/L) were normal. Serum electrolytes (serum sodium 135 mMol/L, serum potassium 3.5 mMol/L, serum calcium 8.2 mg/dL) were within normal range. Pro-brain natriuretic peptide was 339 pg/mL (normal range, 0~263 pg/mL). Thyroid function tests showed that T3 was 86.3 ng/dL (normal range, 60.0~181.0 ng/dL), Free T4 was 0.87 ng/dL (normal range, 0.89~1.76 ng/dL), and TSH was less than 0.008 uIU/mL (normal range, 0.55~4.78 ng/dL). Arterial blood gas analysis of the patient breathing ambient air showed severe hypoxemia (pO₂ 55.5 mmHg and O₂ saturation 92.0%) and respiratory alkalosis (pH 7.499, pCO₂ 23.5 mmHg, and HCO₃⁻ 21.7 mEq/L).

No bacteria were grown on initial blood culture and sputum culture. Antimicrobial serologic tests including serum anti-Leptospiral immunoglobulin G, serum anti-Rickettsia immunoglobulin G, serum anti-Mycoplasma immunoglobulin M and urinary streptococcus pneumonia antigen were all negative.

Autoimmune disease markers showed that cytoplasmic-anti-neutrophil cytoplasmic antibody (C-ANCA, proteinase [PR]3 Ab) was positive (1.8AI, normal range <1.0 antibody index) in fluorescence immunoassay, perinuclear ANCA (P-ANCA, myeloperoxidase [MPO] Ab) negative (0.4AI, normal range <1.0 antibody index), rheumatoid factor 15.1 U/mL (normal range, 0~15 U/mL), and anti-nuclear antibody positive (homogenous type, 1:160 positive). All ENA panels such as anti-ribonucleoprotein, anti-Sm, anti-Ro(SSA), anti-La(SSB), anti-double strand (ds)-DNA (<3 IU/mL; normal range, 0~7 IU/mL) were negative. C-ANCA test performed 5 months later came back negative. Serum complement 3 level was 76 mg/dL (normal range, 90~180 mg/dL) and serum complement 4 level was 16 mg/dL (normal range, 9~37 mg/dL). Diffuse consolidation and ground glass opacity were found in both lungs on her initial chest radiography (Figure 1). Urinalysis showed normal pH (6.0; normal range, 5.0~8.0), no proteinuria, glycosuria (3+), no hematuria (red blood cells 0/hpf), no pyuria (white blood cell 0/hpf), and no bilirubinuria.

Imaging

Diffuse consolidation and ground glass opacity were found in both lungs on her initial chest radiography (Figure 1A). Her chest computed tomography (CT) showed bilateral symmetric involvement with multifocal consolidations, diffuse ground glass opacity and interlobular septal thickening (Figure 1B).

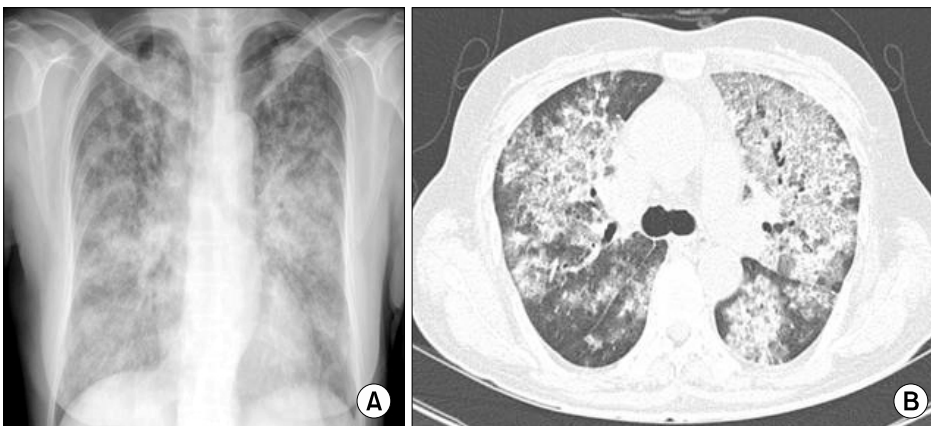


Figure 1. Diffuse consolidation and ground glass opacity are observed on both lungs of initial chest X-ray (A). Initial chest computed tomography shows bilateral involvement of diffuse ground glass opacity, interlobular septal thickening, and multifocal consolidations (B).

Assessment

C-ANCA positive DAH associated with methimazole was diagnosed based on her clinical history (history of methimazole usage), laboratory findings (positive C-ANCA, negative anti-microbiologic serology, and negative culture reports), and chest CT findings. Systemic lupus erythematosus (SLE) was excluded because anti-ds-DNA was less than 3 IU/mL (normal range, 0.0~7.0 IU/mL) and she did not have clinical features meeting the diagnostic criteria of SLE.

Progression

Methimazole was stopped and broad-spectrum antibiotics were administered empirically for possible severe community acquired pneumonia. However, her clinical condition deteriorated with her hemoptysis being unabated despite antibiotic therapy and cessation of methimazole. On the third day of hospitalization, she was intubated and mechanical ventilator was applied because respiratory failure had developed. Bronchoscopic evaluation to confirm diffuse alveolar hemorrhage was not ini-

tially performed due to her unstable condition of respiratory failure. She began to be treated by steroid pulse therapy (methylprednisolone 1 g per day for 3 days) for diffuse alveolar hemorrhage. Steroid therapy improved her oxygenation and chest radiography, as shown in Figure 2. Bronchoscopy performed on the 5th day of hospitalization after steroid pulse therapy detected no endobronchial lesions (Figure 3). She was extubated on the 9th day of hospitalization. On the 13th day of hospitalization, the patient was discharged from the hospital with prednisolone 40 mg per day, because her clinical condition had shown a substantial improvement. After discharge, C-reactive protein dropped from 10.04 to 2.20 mg/dL and serum hemoglobin level improved from 7.0 to 10.9 g/dL respectively. DAH did not recur with cessation of steroid and she had radioactive iodine therapy for her Grave's disease.

DISCUSSION

Here, we report a rare case of DAH due to C-ANCA vasculitis associated with methimazole in a Korean patient

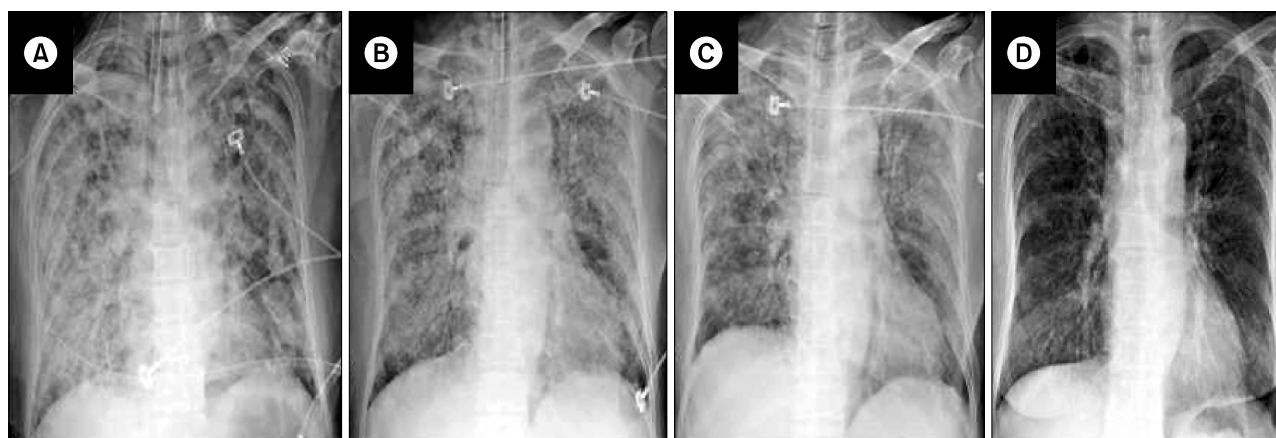


Figure 2. Chest X-rays at intensive care unit showed gradual improvement. On hospital day 3 mechanical ventilator care and steroid pulse therapy were started (A). On hospital day 5, both lung consolidations were improved (B). On hospital day 9, extubation was done (C). On hospital day 13, the patient was discharged from the hospital (D).

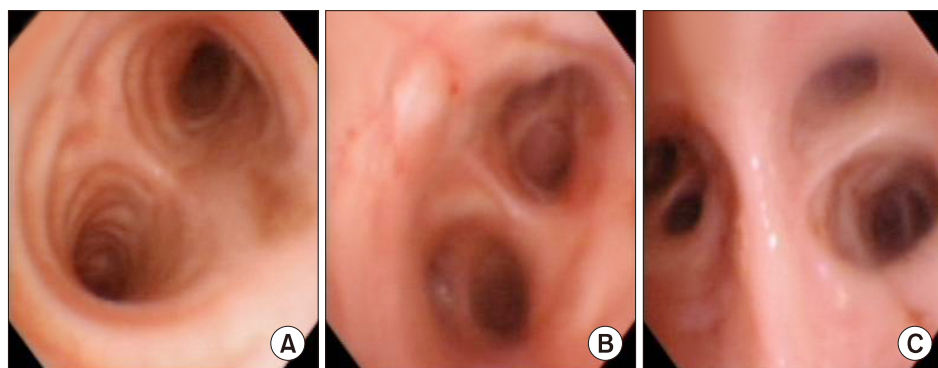


Figure 3. Bronchoscopy (A: main carina, B: left, second carina, C: right upper lobe branch) performed on hospital day 5 showed no endobronchial lesion.

with Grave's disease. The diagnosis of DAH was determined by a clinical manifestation of massive hemoptysis, a history of methimazole medication, and bilateral involvement of diffuse ground glass opacity on chest CT. Steroid pulse therapy rapidly improved her respiratory failure.

DAH is a life-threatening condition associated with various disorders and caused by many provoking factors [1,4]. DAH pathologically originates from damage of alveolar capillaries, arterioles, and venules [2,8]. In our case, bronchoalveolar lavage and lung biopsy were not performed because the patient had massive hemoptysis and was in severe respiratory failure. Hemoptysis, however, is clinically absent in up to one-third of patients with DAH [4,9]. Therefore, a percentage of siderophages (alveolar macrophages filled with hemosiderin $\geq 20\%$) obtained by bronchoalveolar lavage can establish the diagnosis of DAH [9]. Lung biopsy is not usually recommended despite some assistance in diagnosis, due to lack of specific histologic features in most cases of DAH [1].

Propylthiouracil (PTU) and methimazole have been reported to induce ANCA-associated vasculitis in patients with Grave's disease [6,10,11]. But its underlying mechanism by which such drugs provoke ANCA-positive vasculitis is not well defined. DAH induced by PTU or methimazole generally has P-ANCA associated vasculitis as shown in Table 1, whereas our case of C-ANCA associated vasculitis is exceptional [6,10,11]. ANCA is an autoantibody targeting the lysosomal enzymes of neutrophils, and C-ANCA reacts against cytoplasmic PR3 and P-ANCA reacts against MPO [12]. ANCA-associated vasculitis has diverse manifestations with constitutional symptoms, including cutaneous, pulmonary, and renal involvement [12]. ANCA-associated vasculitis generally shows a good response to glucocorticoids, and early cessation of the offending drug is essential in successful treatment of drug-induced vasculitis [12]. The patient in our case recovered from serious respiratory failure by cessation of methimazole and commencing of steroid pulse therapy. Use of steroids has been the cornerstone of ANCA-asso-

Table 1. Summary of cases of diffuse alveolar hemorrhage with MPO-ANCA associated with anti-thyroid drugs

Drug	Race	Gender/ Age (yr)	Other feature	Anti-MPO	Anti-PR3	Tx	Outcome	Reference
MMI	Korean	F/59	-		+	S	Improved	Present case
PTU	Caucasian	F/27	Athralgia, renal failure	+		SP	Improved	Ortiz-Diaz et al.*
PTU	Japanese	F/69	-	+		S	Improved	Wakabayashi et al.*
PTU/MMI	Chineses	F/44	Hematuria	+		S	Improved	Lau et al. [6]
PTU	Korean	Pregnant F/25	GN	+		S	Improved	Kang et al.*
CMZ	Spanish	F/52	GN	+		SC	Improved	Calañas-Continente et al.*
PTU	NA	F/12	-	+		S	Improved	Pirot et al.*
PTU	Japanese	F/54	Hematuria	+		S	Improved	Nakamori et al.*
PTU	Japanese	F/59	-	+	+	-	Improved	Yamauchi et al.*
PTU	Japanese	F/66	Hematuria	+		S	Improved	Katayama et al. [11]
PTU	Caucasian	F/33	-	+		SC	Died	Seligman et al.*
MMI	Chinese	F/18	Skin, nerve	+		SP	Improved	Tsai et al. [10]
PTU	NA	Pregnant F/23	GN	+		SP	Improved	Dhillon et al.*
PTU	Japanese	F/44	Hematuria	+		-	Improved	Ohtsuka et al.*
PTU	NA	F/39	Arthritis	+		-	Improved	Romas et al.*

MPO: myeloperoxidase, ANCA: anti-neutrophil cytoplasmic antibody, PR3: proteinase 3, Tx: treatment, MMI: methimazole, PTU: propylthiouracil, CMZ: carbimazole, F: female, GN: glomerulonephritis, S: steroid, P: plasmapheresis, C: cyclophosphamide, NA: not available.

*Extra references for Table 1.

Calañas-Continente A, et al. *Thyroid* 2005;15:286-8. Dhillon SS, et al. *Chest* 1999;116:1485-8.

Kang AY, et al. *Korean J Intern Med* 2006;21:240-3. Nakamori Y, et al. *Intern Med* 2003;42:529-33.

Ohtsuka M, et al. *Eur Respir J* 1997;10:1405-7. Ortiz-Diaz EO. *BMJ Case Rep* 2014 Aug 22 [Epub] DOI: 10.1136/bcr-2014-204915.

Pirot AL, et al. *Pediatr Pulmonol* 2005;39:88-92. Romas E, et al. *J Rheumatol* 1995;22:803.

Seligman VA, et al. *J Clin Rheumatol* 2001;7:170-4.

Wakabayashi K, et al. *Nihon Ronen Igakkai Zasshi* 2012;49:612-6. Yamauchi K, et al. *Respirology* 2003;8:532-5.

ciated vasculitis therapy, and dose and duration of steroid therapy vary considerably according to various phases of treatment for ANCA associated vasculitis, including remission, induction, and maintenance therapy [13].

DAH induced by methimazole has rarely been reported in Asian countries [6,9]. In contrast to our case with C-ANCA associated DAH, two previously reported cases had MPO-ANCA positive vasculitis [6,10]. Both cases with MPO-ANCA associated DAH were successfully managed mainly with steroid-based therapy as in our case [6,10].

Some lessons can be learned from our case. First, prompt diagnosis and adequate treatment are crucial factors for the prognosis of life-threatening DAH, as early diagnosis and immediate therapeutic intervention by steroid were instrumental in helping our patient survive DAH [14,15]. Second, clinicians should be alert to the possibility that DAH can occur in patients taking methimazole.

There are some limitations to this case report. First, bronchoscopic evaluation to confirm DAH was not performed initially due to her unstable condition. Second, surgical lung biopsy was not performed to exclude other histologic diagnoses, especially Wegener's granulomatosis.

In conclusion, the patient was clinically diagnosed as C-ANCA positive DAH associated with methimazole and was successfully treated by cessation of methimazole and commencing the steroid pulse therapy. These suggest that prompt diagnosis and immediate intervention with steroid adequate treatment are required in the successful management of critically life-threatening DAH.

SUMMARY

Diffuse alveolar hemorrhage is an unusual life-threatening condition characterized by anemia, hemoptysis, and diffuse alveolar infiltrates on chest radiographs. Here, we reported a case of methimazole-associated C-ANCA vasculitis presenting with life-threatening DAH. Her clinical condition improved substantially after cessation of methimazole and steroid pulse therapy. Prompt diagnosis and immediate therapeutic intervention with steroid are required in the successful management of critically life-threatening DAH.

CONFLICT OF INTEREST

No potential conflict of interest relevant to this article

was reported.

REFERENCES

1. Green RJ, Ruoss SJ, Kraft SA, Duncan SR, Berry GJ, Raffin TA. Pulmonary capillaritis and alveolar hemorrhage. Update on diagnosis and management. *Chest* 1996;110: 1305-16.
2. Cordier JF, Cottin V. Alveolar hemorrhage in vasculitis: primary and secondary. *Semin Respir Crit Care Med* 2011; 32:310-21.
3. Primack SL, Miller RR, Müller NL. Diffuse pulmonary hemorrhage: clinical, pathologic, and imaging features. *AJR Am J Roentgenol* 1995;164:295-300.
4. Lara AR, Schwarz MI. Diffuse alveolar hemorrhage. *Chest* 2010;137:1164-71.
5. Specks U. Diffuse alveolar hemorrhage syndromes. *Curr Opin Rheumatol* 2001;13:12-7.
6. Lau EY, So SY, Chan E, Kwok J, Ma J, Kung AW. Methimazole-induced antineutrophil cytoplasmic antibody-associated diffuse alveolar haemorrhage in a Chinese woman with Graves' disease. *Hong Kong Med J* 2009;15: 209-12.
7. Gunton JE, Stiel J, Clifton-Bligh P, Wilmshurst E, McElduff A. Prevalence of positive anti-neutrophil cytoplasmic antibody (ANCA) in patients receiving anti-thyroid medication. *Eur J Endocrinol* 2000;142:587.
8. Colby TV, Fukuoka J, Ewaskow SP, Helmers R, Leslie KO. Pathologic approach to pulmonary hemorrhage. *Ann Diagn Pathol* 2001;5:309-19.
9. De Lassence A, Fleury-Feith J, Escudier E, Beaune J, Bernaudin JF, Cordonnier C. Alveolar hemorrhage. Diagnostic criteria and results in 194 immunocompromised hosts. *Am J Respir Crit Care Med* 1995;151:157-63.
10. Tsai MH, Chang YL, Wu VC, Chang CC, Huang TS. Methimazole-induced pulmonary hemorrhage associated with antimyeloperoxidase-antineutrophil cytoplasmic antibody: a case report. *J Formos Med Assoc* 2001;100:772-5.
11. Katayama K, Hata C, Kagawa K, Noda M, Nakamura K, Shimizu H, et al. Diffuse alveolar hemorrhage associated with myeloperoxidase-antineutrophil cytoplasmic antibody induced by propylthiouracil therapy. *Respiration* 2002; 69:473.
12. Bonaci-Nikolic B, Nikolic MM, Andrejevic S, Zoric S, Bukilica M. Antineutrophil cytoplasmic antibody (ANCA)-associated autoimmune diseases induced by antithyroid drugs: comparison with idiopathic ANCA vasculitides. *Arthritis Res Ther* 2005;7:R1072-81.
13. Keller SF, Miloslavsky EM. Corticosteroids in antineutrophil cytoplasmic antibody-associated vasculitis. *Rheum Dis Clin North Am* 2016;42:91-101, viii.
14. Holguin F, Ramadan B, Gal AA, Roman J. Prognostic factors for hospital mortality and ICU admission in patients with ANCA-related pulmonary vasculitis. *Am J Med Sci* 2008; 336:321-6.
15. de Prost N, Parrot A, Picard C, Ancel PY, Mayaud C, Fartoukh M, et al. Diffuse alveolar haemorrhage: factors associated with in-hospital and long-term mortality. *Eur Respir J* 2010;35:1303-11.