

Rivaroxaban for Thromboprophylaxis in Patients with Antiphospholipid Syndrome

Ji Ho Park, Jung-Soo Song, Sang Tae Choi

Division of Rheumatology, Department of Internal Medicine, Chung-Ang University College of Medicine, Seoul, Korea

The main treatment for Antiphospholipid syndrome (APS) is long-term anticoagulation with an oral vitamin K antagonist, although these are associated with numerous problems. Rivaroxaban is a direct anti-factor Xa inhibitor, with a predictable anticoagulant effect at fixed doses. There are limited reports of rivaroxaban use in APS. We present four cases of patients with APS who received rivaroxaban treatment for six months without thrombosis recurrence or bleeding. Three of the patients received rivaroxaban as initial therapy. In the systematic review, only five patients were treated with rivaroxaban as a thromboprophylaxis. Of the 71 cases of rivaroxaban use including our study, there were seven cases (9.9%) of thrombosis recurrence and two reports of bleeding. The efficacy of rivaroxaban in APS patients was at least equal to warfarin therapy. This report and systematic review suggest that rivaroxaban can be considered cautiously as a thromboprophylactic or alternative therapy for warfarin in patients with APS. (*J Rheum Dis* 2017;24:108-113)

Key Words. Rivaroxaban, Antiphospholipid syndrome

INTRODUCTION

Antiphospholipid syndrome (APS) is an autoimmune disease characterized by vascular thrombosis and/or pregnancy morbidity occurring in association with persistent antiphospholipid antibodies [1]. The conventional treatment for APS involves heparin, followed by long-term anticoagulation. Heparin, either as a low-molecular weight or as an unfractionated formulation, is administered via injection. Thus, the current mainstay of long-term treatment for thrombotic APS is an oral vitamin K antagonist (VKA), such as warfarin [2]. However, treatment with a VKA is associated with numerous problems, because of interactions with other drugs and foods, therefore frequent international normalized ratio (INR) monitoring is required. Moreover, long-term VKA use is associated with an increased rate of serious bleeding, and the inconvenience of regular INR testing can affect quality of life.

Recently, a number of novel drugs have been developed

with anticoagulation potential. Rivaroxaban is a direct anti-factor Xa inhibitor. It has a predictable anticoagulant effect at a fixed dose, and does not interact with dietary constituents or alcohol. Moreover, rivaroxaban does not require routine monitoring of anticoagulant intensity [3]. In phase III randomized controlled trials, rivaroxaban showed comparable efficacy and safety to warfarin in the treatment of venous thromboembolism and pulmonary embolism (PE) [4,5]. Here, we report 4 cases of patients with APS receiving treatment with rivaroxaban for 6 months. Three of the patients received rivaroxaban as a thromboprophylactic therapy without receiving warfarin previously.

CASE REPORT

Case 1

A 20-year-old man was admitted via the emergency department with sudden right leg pain and swelling. Initial vital sign was stable without hypoxemia on arterial blood

Received : June 1, 2016, **Revised :** August 4, 2016, **Accepted :** August 24, 2016

Corresponding to : Sang Tae Choi, Division of Rheumatology, Department of Internal Medicine, Chung-Ang University College of Medicine, 102 Heukseok-ro, Dongjak-gu, Seoul 06973, Korea. E-mail : beconst@hanmail.net

Copyright © 2017 by The Korean College of Rheumatology. All rights reserved.

This is a Free Access article, which permits unrestricted non-commercial use, distribution, and reproduction in any medium, provided the original work is properly cited.

gas analysis. Deep vein thrombosis (DVT) involving the entire right iliac vein and extending to the lower inferior vena cava was shown on a lower extremity computer tomography (CT) angiography (Figure 1A). In addition, PEs were detected in the right lower lobar pulmonary artery and right lower lobe posterior basal segmental pulmonary artery using chest CT imaging (Figure 1B). An inferior vena cava filter was inserted at L1/2 level with mechanical thrombectomy, and enoxaparin (60 mg twice a day) was initiated. On admission, the patient tested positive for lupus anticoagulant (LA) (LA 1.79 with activated partial thromboplastin time [aPTT] 42.7 sec, reference range < 1.2, by diluted Russell's viper venom test, STA[®]-Staclo[®] DRVV Confirm [Diagnostica Stago SAS, Asnieres-sur-Seine, France]) and anti-cardiolipin (aCL) immunoglobulin G

(IgG) (37 IgG phospholipid [GPL], reference range < 23, by REEADS IgG/IgM aCL enzyme-linked immunosorbent assay [ELISA] [Corgenix Inc., Broomfield, CO, USA]). After 12 weeks, follow-up test was showed positivity for LA (2.18), aCL IgG (22 GPL) and anti- β_2 glycoprotein I IgG (49 GPL, reference range < 20, by REAADS IgG/IgM anti- β_2 glycoprotein I ELISA [Corgenix Inc.]). Following initial enoxaparin use for 2 days, rivaroxaban (20 mg/day) was prescribed for 6 months. During rivaroxaban treatment, no recurrences of thrombosis or other complications were reported. Follow-up CT imaging after 10 months showed completely disappeared pulmonary thromboembolism (PT) of pulmonary arteries in lobar and segmental branches of right lower lobe (Figure 1C) and partially disappeared filling defects in right external iliac to the in-

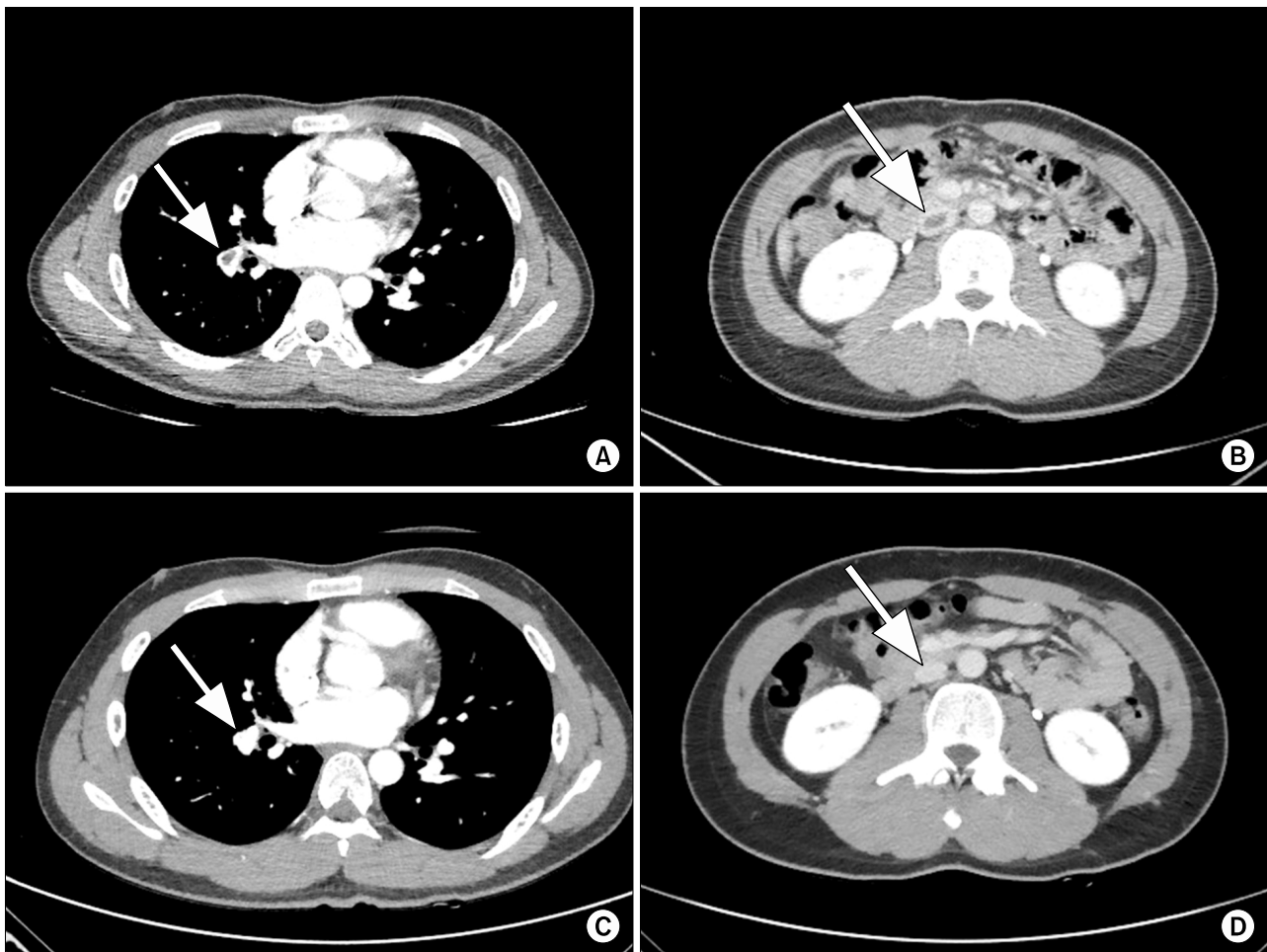


Figure 1. (A) Low attenuated filling defect (arrow) involving the pulmonary artery of the right lower lobe suggestive of a pulmonary embolism at the time of diagnosis. (B) Low attenuated filling defect (arrow) in the inferior vena cava suggestive of deep vein thrombosis at the time of diagnosis. (C) Completely disappeared filling defect (arrow) of pulmonary arteries of the right lower lobe at 10 months after diagnosis. (D) Partially disappeared but still remained small portion of filling defect (arrow) in the inferior vena cava at 10 months after diagnosis.

ferior vena cava (Figure 1D). The patient was subsequently switched from rivaroxaban to warfarin within an INR of 2.0~3.0, and he was followed for a further 4 months without thrombosis.

Case 2

A 60-year-old man without any past medical history about cardiovascular risk factor presented to the outpatient clinic with chest discomfort and left leg pain that had been ongoing for several days. Initial vital sign was stable without any hypoxemia on arterial blood gas analysis. Multiple PEs in the segmental pulmonary arteries of the lingular division of the left upper lobe, the medial basal segments of both lower lobes, and the anterior basal segment of the right lower lobe (Figure 2A), and DVTs in the left popliteal vein (Figure 2B) were revealed on CT imaging. On admission, the patient tested

positive for anti-nuclear antibodies (1:160) and anti- β_2 glycoprotein I IgM (26 MPL, reference range <20). However, he had no symptoms that were indicative of systemic lupus erythematosus or any other autoimmune disease. Further, all of the other tests for autoantibodies were negative. After 12 weeks, the tests showed positivity for anti-nuclear antibodies (1:80) and LA (1.59 with aPTT 28.0 sec). Furthermore, the test showed positivity for LA (1.53) at 6 months follow-up. The patient was initially treated by rivaroxaban (20 mg/day) for 6 months without incidence of thrombosis recurrence or complications. Rivaroxaban was subsequently switched to warfarin within an INR of 2.0~3.0, and the patient was followed for a further 3 months without recurrence of thrombosis. Follow-up CT imaging after 10 months showed disappeared filling defects in both pulmonary artery (Figure 2C) and the left popliteal vein (Figure 2D).

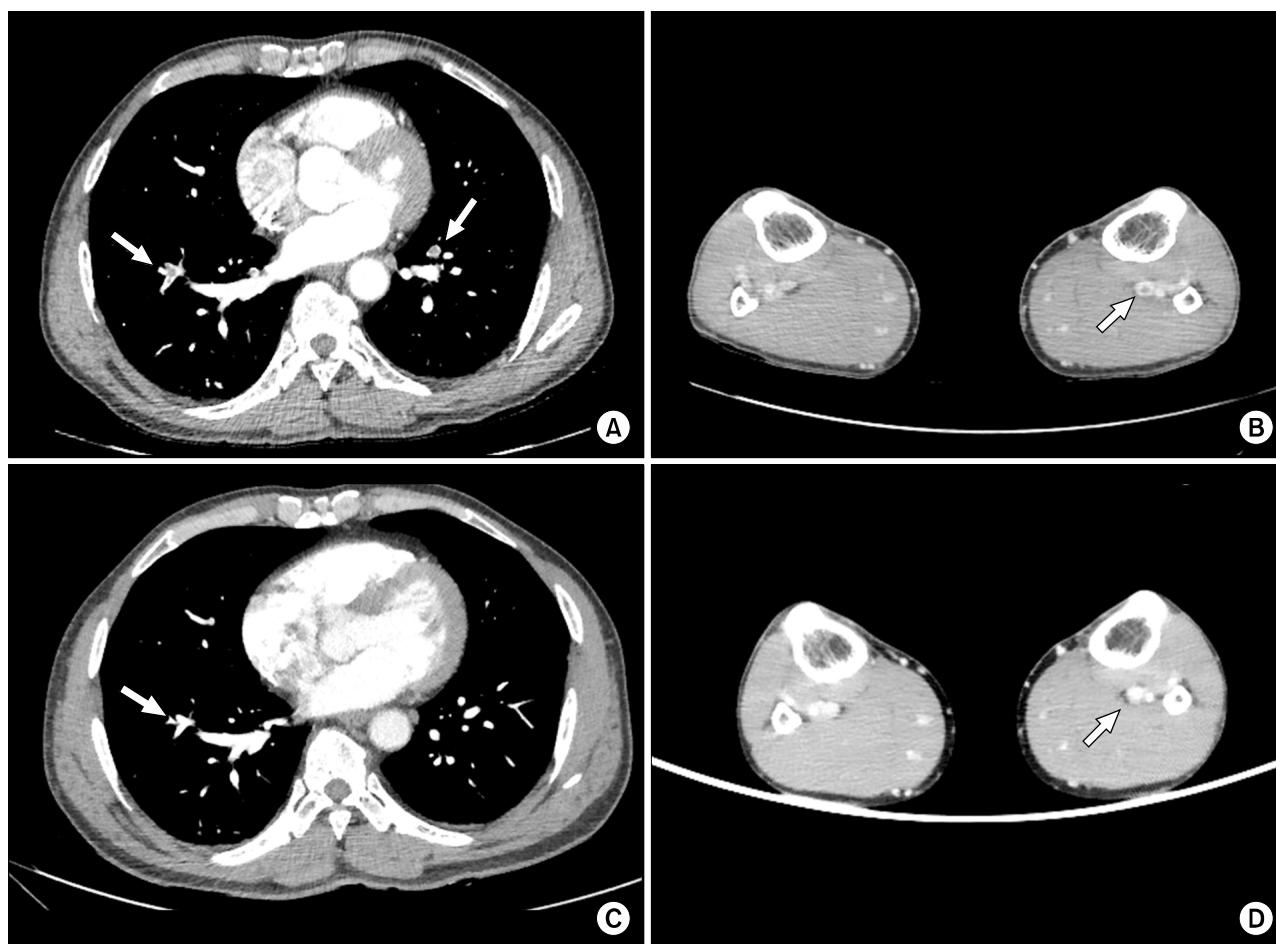


Figure 2. (A) Multiple low attenuated filling defects (arrows) in both pulmonary arteries suggestive of pulmonary embolisms at the time of diagnosis. (B) Low attenuated filling defect (arrow) in the left popliteal vein suggestive of deep vein thrombosis at the time of diagnosis. (C) Disappeared filling defects (arrow) in both pulmonary arteries at 10 months after diagnosis. (D) No discernible filling defect (arrow) in the left popliteal vein at 10 months after diagnosis.

Case 3

A 78-year-old woman was referred with sudden chest pain. Initial vital sign was stable. She was undergoing rehabilitation for a subarachnoid hemorrhage that had occurred 2 months previous. She had no previous history about cardiovascular risk factor except hypertension. She could walk independently with some limitation. Multiple PEs in the medial, anterior, and lateral basal segments of the left lower lobe were detected on chest CT imaging (Figure 3), but there was no evidence of DVT. She tested positive for aCL IgG (54 GPL), and was treated with warfarin. Five months later, following a positive repeat test for aCL IgG (48 GPL), she was diagnosed with APS. Rivaroxaban (20 mg/day) was prescribed instead of warfarin for 6 months. The patient was subsequently switched back to warfarin. She was followed for a further 8 months without any recurrence of thrombosis or bleeding.

Case 4

A 59-year-old man presented to the outpatient clinic with left leg pain and edema. He had been diagnosed with a right DVT at a different hospital 11 months before, and had been initially prescribed heparin followed by rivaroxaban (20 mg/day) for 6 months. He had not received any further medication until the development of the current left leg problem. Initial vital sign was stable and he didn't have any past medical history except previous DVT. CT imaging revealed multiple thromboses of both the distal superficial femoral vein and the popliteal vein (Figure 4). Tests for aCL IgG upon admission and at 12-week fol-

low-up were positive (28 GPL and 24 GPL, respectively). Furthermore, test for aCL IgG at 24-week follow-up was positive on high titer (45 GPL). The patient was prescribed rivaroxaban 20 mg/day for 6 months. A lower extremity ultrasound 5 months later showed no evidence of thrombosis. After 6 months of rivaroxaban treatment, the patient was switched to warfarin for 2 months.

DISCUSSION

In the cases reported here, the patients with APS showed no recurrence of thrombosis or bleeding during the 6 months of rivaroxaban treatment. Notably, 3 of the 4 patients received rivaroxaban as initial therapy without previous warfarin use. Rivaroxaban may have efficacy as a thromboprophylaxis in patients with APS. We believe that this is the first report of rivaroxaban use for APS patients in Korea.

A number of drugs, including aspirin, clopidogrel, and dabigatran, have demonstrated minimal or no benefit for the prevention of thrombosis in APS manifestations [6,7]. Therefore, despite serious side effects, long-term anticoagulation with warfarin is regarded as the mainstay of treatment for the management of APS.

Rivaroxaban, a direct anti-factor Xa inhibitor, has numerous advantages over warfarin, including no dietary or drug interactions, no requirements for drug level monitoring, and a lower risk of serious bleeding [3]. Rivaroxaban is not expected to directly influence protein C and S activity. Thus, it may have a greater anticoagulation effect than warfarin in patients with APS [8]. However, rivarox-

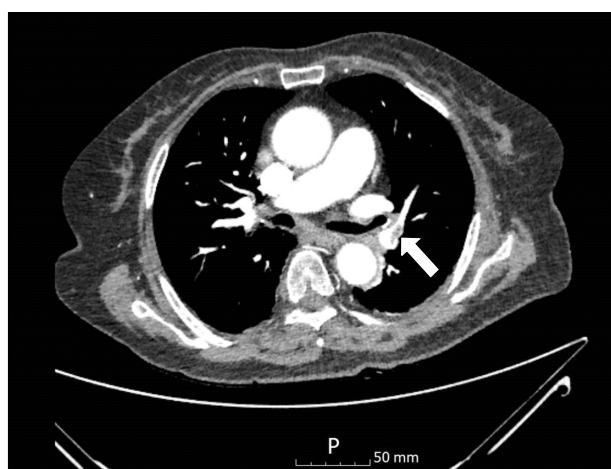


Figure 3. Pulmonary embolism in the segmental bronchi of the left lower lobe (arrow).

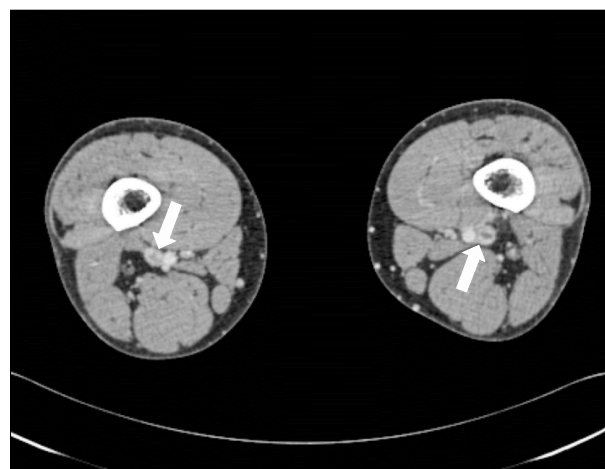


Figure 4. Low attenuated filling defects (arrow) suggest deep vein thrombosis in both popliteal veins.

Table 1. Summary of cases of rivaroxaban use in patients with antiphospholipid syndrome

First author (ref.)	Number of patient	Site	Duration (mo)	Outcome
Current study	4	2: DVT with PE 1: PE 1: SVT and DVT	6	No thrombosis and bleeding
Bachmeyer et al. [10]	1	1: SVT	-	No thrombosis and bleeding
Schaefer et al. [6]	2	1: Radial arterial thrombosis 1: DVT	2/6	1: Stroke 1: Intra/extrahepatic, splenic, and mesenteric thrombosis
Win et al. [7]	2	1: Stroke with DVT 1: SVT and DVT	6/-	1: SVT 1: DVT
Son et al. [11]	12	12: DVT and stroke	2 ~ 16	10 : No thrombosis and bleeding 2: DVT
Sciascia et al. [12]	35	24: DVT 11: DVT with PE	10	No thrombosis and bleeding
Noel et al. [13]	15	12: DVT and/or PE 2: Digital ischemia or ulcer 1: Stroke	1 ~ 27	1: Microthrombotic recurrence 2: Bleeding 1: Migraine

Ref.: reference, DVT: deep vein thrombosis, PE: pulmonary embolism, SVT: superficial vein thrombosis, -: not described.

aban has some limitations on monitoring of therapeutic drug level because of lack of antidote and having insufficient evidence about usage on specific conditions such chronic kidney disease, malignancy, or pregnancy [9]. Also there is not enough evidence about rivaroxaban on massive PE with hemodynamic instability [9]. In patients with DVT and PE, a single regimen of rivaroxaban was non-inferior to standard therapy and improved the benefit-risk profile [4,5]. However, the efficacy of rivaroxaban in patients with APS has not been demonstrated yet in clinical trials.

There are a number of case reports of rivaroxaban use in patients with APS (Table 1) [6,7,10-13]. In these reports, the duration of treatment with rivaroxaban was 2 ~ 27 months. In our cases, the patients received rivaroxaban treatment for 6 months. The duration of treatment was limited by the Korean national insurance system, and not by medical problems. Of the 71 case reports of rivaroxaban use in APS including our cases, there were 7 cases of thrombosis recurrence (9.9%). Considering that the thrombosis recurrence rate in patients with APS treated with warfarin is reported as 3.4% ~ 11.1% [14,15], the efficacy of rivaroxaban in patients with APS may be non-inferior to warfarin therapy. In warfarin studies, bleeding occurrence rates are reported as 5.4% ~ 27.8% [14,15]; however, there have been two reports of bleeding associated with rivaroxaban [6,7,10-13].

In the other cases reported, all of the patients, with the

exception of five, were switched from a VKA to rivaroxaban [6,7,10-13]. In our cases, 3 of the 4 patients received rivaroxaban as the initial drug upon diagnosis without previous warfarin use. Therefore, our results with these patients suggest that early rivaroxaban use for 6 months followed by warfarin may be useful in the management of APS. An open-label prospective non-inferiority randomized controlled trial of rivaroxaban in patients with APS is ongoing [8]. The outcome of this trial and additional clinical experience will present more clear evidence on the efficacy of rivaroxaban in patients with APS.

SUMMARY

We reported the first Korean cases of rivaroxaban use as a thromboprophylaxis in APS patients. Our report suggests that rivaroxaban can be considered cautiously as a thromboprophylactic or alternative therapy for warfarin in patients with APS.

CONFLICT OF INTEREST

No potential conflict of interest relevant to this article was reported.

REFERENCES

1. Miyakis S, Lockshin MD, Atsumi T, Branch DW, Brey RL, Cervera R, et al. International consensus statement on an

- update of the classification criteria for definite antiphospholipid syndrome (APS). *J Thromb Haemost* 2006; 4:295-306.
2. Ruiz-Irastorza G, Cuadrado MJ, Ruiz-Arruza I, Brey R, Crowther M, Derksen R, et al. Evidence-based recommendations for the prevention and long-term management of thrombosis in antiphospholipid antibody-positive patients: report of a task force at the 13th International Congress on antiphospholipid antibodies. *Lupus* 2011;20: 206-18.
3. Erkan D, Aguiar CL, Andrade D, Cohen H, Cuadrado MJ, Danowski A, et al. 14th International Congress on Antiphospholipid Antibodies: task force report on antiphospholipid syndrome treatment trends. *Autoimmun Rev* 2014;13:685-96.
4. EINSTEIN Investigators, Bauersachs R, Berkowitz SD, Brenner B, Buller HR, Decousus H, et al. Oral rivaroxaban for symptomatic venous thromboembolism. *N Engl J Med* 2010;363:2499-510
5. EINSTEIN-PE Investigators, Büller HR, Prins MH, Lensin AW, Decousus H, Jacobson BF, et al. Oral rivaroxaban for the treatment of symptomatic pulmonary embolism. *N Engl J Med* 2012;366:1287-97.
6. Schaefer JK, McBane RD, Black DF, Williams LN, Moder KG, Wysokinski WE. Failure of dabigatran and rivaroxaban to prevent thromboembolism in antiphospholipid syndrome: a case series of three patients. *Thromb Haemost* 2014;112:947-50.
7. Win K, Rodgers GM. New oral anticoagulants may not be effective to prevent venous thromboembolism in patients with antiphospholipid syndrome. *Am J Hematol* 2014; 89:1017.
8. Cohen H, Doré CJ, Clawson S, Hunt BJ, Isenberg D, Khamashta M, et al. Rivaroxaban in antiphospholipid syndrome (RAPS) protocol: a prospective, randomized controlled phase II/III clinical trial of rivaroxaban versus warfarin in patients with thrombotic antiphospholipid syndrome, with or without SLE. *Lupus* 2015;24:1087-94.
9. Bayer Pharma AG. Xarelto® Summary of product characteristics [Internet]. Berlin: Bayer HealthCare Pharmaceuticals, 2015 May [cited 2016 Aug 24]. Available from: <https://www.xarelto.com/static/media/pdf/BHC-Xar-SPC-May-2015-LAY03.pdf>.
10. Bachmeyer C, Elalamy I. Rivaroxaban as an effective treatment for recurrent superficial thrombophlebitis related to primary antiphospholipid syndrome. *Clin Exp Dermatol* 2014;39:840-1.
11. Son M, Wypasek E, Celinska-Lowenhoff M, Undas A. The use of rivaroxaban in patients with antiphospholipid syndrome: A series of 12 cases. *Thromb Res* 2015;135:1035-6.
12. Sciascia S, Breen K, Hunt BJ. Rivaroxaban use in patients with antiphospholipid syndrome and previous venous thromboembolism. *Blood Coagul Fibrinolysis* 2015;26:476-7.
13. Noel N, Dutasta F, Costedoat-Chalumeau N, Bienvenu B, Mariette X, Geffray L, et al. Safety and efficacy of oral direct inhibitors of thrombin and factor Xa in antiphospholipid syndrome. *Autoimmun Rev* 2015;14:680-5.
14. Crowther MA, Ginsberg JS, Julian J, Denburg J, Hirsh J, Douketis J, et al. A comparison of two intensities of warfarin for the prevention of recurrent thrombosis in patients with the antiphospholipid antibody syndrome. *N Engl J Med* 2003;349:1133-8.
15. Finazzi G, Marchioli R, Brancaccio V, Schinco P, Wisloff F, Musial J, et al. A randomized clinical trial of high-intensity warfarin vs. conventional antithrombotic therapy for the prevention of recurrent thrombosis in patients with the antiphospholipid syndrome (WAPS). *J Thromb Haemost* 2005;3:848-53.