

Melanotic Oncocytic Metaplasia of the Nasopharynx in the Patient with Suspicious Hemoptysis: Case Report

Taek Yoon Cheong, MD¹, Han Seong Kim, MD, PhD², and Ick Soo Choi, MD, PhD¹

¹Department of Otorhinolaryngology-Head and Neck Surgery and ²Pathology, Ilsan Paik Hospital, Inje University College of Medicine, Goyang, Korea

Melanotic oncocytic metaplasia (MOM) in the nasopharyngeal space is a very rare entity. Only 35 cases have been reported in the English literature, and most patients were East Asian males between 60 and 70 years of age. MOM presents as a brown or black lesion with slight elevation of the mucosa. These lesions are benign and defined as cellular enlargement with eosinophilic granular melanin-pigmented cytoplasm caused by mitochondrial accumulation. However, such presentation can lead physicians to misjudge MOM as a malignant lesion. Recently, we experienced a case of MOM of the nasopharynx. A 58-year-old woman was admitted to the internal medicine department with small-volume hemoptysis and referred to the ENT department for evaluation. She was a regular smoker without any medical history. Sinus endoscopy showed black pigmented lesions on both the torus tubaris and left posterior tonsillar pillar, with low bleeding risk. Excisional biopsy of the lesion was performed, and oncocytic metaplasia was confirmed pathologically. Hemoptysis showed spontaneous remission and no recurrence or other symptoms over 12 months of follow up. Melanotic oncocytic metaplasia in the nasopharynx should be clinically recognized to avoid misdiagnosis as a malignancy like melanoma.

KEY WORDS: Adenoma, Oxyphilic · Nasopharynx · Hemoptysis.

INTRODUCTION

First melanotic oncocytic metaplasia (MOM) of the nasopharynx was reported in 1995.¹⁾ MOM can be misdiagnosed as early nasopharyngeal carcinoma or melanoma, due to its macroscopic appearance. However, MOM is clearly distinct from such diseases histologically. MOM comprises both oncocytic metaplasia and melanin pigmentation of the epithelium in the same gland. Oncocytes are big epithelial cells with an aplenty, deeply eosinophilic granular cytoplasm and a small, round, dark colored nucleus. Melanocytes found to coexist in MOM, is considered to be the source of melanin.²⁾ No atypia or mitotic activity found in MOM. Fontana-Masson staining is positive and highlights several dendritic melanocytes between the metaplastic and the surface

epithelial cells.³⁾ MOM is thought to be an age-related change since its incidence increases with age, and predominantly occurs in Asian population.⁴⁾

MOM of the nasopharynx is a very rare lesion, and only 35 cases were reported in English literature. Most lesions were asymptomatic and incidentally discovered during physical examination.

We present here a case of MOM of the nasopharynx, found in a patient with suspicious hemoptysis.

CASE REPORT

A 58-year-old woman was admitted to internal medicine department, presenting small volume hemoptysis for 5 days. She was a regular smoker (10/day × 20 years) without any

Received: July 30, 2020 / **Revised:** September 14, 2020 / **Accepted:** October 5, 2020

Address for correspondence: Ick Soo Choi, MD, PhD, Department of Otorhinolaryngology-Head and Neck Surgery, Ilsan Paik Hospital, Inje University College of Medicine, 170 Juhwa-ro, Ilsanseo-gu, Goyang 10380, Korea

Tel: +82-31-910-7114, Fax: +82-31-910-7747, E-mail: Leochoics@gmail.com

medical history. Patient admitted and undergone computed tomography scan of lung. Since the radiologic evaluation at the internal medicine department showed no clinical signifi-

cance except for minor bronchopneumonia, consultation to ENT department was proceed for further evaluation of other possible causes. Sinus endoscopy revealed black pig-

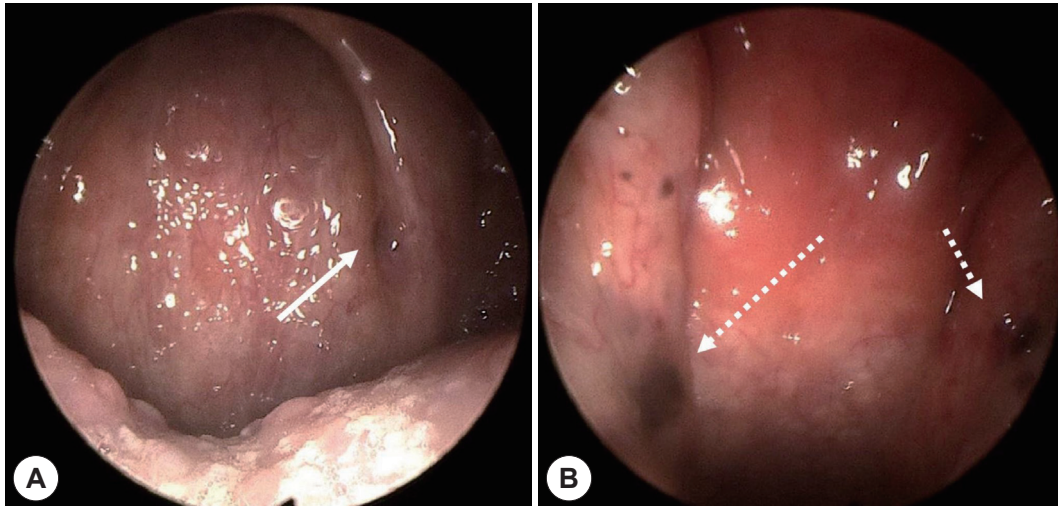


Fig. 1. Endoscopic findings. A: Endoscopic finding of melanotic oncocytic metaplasia on left anterior pharyngeal pillar (white arrow). B: Endoscopic finding of melanotic oncocytic metaplasia on both torus tubaris (white dotted arrows).

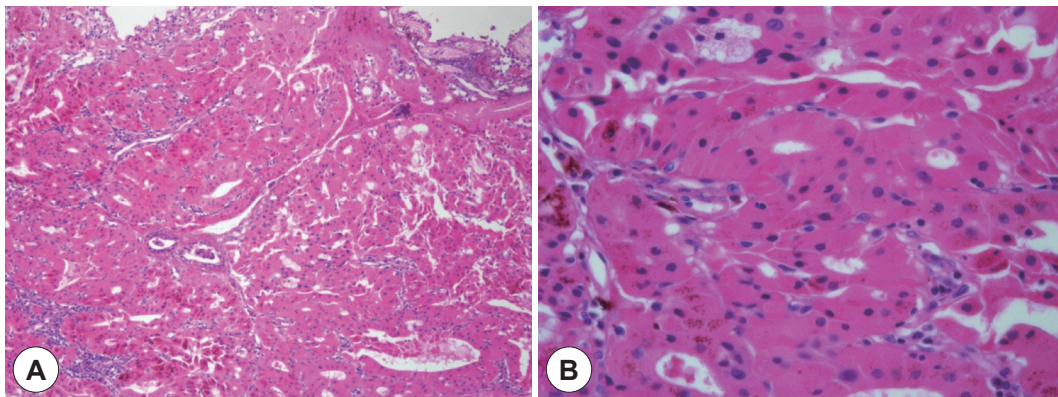


Fig. 2. Pathologic results of the case. A: Microscopic finding ($\times 100$) shows deeply homogeneous eosinophilic epithelial cells, noted with lumen formation. B: Scattered melanin pigment granules are found in eosinophilic cytoplasm ($\times 400$).

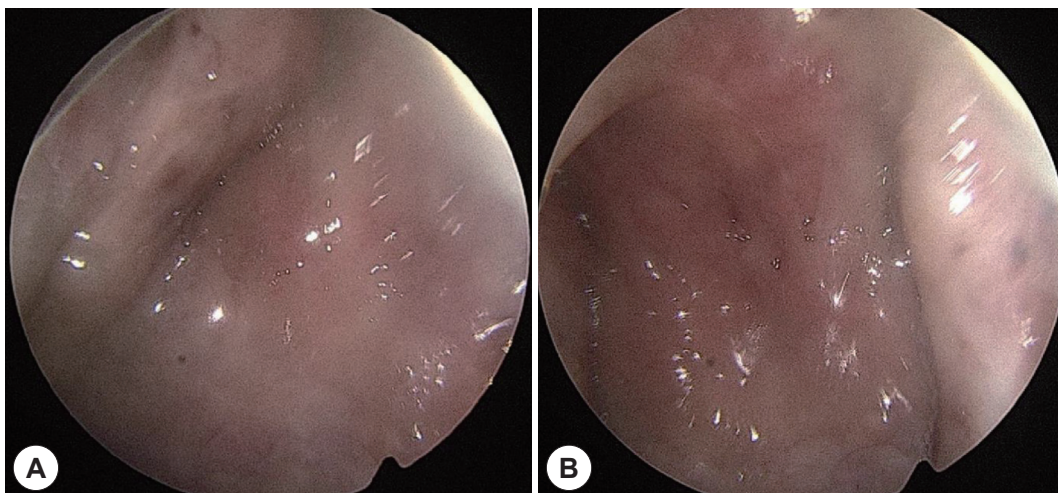


Fig. 3. Endoscopic findings after 12 months. A: Rt torus tubaris. B: Lt torus tubaris.

mented lesions on both torus tubaris and left posterior tonsillar pillar (Fig. 1), but bleeding from the lesion was unseen. Sinus mucosa and anatomy was intact otherwise. Though

hemoptysis stopped spontaneously during the admission period, surgical biopsy of the lesion was performed to rule out possible malignancy. Five specimens were sent for he-

Table 1. Reported cases of melanotic oncocyctic metaplasia of nasopharynx

Case	Sex/age	Site	Chief complaint for visiting clinic	Number of lesions	Smoking history	Author/year
1	M/67	EO	Otitis media	Single	Unknown	Shek TW, 1995 ¹
2	M/63	EO	Tinnitus	Single	Unknown	Shek TW, 1995
3	M/70	Bilateral EO	Tinnitus	Multiple	Unknown	Xue WC, 1999 ⁵
4	M/64	Bilateral EO, left suprapharynx, and nasal cavity	Throat discomfort	Multiple	Unknown	Hirakawa E, 1999 ⁶
5	M/62	Left EO and bilateral torus tubaris	Discomfort in Lt ear	Multiple	Unknown	Takano K, 2004 ⁷
6	M/69	Left nasopharynx	Foreign body swallowing	Multiple	Unknown	Kurihara K, 1997 ⁸
7	M/80	Right nasal cavity and pharynx	Hoarseness	Multiple	10/day × 50 yr	Sakaki M, 2004 ⁹
8	M/69	Left EO	Hoarseness	Single	40/day × 60 yr	Sakaki M, 2004
9	M/74	Left nasopharynx	Rhinorrhea	Single	Unknown	Sakaki M, 2004
10	F/74	Right EO	Throat discomfort	Multiple	Unknown	Sakaki M, 2004
11	M/68	Nasopharynx	None	Single	Unknown	Sakaki M, 2004
12	M/65	Right EO	Hemoptysis	Single	Unknown	Sakaki M, 2004
13	M/63	Left EO	Epistaxis	Single	Unknown	Sakaki M, 2004
14	M/-	Bilateral nasopharynx	None(examined to find origin site of metastatic carcinoma)	Multiple	Unknown	Liao C, 2005 ¹⁰
15	M/79	Right EO	Otitis media	Single	20/day × 40 yr	Lui PC, 2004 ¹¹
16	M/58	Bilateral nasopharynx	Epistaxis	Multiple	Unknown	Li Y, 2010 ¹²
17	M/73	Bilateral torus tubaris	Nasal congestion	Multiple	Non-smoker	Kondo, 2010 ¹³
18	M/72	Bilateral torus tubaris	Headache and hearing impairment	Multiple	40/day × 50 yr	JY Na, 2012 ¹⁴
19	M/71	Left torus tubaris and soft palate	Hoarseness	Multiple	20/day × 40 yr	JY Na, 2012
20	M/51	Right torus tubaris	Tongue pain	Multiple	Unknown	JY Na, 2012
21	M/63	Nasopharynx	Epistaxis	Multiple	40/day × 40 yr	Chang, 2014 ¹⁵
22	M/57	Right torus tubaris	None (examined to find origin site of metastatic carcinoma)	Multiple	30/day × 40 yr	Shogo Tajima, 20152
23	F/70	EO	Routine gastrointestinal endoscopy	Multiple	Unknown	Uehara K, 2015 ¹⁶
24	F/61	Left EO	Hoarseness	Single	Unknown	Uehara K, 2015
25	M/74	Bilateral nasopharynx	Hoarseness	Multiple	Unknown	Uehara K, 2015
26	M/57	Right nasopharynx	Nasal obstruction	Single	Smoker	Li J, 2019 ¹⁷
27	M/61	Left nasopharynx	Neck mass	Single	Smoker	Li J, 2019
28	M/69	Left nasopharynx	Rhinorrhea	Multiple	Smoker	Li J, 2019
29	M/56	Left EO	Epistaxis	Single	Smoker	Li J, 2019
30	M/58	Right nasopharynx	Facial palsy	Single	Smoker	Li J, 2019
31	M/52	Left EO	Tinnitus	Multiple	Smoker	Li J, 2019
32	F/77	Left nasopharynx	Hoarseness	Single	Smoker	Li J, 2019
33	M/59	Left nasopharynx	Nasal obstruction	Single	Smoker	Li J, 2019
34	M/59	Left EO	Tinnitus	Single	Smoker	Li J, 2019
35	M/75	Right EO	Epistaxis	Multiple	30/day × 50 yr	Chen HY, 2020 ¹⁸
36	F/53	Left posterior tonsillar pillar, both torus tubaris	Hemoptysis	Multiple	10/day × 20 yr	Present case, 2020

EO: Eustachian opening, M: male, F: Female

matoxylin and eosin(H&E) staining. Microscopically, homogenous oncocyctic cells with melanin pigment granules in their cytoplasm were found, and melanotic oncocyctic metaplasia was pathologically confirmed (Fig. 2). Hemoptysis stopped spontaneously. The patient discharged without complications and didn't presented hemoptysis or other symptoms during 12 months follow up. Endoscopic finding showed no further growth or advancement of previous lesion (Fig. 3).

DISCUSSION

Oncocyctic change found in the upper respiratory tract is an unusual finding. Melanotic variation of oncocyctic metaplasia is an extremely anomalous condition, presented as a small, brown to black mucosal lesion.³⁾ To our knowledge, only 35 cases have been reported in the English literature, and our case is the 36th (Table 1). All reported cases were elderly Asian, supporting the possibility of ethnic background as a predisposing factor of MOM. MOM predominantly occurred in males (31/36), and most of patients were long time smoker (18/19), supporting the hypothesis that smoking might be a predisposing factor for MOM. The male predominance of patients supports this hypothesis also, since male smokers are more frequent among Asian population. 16 cases showed single lesion while other 20 cases presented multiple lesions in nasopharynx. The presented patient was an Asian female with multiple lesions, and smoking history was relatively short compared to other 17 previously reported cases with smoking history.

Pathological findings of the patient in H&E stain showed oncocyctic metaplasia and scattered melanin pigment granules. Atypia or mitotic figures were not found. Oncocyctic cells are epithelial cells, characterized by abundant eosinophilic cytoplasm. Yet, oncocyctic metaplasia is uncommon finding in upper respiratory tract. The exact origin of the melanin pigment in MOM is still in question. However, previous studies demonstrated that Fontana-Masson stain, S-100 protein immunostain and human melanoma black-45 immunostain revealed dendritic melanocytes stretching through the epithelial cells of the glands in MOM,^{2,9)} supporting that melanin pigment may be derived from the adjoining melanocytes through their stretching dendrites.^{6,14)}

Most of the cases were found incidentally with other symptoms such as tinnitus, hoarseness, epistaxis, rhinorrhea, and hemoptysis. Some symptoms, such as ear discomfort at the

same side of MOM near eustachian opening, seemed to be related with the lesion, while other symptoms like hoarseness seemed almost independent from the lesion.

It is unclear whether MOM can cause hemoptysis or not. One case with hemoptysis was reported previously,⁹⁾ but it's clinical course or relation between the lesion was not described. Three cases with epistaxis had been reported also. During the endoscopic biopsy of presented case, the lesions didn't show hemorrhagic features, supporting irrelevance between hemoptysis and the lesion. Minor bronchopneumonia could have been the origin of hemoptysis in this case, but was not clearly identified.

Clinically, carcinoma or melanoma may show similar appearance with MOM during the endoscopic examination. Differential diagnosis between those entities are straightforward histologically, so physicians encountered such lesions should try biopsy. Endoscopic findings isn't sufficient to distinguish between MOM and nasopharyngeal malignancy since nasopharyngeal malignancy may shows various forms including submucosal lesions.

It is known that MOM follows a benign clinical path. Simple excision is a suitable treatment for MOM.²⁾ No abnormal bleeding or surgical difficulty was found in operation of this case. Since no recurrence or advancement of the lesion has been reported in the literatures, diagnosed MOM can be observed without any further treatment.

In conclusion, we report the 36th cases of melanotic oncocyctic metaplasia in the nasopharynx. As a benign imitator of malignant lesion, MOM should be always taken into consideration in examination of nasopharynx.

REFERENCES

- 1) Shek TWH, Luk ISC, Nicholls JM, Fok KO. Melanotic oncocyctic metaplasia of the nasopharynx. *Histopathology* 1995;26(3):273-5.
- 2) Tajima S, Ohkubo A, Yoshida M, Koda K, Nameki I. Melanotic oncocyctic metaplasia of the nasopharynx: a case report with a focus on immunohistochemical analyses and literature review. *International Journal of Clinical and Experimental Pathology* 2015;8(2): 2103-10.
- 3) Antonio C, Pieter J, Nina G, Alessandro F. *Pathology of the Head and Neck*. 2nd ed. Berlin, Heidelberg: Springer;2016.
- 4) Mills S. *Histology for Pathologists*. Philadelphia: Lipincott Williams & Wilkins;2012.
- 5) Xue WC, Hui YZ. Melanotic oncocyctic metaplasia of the nasopharynx. *Histopathology* 1999;35(5):481-2.
- 6) Hirakawa E, Miki H, Ohmori M, Kobayashi S, Haba R, Nagai Y. Melanin pigmented oncocyctic metaplasia of the nasopharynx. *Virchows Archiv* 1999;434(5):455-7.
- 7) Takano KI, Sato J, Shirasaki H, Yamazaki N, Hoki K, Himi T. Mel-

- anin pigmented oncocytic metaplasia of the nasopharynx. *Auris Nasus Larynx* 2004;31(2):161-3.
- 8) Kurihara K, Nakagawa K. Pigmented variant of benign oncocytic lesion of the pharynx. *Pathology International* 1997;47(5):315-7.
 - 9) Sakaki M, Shek TWH, Hirokawa M, Kashima K, Daa T, Gamachi A, et al. Melanotic oncocytic metaplasia of the nasopharynx: a report of seven cases and review of the literature. *Virchows Archiv* 2004;444(4):345-9.
 - 10) Liao CT, Kuo TT. Melanotic Oncocytic Metaplasia of the Nasopharynx. *International Journal of Surgical Pathology* 2005;13(3):279.
 - 11) Lui PCW, Chan ABW, Chan KF, Choi CH, Tse GMK. Melanocytic and non-melanocytic oncocytic metaplasia of the nasopharynx. *Pathology* 2004;36(5):504-5.
 - 12) Li Y, Lu ZH, Lü W, Chen J. Images for diagnosis. Melanotic oncocytic metaplasia of nasopharynx: a case report with review. *Chin Med J (Engl)* 2010;123(9):1230-2.
 - 13) Kondo T, Mori K, Oka S, Morinaka S. Melanotic oncocytic metaplasia of the nasopharynx as a benign mimicker of malignant melanoma: a case report. *Diagnostic Pathology* 2010;5:5.
 - 14) Na JY, Kim YH, Choi YD, Lee JS. Melanotic oncocytic metaplasia of the nasopharynx: a report of three cases and review of the literature. *Korean Journal of Pathology* 2012;46(2):201-4.
 - 15) Chang IW, Wang CC, Liu KW, Lan CH, Hung CH. Melanotic oncocytic metaplasia of the nasopharynx. *Polish Journal of Pathology* 2014;65(2):162-5.
 - 16) Uehara K, Usami Y, Imai Y, Shimizu M. Melanotic oncocytic metaplasia of the nasopharynx. *Pathology International* 2015;65(3):144-7.
 - 17) Li JJX, Ng JKM, Chan ABW. Clinicopathological features of melanotic and non-melanotic oncocytic lesions of the nasopharynx. *Pathology* 2019;51(6):600-4.
 - 18) Chen HY, Gule MF, Chang IW. Melanotic oncocytic metaplasia of the nasopharynx: a case report with review of literature. *Ear Nose Throat J* 2020;145561320907427.