

Histomorphometric analysis of microcrack healing after the installation of mini-implants

Soobin Shin, Pan-Soo Park, Seung-Hak Baek, Il-Hyung Yang*

Department of Orthodontics and Dental Research Institute, Seoul National University School of Dentistry, Seoul, Korea

pISSN 2093-2278
eISSN 2093-2286



JPIS >
Journal of Periodontal
& Implant Science

Research Article

J Periodontal Implant Sci 2015;45:62-68
<http://dx.doi.org/10.5051/jpis.2015.45.2.62>

Purpose: The goal of this study was to investigate the histomorphometric characteristics of the healing process of microcracks in the cortical bone after the installation of mini-implants (MIs).

Methods: Self-drilling MIs were inserted into the tibial diaphysis of twelve adult male New Zealand rabbits. Four MIs per rabbit were placed randomly. The animals were divided into four groups according to the length of the healing period: group A was sacrificed immediately, group B was sacrificed after one week, group C was sacrificed after two weeks, and group D was sacrificed after four weeks. Cortical bone thickness was measured using micro-computed tomography, and histomorphometric analyses of the cumulative length of the microcracks (CLCr) and the total number of microcracks (NCr) were performed using hematoxylin and eosin staining.

Results: The microcracks were radially and concentrically aligned in the peri-MI bone. The CLCr decreased significantly one week after the surgery, mainly due to healing of the concentrically aligned microcracks. The CLCr showed another significant decrease from two weeks after the surgery to four weeks after the surgery, mainly reflecting healing of the radially aligned microcracks. A statistically significant decrease in the NCr occurred as the microcracks healed from zero weeks to two weeks. However, no significant difference in the NCr was found between groups C and D.

Conclusions: In order to improve the primary stability of MIs, delayed loading and a healing period of a certain length are recommended to ensure the optimal healing of microcracks and bone remodeling.

Keywords: Bone remodeling, Orthodontic anchorage procedures.

Received: Mar. 18, 2015

Accepted: Apr. 19, 2015

*Correspondence:

Il-Hyung Yang
Department of Orthodontics and Dental Research
Institute, Seoul National University School of
Dentistry, 101 Daehak-ro, Jongno-gu,
Seoul 110-749, Korea
E-mail: drortho@snu.ac.kr
Tel: +82-2-2072-4701
Fax: +82-2-2072-3817

INTRODUCTION

Anchorage is the source of resistance to the forces that are generated in reaction to the active component of an appliance, and it plays a very important role in orthodontic treatment [1]. Recently, various skeletal anchorage systems including endosseous implants, mini-implants, and mini-plates have entered into clinical use. Among them, mini-implants (MIs, also known as temporary anchorage devices) are most frequently used due to their ease of installation [2].

The successful installation of MIs is influenced by the skeletal pattern of the patient, immediate or late loading, oral hygiene, and the shape of the MI [3,4], and success rates ranging from 84% to over 90% have been reported in several studies [5,6]. While MIs are very

This is an Open Access article distributed under the terms of the Creative Commons Attribution Non-Commercial License (<http://creativecommons.org/licenses/by-nc/3.0/>).

similar to dental implants, they are different in that some MIs do not exhibit osseointegration with the surrounding bone. Therefore, the primary stability of an MI, also known as its initial stability, is more important for the successful installation of MIs than it is for the installation of dental implants.

The primary stability of an MI is achieved by mechanical coherence between the bone and the MI immediately after installation, while secondary stability is achieved after healing, by means of a process in which osteoblasts form fibrous and lamellar bone around the inserted MI. The factors affecting primary stability are bone density, surgical technique, and the morphology of the MI [7-10], which have also been studied in the context of dental implants [11-13]. After a certain period of healing, secondary stability plays a more important role. The transition process between primary and secondary stability is critical, because anchorage stability depends on the completion of bone remodeling. Studies investigating primary stability have mainly dealt with macroscopic and clinical factors; however, little is known about the relationship between macroscopic factors and histologic reactions. There are a limited number of studies which have suggested that microcracks and microdamage are the factors affecting the primary stability of MIs [10,14]. Furthermore, microcracks play an important role in bone physiology because they induce remodeling of the cortical bone [15-17]. Therefore, the quantification of microcracks, along with bone mass measurements, has been suggested to be a useful technique in then experimentally estimation of the degree of bone remodeling [18].

A relationship between the diameter of an MI and the emergence of microcracks after installation has been reported in previous studies, although no consensus has been reached. Other studies have demonstrated different dynamics of microcrack generation in a range of installation methods including self-drilling, self-tapping, and pilot drilling installation [19,20].

Although MIs are widely used, the effect of microcracks on primary stability is still insufficiently studied. Moreover, to the best of our knowledge, no studies have investigated how microcracks generated during the installation procedure heal. The purpose of this study was to investigate the histomorphometric characteristics of the healing process of microcracks in the cortical bone after the installation of MIs.

MATERIALS AND METHODS

Twelve mature New Zealand white rabbits (males; mean age, six months; mean weight, 3.1 kg) were used according to a protocol that was approved by the Animal Ethics Committee of Seoul National University (SNU-100831-1).

Cylindrically shaped self-drilling MIs (titanium-aluminum-vanadium alloy; Biomaterials Korea, Seoul, Korea), 1.5 mm in diameter and 6 mm in length, were used (total number of MIs=48). In order to exclude the possible effect of extraneous factors on microcrack formation, the design, diameter, and length of the MIs were identical and a single company was used.

All rabbits were randomly assigned to one of four groups, using a round-robin method [21]: the immediate sacrifice group, the one-week healing group, the two-week healing group, and the four-week healing group. Four MIs were placed in the tibia of each rabbit.

The rabbits were anesthetized and an operation field was prepared on the medial side of the upper portion of the hind leg by shaving the fur and disinfecting the area with povidone iodine. Local anesthesia was performed with 2% lidocaine hydrochloride and 1:100,000 epinephrine (Gwangmyung, Seoul, Korea). After a full-thickness stab incision was made on the target site in the proximal third of the tibia, an MI was placed on the site via a surgical device (Elcomed SA-200C, W&H Dentalwerk, Bürmoos, Austria). The insertion settings involved a maximum torque of 30 cN and 20 rpm. Two MIs were placed on each side, with a minimum distance of 2 cm between them. After the operation, all rabbits were administered antibiotics and anti-inflammatory medication. The rabbits were sacrificed at zero days (group A), one week (group B), two weeks (group C), and four weeks (group D) after surgery. Two 2-cm long bone segments containing the MIs were cut from each tibia. Each specimen contained one MI in the central region. However, two rabbits were lost during the healing period and three specimens were abandoned during the harvesting procedure because of spontaneous fracture. In order to prevent additional microcracks during the removal of the MI, specimens were prepared with the MIs in situ. Subsequently, the cortical bone thickness adjacent to the MI was measured using micro-computed tomography (1072 X-ray microtomography, Skyscan, Antwerp, Belgium) and a computed tomography analyzer (version 16.1, Skyscan, Antwerp, Belgium). The bone density of each specimen, expressed in Hounsfield units, was examined to see whether it was between 1,200 and 1,600 [22], which is known to be the normal human range; rabbits have similar cortical bone density values to humans [23].

The blocks were fixed with 4% paraformaldehyde for three weeks, dehydrated with gradient alcohol (90%, 90%, 95%, and 100% alcohol for one day each) and embedded in Kleer set resin TM (Metprep Ltd., Coventry, UK). They were then sliced. The specimens were ground perpendicular to the MI to a thickness of 40–50 µm using the EXAKT cutting and grinding system (EXAKT Apparatebau, Norderstedt, Hamburg, Germany) and stained with hematoxylin and eosin (H&E). Ten consecutive sections were prepared for each specimen and the middle two sections were selected for observation.

Histomorphologic and histomorphometric observations were performed using a microscope and Image J software (version 1.49a, National Institutes of Health, Bethesda, Maryland, USA). The total number of cracks (NCr, reflecting the number of cracks at least 50 µm long) and the cumulative length of the cracks (CLCr) were measured using a protocol described in a previous study [10] (Fig. 1).

Differences in mean values among the four groups were compared using the Kruskal-Wallis test and the Mann-Whitney *U* test with the Bonferroni correction, in order to investigate changes in the microcracks depending on the length of healing.

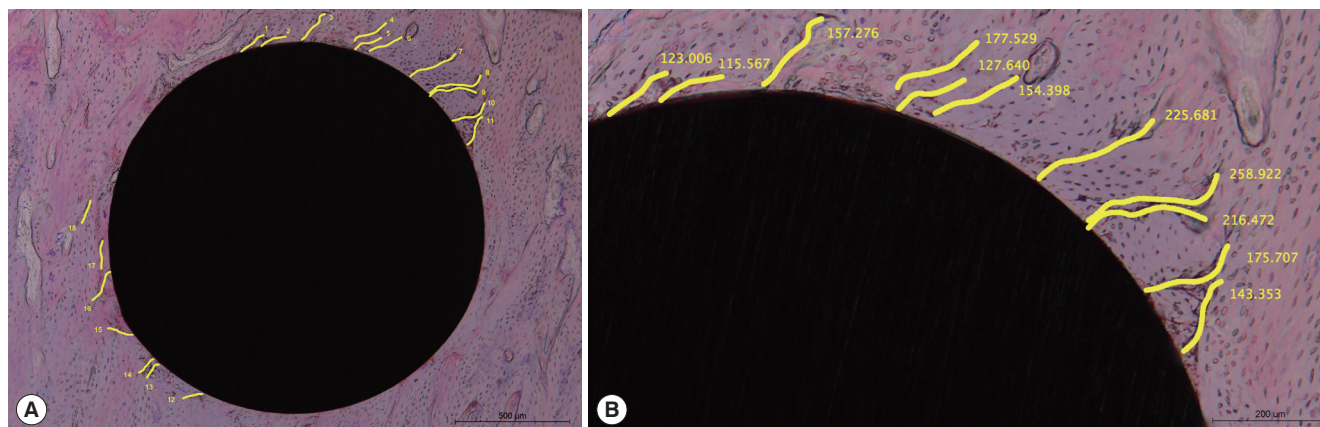


Figure 1. Microcracks in peri-mini-implant bone and the variables measured in this study. (A) The number of microcracks (NCr). (B) The cumulative length of microcracks (CLCr). The scale bars represent 500 µm (A) and 200 µm (B).

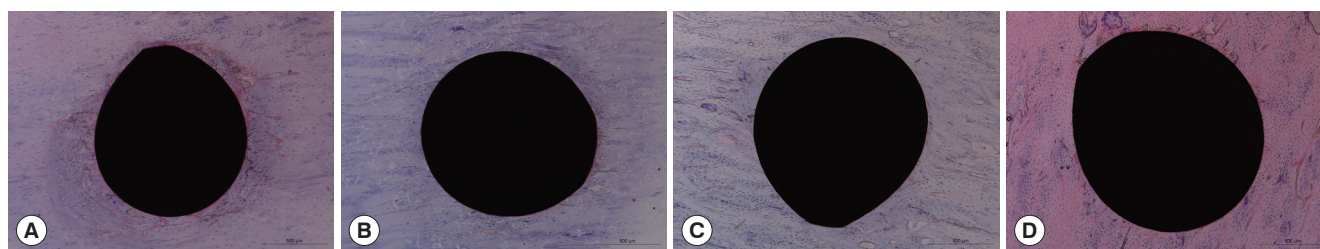


Figure 2. Examples of microcracks in peri-mini-implant bone. (A) The no healing group. (B) The one-week healing group. (C) The two-week healing group. (D) The four-week healing group. The scale bars in all panels represent 500 µm.

RESULTS

Histomorphologic analysis

As visualized by H&E staining, microcracks were radially or concentrically aligned in the peri-MI bone area. Microdamage was mainly seen in two opposite sides that formed an axis, and was rarely found in the other two areas perpendicular to that axis. Although it was not reliably distinguishable, diffuse damage appeared to be found in the peri-MI bone and linear microcracks seemed to propagate from the surface of the MI. The linear microcracks had various lengths, and some of them even originated at some distance from the surface of the MI. Many ruptured osteocyte lacunae could be found adjacent to the MI (Fig. 2).

Although no distinguishable difference was found between groups B and C, long linear microcracks were found to disappear as the healing process continued from zero to four weeks after the surgery. When groups A and B were compared, concentrically aligned microcracks were found to have undergone a significant decrease prior to the radially aligned microcracks. A decrease in the radially aligned microcracks was noted in groups C and D, in comparison with groups A and B. It was also noted that microcracks starting from the surface of the MI was more hardly found in group D than in group A (Fig. 2).

Table 1. Comparison of cortical bone thickness among the four groups.

Healing group	Cortical bone thickness (mm)		P-value
	Mean	SD	
Group A (n=11)	0.70	0.18	0.420
Group B (n=11)	0.72	0.16	
Group C (n=8)	0.72	0.18	
Group D (n=6)	0.78	0.19	

The Kruskal-Wallis test was performed. P-values less than 0.05 were considered to indicate statistical significance.

Group A, immediate sacrifice; group B, one-week healing period; group C, two-week healing period; group D, four-week healing period.

SD: standard deviation.

Histomorphometric analysis

All specimens showed values of bone density within the normal range, between 1,200 and 1,600 Hounsfield units (data not shown). No significant differences were found in the thickness of the cortical bone among the four groups (Table 1).

The CLCr tended to decrease as the healing time increased, although a statistically significant difference was not found between groups B and C ($P=0.129$). However, statistically significant decreases in the CLCr were found between groups A and B and between groups C and D ($P<0.001$) (Table 2 and Fig. 3).

Table 2. Comparison of the cumulative length of microcracks according to the length of the healing period.

Healing group	Cumulative length (μm)		P-value	Multiple comparison		
	Mean	SD		Group B	Group C	Group D
Group A (n = 11)	7566.81	556.08	<0.01 ^{a)}	<0.001 ^{b)}	<0.001 ^{b)}	<0.001 ^{b)}
Group B (n = 11)	3570.80	373.76			0.129	<0.001 ^{b)}
Group C (n = 8)	3228.15	435.24				<0.001 ^{b)}
Group D (n = 6)	865.23	36.30				

Group A, immediate sacrifice; group B, one-week healing period; group C, two-week healing period; group D, four-week healing period.
SD: standard deviation.

^{a)}The Kruskal-Wallis test, ^{b)}The Mann-Whitney *U* test with the Bonferroni correction for multiple tests. *P*-values <0.001 (that is, 0.01/4C₂) were considered to indicate statistical significance in the multiple comparisons.

Table 3. Comparison of the number of microcracks according to the length of the healing period.

Healing group	Number of cracks		P-value	Multiple comparison		
	Mean	SD		Group B	Group C	Group D
Group A (n = 11)	33.00	3.19	<0.01 ^{a)}	<0.001 ^{b)}	<0.001 ^{b)}	<0.001 ^{b)}
Group B (n = 11)	20.55	1.75			<0.001 ^{b)}	<0.001 ^{b)}
Group C (n = 8)	14.75	1.67				0.036
Group D (n = 6)	12.50	1.52				

Group A, immediate sacrifice; group B, one-week healing period; group C, two-week healing period; group D, four-week healing period.
SD: standard deviation.

^{a)}The Kruskal-Wallis test, ^{b)}The Mann-Whitney *U* test with the Bonferroni correction for multiple tests. *P*-values < 0.001 (that is, 0.01/4C₂) were considered to indicate statistical significance in the multiple comparisons.

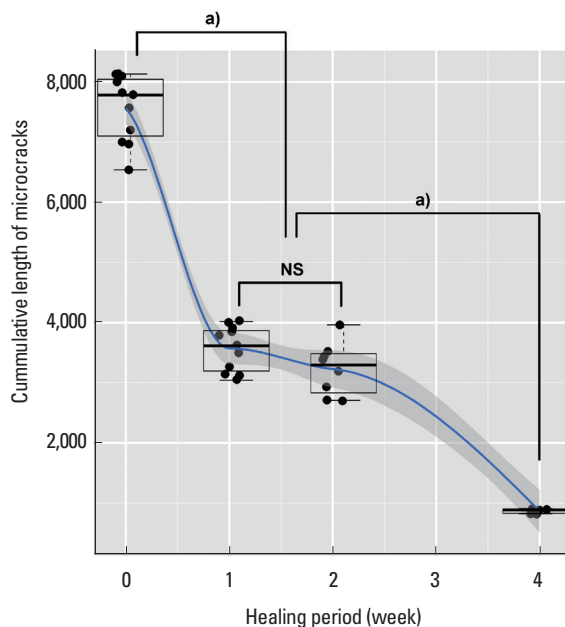


Figure 3. Comparison of the cumulative length of microcracks among groups according to the length of the healing period. ^{a)}A statistically significant difference (*P*<0.001), NS: not significant.

However, the NCr showed a different pattern of change. A statistically significant decrease in the NCr was observed as the heal-

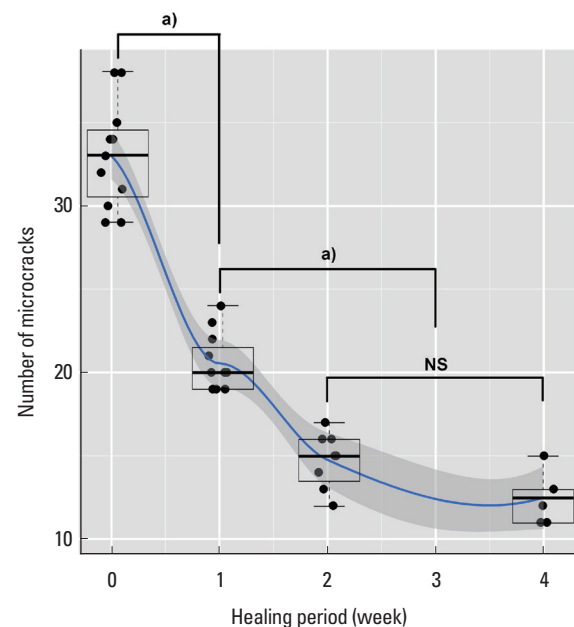


Figure 4. Comparison of the number of microcracks among groups according to the length of the healing period. ^{a)}A statistically significant difference (*P*<0.001), NS: not significant.

ing time increased from zero to two weeks (i.e., among groups A, B, and C; *P*<0.001), but no significant change in the NCr was found

after two weeks (i.e., between groups C and D, $P=0.036$) (Table 3 and Fig. 4).

DISCUSSION

Although microdamage due to fatigue stress in normal cortical bone or after the installation of cortical bone screws or dental implants has been well studied by many researchers [24–26], little is known about microdamage after the installation of MIs. Furthermore, little is known about the repair or healing of microdamage induced by cortical bone screws, dental implants, and MIs. A limited number of studies have performed histomorphometric analysis on the microdamage around MIs; however, most of these studies analyzed microdamage immediately after the installation, evaluated the effects of MI design or different pre-drilling procedures, and mainly dealt with bone-to-implant contact [7,10,19,27,28]. In one of these studies, the researchers took direct histomorphometric measurements of the microdamage as the healing period progressed and found that four weeks of healing were necessary for the microdamage to be repaired [29]. However, that study dealt with cortical bone screws installed after a pre-drilling procedure, which is more common in orthopedic surgery than in orthodontic treatments. In this study, microdamage around self-drilling MIs without a pre-drilling procedure was observed histomorphometrically, with a focus on the effect of the duration of the healing period. Direct measurements of the microcracks were used for histomorphometric analysis because doing so is a more intuitive way of assessing primary stability than measuring the formation of osteoclasts, osteoblasts, or new bone.

The gross pattern of microcracks showed both concentric and radial alignment, unlike what has been reported in previous studies [19,29]. This discrepancy occurred primarily because the sections were viewed differently. The cross-section which was perpendicular to the long axis of the MI was used for analysis in this study, whereas the sagittal section that runs parallel to the long axis of the MI was used in other studies. Concentrically aligned microcracks cannot be observed in sagittal specimens, due to their orientation. Although it would be better to examine the specimen along the long axis of the MI in order to observe bone-to-implant contact or histologic reactions in the cancellous bone, specimens perpendicular to the long axis of the MI better illustrate microcracks in the peri-MI cortical bone and their repair.

Concentric microcracks were most frequently observed in group A. During the installation procedure of self-drilling MIs, large concentric microcracks are quickly formed due to the release of high torque energy, causing the rupture of microstructures in the osteonal cortical bone. These microcracks seemed to be more destructive than radial microcracks. However, the concentric microcracks were reduced in number after only one week of healing (group B), while the radial microcracks were still prominent after the same healing period. It appeared that the healing process repaired the more destructive concentric microcracks before repairing the less destruc-

tive radial microcracks. Concentric microcracks were barely observable in the specimens after four weeks of healing (group D). Some previous studies have described the repair of microcracks after four weeks [27–29]. Since a consensus exists that rupture of the osteocyte lacunae and canaliculi is essential for the repair of microdamage [30,31], the concentric microcracks were more prone to be repaired than the radial microcracks because they destroyed the microstructure of osteons in the cortical bone to a greater extent than the radial microcracks.

As a result of the prominent repair of the concentric microcracks, the CLCr showed a statistically significant decrease after one week. A plateau of sorts in the CLCr occurred between one and two weeks of healing (groups B and C). During that period, the differentiation of osteoblasts and the formation of new bone seemed to occur, but no significant change in the CLCr was observed. The repair process starts with the recruitment of osteoclasts at the focal site of the microcrack, forming a resorptive cutting cavity, and is followed by the emergence of a closed cavity with osteoblasts and new bone [32]. After four weeks, the microcracks were replaced by new bone, and the CLCr showed another significant decrease (Fig. 2, 3).

The NCr showed a different pattern of changes than the CLCr. The NCr was significantly reduced by two weeks after the beginning of the healing process and did not change significantly thereafter (groups C and D). During the repair process of the microcracks, the repair foci of the osteoclasts and osteoblasts on the microcracks segmented large linear microcracks into small microcracks [33,34]. The repair process yielded more segments of microcracks after a certain period of healing (two weeks in this study), because large linear microcracks fragmented into several small microcracks, which were countable separately, and therefore no difference was found in the NCr between groups C and D. This explanation is also supported by the observation that the number of microcracks that originated away from the surface of the MI increased after two weeks of healing (groups C and D) (Fig. 2, 4).

Repair process seemed to occur first in large microcracks ahead of minor microcracks by a mechanism that began with the rupture of osteocyte lacunae. Microdamage away from the installation site needed more time to be repaired due to the absence of an initiation event like that observed in the peri-MI area.

In conclusion, the stability of MIs can be enhanced by ensuring a healing period after installation and allowing the repair of microdamage, which would improve primary stability.

Further studies are required to investigate the possible influence of other parameters such as MI design, self-tapping installation, wobbling during installation, and immediate loading. It is also necessary to investigate the correlation between mechanical stability and histologic findings with regard to the healing of microdamage.

CONFLICT OF INTEREST

No potential conflict of interest relevant to this article was reported.

ACKNOWLEDGEMENTS

The research was supported by the Research Settlement Fund for the new faculty of Seoul National University and the International Research & Development Program of the National Research Foundation of Korea (NRF), funded by the Ministry of Science, ICT & Future Planning (Grant number: 2014K1A3A1A21001365).

ORCID

Soobin Shin <http://orcid.org/0000-0001-9308-6672>
Pan-Soo Park <http://orcid.org/0000-0001-8869-2715>
Seung-Hak Baek <http://orcid.org/0000-0002-6586-9503>
Il-Hyung Yang <http://orcid.org/0000-0001-6398-4607>

REFERENCES

- Proffit WR, Fields HW. Mechanical principles in orthodontic force control. In: Contemporary orthodontics. 3rd ed. St. Louis (MO): Mosby; 2000. p.326-62.
- Carano A, Velo S, Leone P, Siciliani G. Clinical applications of the Miniscrew Anchorage System. *J Clin Orthod* 2005;39:9-24.
- Miyawaki S, Koyama I, Inoue M, Mishima K, Sugahara T, Takano-Yamamoto T. Factors associated with the stability of titanium screws placed in the posterior region for orthodontic anchorage. *Am J Orthod Dentofacial Orthop* 2003;124:373-8.
- Cheng SJ, Tseng IY, Lee JJ, Kok SH. A prospective study of the risk factors associated with failure of mini-implants used for orthodontic anchorage. *Int J Oral Maxillofac Implants* 2004;19:100-6.
- Park HS, Jeong SH, Kwon OW. Factors affecting the clinical success of screw implants used as orthodontic anchorage. *Am J Orthod Dentofacial Orthop* 2006;130:18-25.
- Wiechmann D, Meyer U, Büchter A. Success rate of mini- and micro-implants used for orthodontic anchorage: a prospective clinical study. *Clin Oral Implants Res* 2007;18:263-7.
- Brinley CL, Behrents R, Kim KB, Condoor S, Kyung HM, Buschang PH. Pitch and longitudinal fluting effects on the primary stability of miniscrew implants. *Angle Orthod* 2009;79:1156-61.
- Florvaag B, Kneuert P, Lazar F, Koebke J, Zöller JE, Braumann B, et al. Biomechanical properties of orthodontic miniscrews. An in-vitro study. *J Orofac Orthop* 2010;71:53-67.
- Cha JY, Kil JK, Yoon TM, Hwang CJ. Miniscrew stability evaluated with computerized tomography scanning. *Am J Orthod Dentofacial Orthop* 2010;137:73-9.
- Lee NK, Baek SH. Effects of the diameter and shape of orthodontic mini-implants on microdamage to the cortical bone. *Am J Orthod Dentofacial Orthop* 2010;138:8.e1-8.
- Moon SH, Um HS, Lee JK, Chang BS, Lee MK. The effect of implant shape and bone preparation on primary stability. *J Periodontal Implant Sci* 2010;40:239-43.
- Bartold PM, Kuliwaba JS, Lee V, Shah S, Marino V, Fazzalari NL. Influence of surface roughness and shape on microdamage of the osseous surface adjacent to titanium dental implants. *Clin Oral Implants Res* 2011;22:613-8.
- Shin SY, Shin SI, Kye SB, Chang SW, Hong J, Paeng JY, et al. Bone cement grafting increases implant primary stability in circumferential cortical bone defects. *J Periodontal Implant Sci* 2015;45:30-5.
- Liu SS, Cruz-Marroquin E, Sun J, Stewart KT, Allen MR. Orthodontic mini-implant diameter does not affect in-situ linear microcrack generation in the mandible or the maxilla. *Am J Orthod Dentofacial Orthop* 2012;142:768-73.
- Herman BC, Cardoso L, Majeska RJ, Jepsen KJ, Schaffler MB. Activation of bone remodeling after fatigue: differential response to linear microcracks and diffuse damage. *Bone* 2010;47:766-72.
- Chapurlat RD, Delmas PD. Bone microdamage: a clinical perspective. *Osteoporos Int* 2009;20:1299-308.
- Carter DR, Hayes WC. Compact bone fatigue damage: a microscopic examination. *Clin Orthop Relat Res* 1977:265-74.
- Lee TC, Mohsin S, Taylor D, Parkesh R, Gunnlaugsson T, O'Brien FJ, et al. Detecting microdamage in bone. *J Anat* 2003;203:161-72.
- Taing-Watson E, Katona TR, Stewart KT, Ghoneima A, Chu GT, Kyung HM, et al. Microdamage generation by tapered and cylindrical mini-screw implants after pilot drilling. *Angle Orthod*. Forthcoming 2014.
- Yadav S, Upadhyay M, Liu S, Roberts E, Neace WP, Nanda R. Microdamage of the cortical bone during mini-implant insertion with self-drilling and self-tapping techniques: a randomized controlled trial. *Am J Orthod Dentofacial Orthop* 2012;141:538-46.
- Zar JH. Biostatistical analysis. 2nd ed. Englewood Cliffs (NJ): Prentice Hall International; 1984.
- Chugh T, Ganeshkar SV, Revankar AV, Jain AK. Quantitative assessment of interradicular bone density in the maxilla and mandible: implications in clinical orthodontics. *Prog Orthod* 2013;14:38.
- Wang X, Mabrey JD, Agrawal CM. An interspecies comparison of bone fracture properties. *Biomed Mater Eng* 1998;8:1-9.
- Martin RB. Osteonal remodeling in response to screw implantation in canine femora. *J Orthop Res* 1987;5:445-52.
- Huja SS, Katona TR, Burr DB, Garetto LP, Roberts WE. Microdamage adjacent to endosseous implants. *Bone* 1999;25:217-22.
- Eraslan O, Inan O. The effect of thread design on stress distribution in a solid screw implant: a 3D finite element analysis. *Clin Oral Investig* 2010;14:411-6.
- Wu J, Bai YX, Wang BK. Biomechanical and histomorphometric characterizations of osseointegration during mini-screw healing in rabbit tibiae. *Angle Orthod* 2009;79:558-63.
- Zhang L, Zhao Z, Li Y, Wu J, Zheng L, Tang T. Osseointegration of orthodontic micro-screws after immediate and early loading. *Angle Orthod* 2010;80:354-60.
- Wang L, Ye T, Deng L, Shao J, Qi J, Zhou Q, et al. Repair of microdamage in osteonal cortical bone adjacent to bone screw. *PLoS One* 2014;9:e89343.
- Schaffler MB. Role of bone turnover in microdamage. *Osteoporos Int* 2009;19:1299-308.

- ros Int 2003;14 Suppl 5:S73-7.
31. Hazenberg JG, Freeley M, Foran E, Lee TC, Taylor D. Microdamage: a cell transducing mechanism based on ruptured osteocyte processes. *J Biomech* 2006;39:2096-103.
32. Martin RB. Targeted bone remodeling involves BMU steering as well as activation. *Bone* 2007;40:1574-80.
33. Parfitt AM. The mechanism of coupling: a role for the vasculature. *Bone* 2000;26:319-23.
34. Eriksen EF. Cellular mechanisms of bone remodeling. *Rev Endocr Metab Disord* 2010;11:219-27.