

Esthetic evaluation of maxillary single-tooth implants in the esthetic zone

Hae-Lyung Cho, Jae-Kwan Lee, Heung-Sik Um, Beom-Seok Chang*

Department of Periodontology, Gangneung-Wonju National University College of Dentistry, Gangneung, Korea

Purpose: The aim of this study is to assess the influence exerted by the observer's dental specialization and compare patients' opinion with observers' opinion of the esthetics of maxillary single-tooth implants in the esthetic zone.

Methods: Forty-one adult patients, who were treated with a single implant in the esthetic zone, were enrolled in this study. Eight observers (2 periodontists, 2 prosthodontists, 2 orthodontists and 2 senior dental students) applied the pink esthetic score (PES)/white esthetic score (WES) to 41 implant-supported single restorations twice with an interval of 4 weeks. We used a visual analog scale (VAS) to assess the patient's satisfaction with the treatment outcome from an esthetic point of view.

Results: In the PES/WES, very good and moderate intraobserver agreements were noted between the first and second rating. The mean total PES/WES was 11.19 ± 3.59 . The mean PES was 5.17 ± 2.29 and mean WES was 6.02 ± 1.96 . In the total PES/WES, the difference between the groups was not significant. However, in the WES, the difference between the groups was significant and prosthodontists were found to have assigned poorer ratings than the other groups. Periodontists gave higher ratings than prosthodontists and senior dental students. Orthodontists were clearly more critical than the other observers. The statistical analysis revealed statistically significant correlation between patients' esthetic perception and dentists' perception of the anterior tooth. However, the correlation between the total PES/WES and the VAS score for the first premolar was not statistically significant.

Conclusions: The PES/WES is an objective tool in rating the esthetics of implant supported single crowns and adjacent soft tissues. Orthodontists were the most critical observers, while periodontists were more generous than other observers. The statistical analysis revealed a statistically significant correlation between patients' esthetic perception and dentists' perception of the anterior tooth.

Keywords: Dental esthetics, Patient satisfaction, Single-tooth dental implants.

INTRODUCTION

With a history of nearly 50 years, dental implants have gained a high reputation due to their high success rate. Numerous studies [1-4] have reported similar implant survival and success rates for implants inserted in the esthetic zone compared to those placed in other segments of the jaws.

Albrektsson's criteria for success [5] are considered to be

well-established and are widely used in clinical studies as a 'rule' for analyzing the success rate. For esthetically sensitive cases, however, these osseointegration-oriented criteria are not adequate. With osseointegration and restoration of function, patient satisfaction is a key factor in the success of implant therapy, especially in the anterior maxilla [6]. Therefore, Smith and Zarb [7] extended the criteria by emphasizing that a successful implant must allow for an adequately esthetic

Received: May. 20, 2010; Accepted: Jul. 23, 2010

*Correspondence: Beom-Seok Chang

Department of Periodontology, Gangneung-Wonju National University College of Dentistry, 123 Jibyeon-dong, Gangneung 210-702, Korea

E-mail: dentist@gwnu.ac.kr, Tel: +82-33-640-3188, Fax: +82-33-640-3113

appearance.

In 2005, Furhauser et al. [8] proposed an excellent index termed the pink esthetic score (PES), focusing essentially on the soft tissue aspects of an anterior implant restoration. This PES is based on seven variables: mesial papilla, distal papilla, soft-tissue level, soft-tissue contour, alveolar process deficiency, soft-tissue color, and texture [8]. Each variable is assessed with a 2-1-0 score, with 2 being the best and 0 being the poorest score, which results in a maximum possible score of 14 [8]. Furhauser et al. [8] suggested that the PES is a suitable instrument for reproducibly evaluating soft tissue around single-tooth implant crowns that might change over time and could be a useful tool for monitoring long-term soft-tissue alterations. Belser et al. [9] modified the previously published PES [8] and proposed an implant restoration index (white esthetic score, WES) in analyzing a single-tooth implant. In contrast to the original proposal, the PES/WES by Belser et al. [9] comprises the five variables. The suitability of the PES/WES index for the objective outcome assessment of the esthetic dimension of anterior single-tooth implants was confirmed [8-10].

We applied the PES/WES index for objective evaluation of single tooth implants. Furthermore, we used a visual analog scale (VAS) to assess the patient's subjective satisfaction with the treatment outcome from an esthetic point of view.

The aim of this study was to assess the influence exerted by the observer's dental specialization and compare patients' evaluations with observers' evaluations of the esthetics of single-tooth implants in the esthetic zone.

MATERIALS AND METHODS

Study population

Forty-one patients, 25 males and 16 females, who had been treated with single-tooth implants at the Department of Periodontics, Gangneung-Wonju National University Dental Hospital, between January 2001 and July 2009 were included in this study (Table 1). Forty-one implants were placed in the esthetic zone (incisors, canines or first premolars), including 13 central incisors, 10 lateral incisors, 3 canines, and 15 first premolars (Fig. 1).

The reasons for extraction of natural teeth are summarized in Table 2. The subsequent prosthetic procedures were carried out by referral to the Department of Prosthodontics. The implant crowns were mainly fabricated in a dental laboratory of

Gangneung-Wonju National University Dental Hospital. All patients signed a consent form to participate in this study. Approval for this study was granted by the Institutional Review Board, Gangneung-Wonju National University Dental Hospital (IRB 2009-14-2).

Follow-up examination

The calibrated observers consisted of two periodontists, two prosthodontists, two orthodontists, and two senior dental students. The questionnaires were handed to 8 observers in order to assess WES and PES scoring.

To objectively examine the esthetic outcome of the implants, the study casts and intraoral photographs were critically analyzed by eight observers according to two specific indices, the PES and WES, each with five parameters. Each implant site was scored together, following the order of the 10 PES/WES parameters. Assessments were made twice with an interval of 4 weeks. To reduce the bias from the first viewing, the order of the photographs were reversed for the second viewing.

Cast analysis

The study casts were evaluated to facilitate the objective appreciation of the crown outline, volume, and surface texture, in addition to root convexity and soft tissue texture. A pair of study casts, produced in type IV stone, were fabricated for each

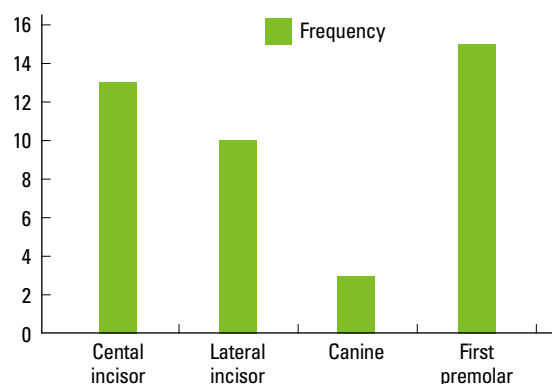


Figure 1. Distribution of implant regions.

Table 2. The reasons for extraction of natural teeth.

Reasons for tooth extraction	Frequency
Periodontal disease	16
Root fracture	12
Caries	6
Root resorption	3
Periapical infection	2
Impaction	1
Malformed tooth	1

Table 1. Distribution of patients' age and gender.

Subjects	
Age (years)	19-70 (mean, 46)
Gender (male/female)	25/16

of the 41 patients to facilitate a direct, objective assessment related to the PES/WES index.

Clinical photographs

Each implant was photographed with a digital camera (D80, Nikon, Tokyo, Japan) and a 105 mm lens (AF-S VR Micro-Nikor 105 mm f/2.8G IF-ED, Nikon, Tokyo, Japan) with a ring flash (EM-140 DG, SIGMA, Kawasaki, Japan).

Photographs were taken at or slightly superior to the occlusal plane, centered at the contact region. For assessing anterior tooth replacements, the reference tooth had to be visible enough to ensure comparability. Standard clinical photographs ($\times 2$, $\times 1$ magnification) were taken at each implant site and at the contralateral tooth. The implant-supported restorations at the region of the canine were photographed to ensure comparison with the first premolar ($\times 1$ magnification). At the region of the first premolar, standardized photographs had to include a full representation of the second premolar, which served as the reference.

Photographs were transferred to a 42-inch PDP monitor (XCANVAS, LG, Seoul, Korea). The clinical photographs were primarily used to assess general tooth/crown form, tooth/crown color, incisal translucency and characterization, as well as soft tissue color, curvature, and level.

Evaluation of esthetic treatment outcome

Eight observers applied the PES/WES index according to Belser et al. [9].

PES/WES score

A score of 2, 1, or 0 was assigned to each PES/WES Parameters (Tables 3 and 4). Hence, the highest possible combined PES/WES score was 20, which represented a close match of the peri-implant soft tissue conditions and the clinical single-tooth crown compared to the respective features present at the contralateral natural tooth site. The threshold of clinical acceptability was set at 6 for the PES and WES.

Table 3. Assessment criteria-PES.

Parameter	Absent	Incomplete	Complete
Mesial papilla	0	1	2
Distal papilla	0	1	2
	Major discrepancy	Minor discrepancy	No discrepancy
Curvature of facial mucosa	0	1	2
Level of facial mucosa	0	1	2
Root convexity/soft tissue color and texture	0	1	2
Maximum total PES score			10

PES: pink esthetic score.

Visual analog scale analysis

A VAS is a measurement tool that can be applied to evaluate patients' subjective esthetic evaluation [11-13]. Our questionnaire evaluated to patients' satisfaction with the esthetics of an anterior single tooth implant using a VAS at the follow-up examination. We used a horizontal VAS bar 100 millimeters in length, with the left anchor labeled "0" and the right anchor labeled "100." The question addressed specifically the patient's satisfaction with the treatment outcome from an esthetic point of view; the range of possible answers went from "totally unsatisfied=0" to "completely satisfied=100."

The questionnaires were accompanied by simple and precise instructions for use. We provided an example to explain the VAS and asked the patients to precisely mark on a calibrated horizontal line his or her specific degree of esthetic satisfaction with single-tooth implant treatment.

Statistical analysis

All statistical analyses were performed using statistical software (SPSS™, SPSS Inc., Chicago, IL, USA). Intraobserver agreements between first and second assessments were evaluated with the weighted Cohen's Kappa (κ). Kappa represents the observed proportion of non-chance agreement. The differences in the PES, WES and total PES/WES among the specialty groups were assessed with the Kruskal Wallis analysis. The Spearman correlation test was carried out to evaluate the relationship between the VAS and total PES/WES. To provide a graphic description of the results, scatter plots were created. The significance level of the test was set at $P < 0.05$.

RESULTS

PES/WES analysis

The intraobserver agreements by weighted Cohen's κ are listed in Table 5. Overall, very good and moderate agreements were noted between the first and second rating. The greatest agreement of 0.941 was observed for orthodontist 2, and the lowest agreement of 0.526 was observed for senior dental student 2.

Table 4. Assessment criteria-WES.

Parameter	Major discrepancy	Minor discrepancy	No discrepancy
Tooth form	0	1	2
Tooth volume/outline	0	1	2
Color (hue/value)	0	1	2
Surface texture	0	1	2
Translucency	0	1	2
Maximum total WES score			10

WES: white esthetic score.

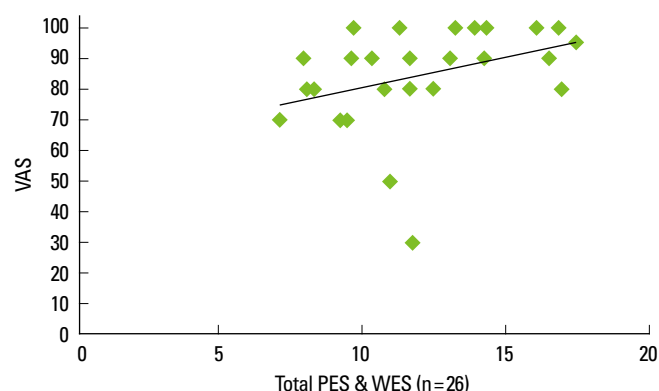


Figure 2. Correlation between the total pink esthetic score (PES)/white esthetic score (WES) and visual analog scale response for the anterior tooth.

Table 5. Intraobserver agreement between the first and second ratings.

Specialty group	Valid (n)	Kappa (κ)	Mean PES	Mean WES	Mean PES/WES
Periodontist 1	410	0.655	5.48 \pm 0.09 ^a	5.90 \pm 0.17	11.38 \pm 0.26
Periodontist 2	410	0.616	5.77 \pm 0.09	7.05 \pm 0.00	12.81 \pm 0.09
Periodontist 1+2			5.62 \pm 0.20	6.47 \pm 0.81	12.10 \pm 1.01
Prosthodontist 1	410	0.670	4.99 \pm 0.02	5.49 \pm 0.10	10.48 \pm 0.09
Prosthodontist 2	410	0.813	5.60 \pm 0.12	5.16 \pm 0.16	10.76 \pm 0.03
Prosthodontist 1+2			5.29 \pm 0.43	5.32 \pm 0.23	10.61 \pm 0.20
Orthodontist 1	410	0.723	4.57 \pm 0.22	6.59 \pm 0.03	11.16 \pm 0.26
Orthodontist 2	410	0.941	4.56 \pm 0.10	5.16 \pm 0.02	9.72 \pm 0.12
Orthodontist 1+2			4.57 \pm 0.00	5.87 \pm 1.00	10.44 \pm 1.00
Senior dental student 1	410	0.838	5.13 \pm 0.09	6.70 \pm 0.22	11.83 \pm 0.31
Senior dental student 2	410	0.526	5.28 \pm 0.19	6.09 \pm 0.02	11.37 \pm 0.17
Senior dental student 1+2			5.20 \pm 0.10	6.39 \pm 0.43	11.60 \pm 0.32
Total group	410		5.17 \pm 0.45	6.02 \pm 0.70	11.18 \pm 0.90

Strength of agreement: <0.2, poor; 0.21-0.4, fair; 0.41-0.6, moderate; 0.61-0.8, good; 0.81-1, very good.

PES: pink esthetic score, WES: white esthetic score.

^aData are shown as mean standard deviation.

The summarized mean total PES/WES scores including the standard deviations of the 41 examined single-tooth implants are presented in Table 5. The mean total PES/WES was 11.19 \pm 0.90. The mean PES was 5.17 \pm 0.45, and mean WES was 6.02 \pm 0.70. The WES was clearly higher than the corresponding PES. The mean PES (5.17 \pm 0.45) scored below the threshold of 6. On the other hand, the mean WES (6.02 \pm 0.70) scored slightly above the threshold of 6.

In the PES, the score for the mesial and distal papilla (mean scores of 0.63 and 0.62) showed the lowest mean score of all five parameters, while in the WES, the score for tooth form and

Table 6. Summarized the PES and WES of the 41 implants.

PES	Mesial papilla	Distal papilla	Curvature of facial mucosa	Level of facial mucosa	Root convexity, soft tissue color and texture	Total PES (Max 10)
Mean	0.63	0.62	1.31	1.33	1.16	5.17
SD	0.12	0.09	0.21	0.13	0.13	0.45
WES	Tooth form	Tooth volume/outline	Color (hue/value)	Surface texture	Translucency and racterization	Total WES (Max 10)
Mean	0.59	0.61	1.22	1.39	1.12	6.02
SD	0.17	0.14	0.16	0.34	0.17	0.70

PES: pink esthetic score, WES: white esthetic score.

Table 7. Correlation between the total PES/WES and VAS response.

Regional group	Valid (n)	Spearman correlation coefficient	Statistical significance (P-value)
Anterior tooth	26	0.472 ^a	0.015 ^a
First premolars	15	0.244	0.381
Anterior tooth+first premolars	41	0.170	0.289

PES: pink esthetic score, WES: white esthetic score, VAS: visual analog scale.

^aStatistical significance ($P < 0.05$).

Table 8. Statistical significance (P) according to Kruskal Wallis analysis among the specialty groups.

	Valid (n)	PES	WES	Total PES/WES
Specialty groups	41	0.143	0.029 ^a	0.119

PES: pink esthetic score, WES: white esthetic score.

^aStatistical significance ($P < 0.05$).

tooth volume/outline (mean scores of 0.59 and 0.61) showed the lowest mean score of all five parameters (Table 6).

Patients' and dental professionals' opinions

In the questionnaires, the patients gave a VAS score of 30 to 100 (mean scores of 86). The Spearman analysis revealed a statistically significant correlation (correlation coefficient=0.472; $P=0.015$) between the total PES/WES and the VAS score of the anterior tooth as shown in Fig. 2. However, the correlation between the total PES/WES and the VAS score for the first premolars was not statistically significant (Table 7).

Effects of specialization

The mean total PES/WES was 12.10 for the periodontists, 10.61 for the prosthodontists, 10.44 for the orthodontists and 11.60 for the senior dental students (Table 5). For the total PES/WES, the difference among the groups was not significant according to the Kruskal Wallis analysis ($P=0.119$). For the WES, the difference among the groups was significant according to the Kruskal Wallis analysis ($P=0.029$, Table 8), and

prosthodontists were found to have assigned poorer ratings than the other groups (Table 5). Periodontists gave relatively higher ratings than prosthodontists and senior dental students. Orthodontists were clearly more critical than the other groups (Table 5).

DISCUSSION

In our study, we demonstrated the intraobserver reproducibility of the PES/WES index with the Kappa test. For the PES/WES, very good and moderate intraobserver agreements were noted. The PES/WES index is a suitable instrument for evaluating the esthetics around single-implant restorations. The PES/WES index could also give a more objective insight into esthetic results in daily practice. Furthermore, the index could be a very useful tool in scientific research.

In the present study, we demonstrated the influence of the observers' dental specialization on their perception of esthetics. For the total PES/WES, the difference among the observer groups was not statistically significant. On the other hand, for the WES, the difference was statistically significant. Prosthodontists were found to have assigned lower WES ratings than the other groups. In other words, prosthodontists were clearly more critical than the other observers in the WES. Periodontists gave higher ratings than prosthodontists and senior dental students. Orthodontists were clearly more critical than the other groups. Furhauser et al. [8] also reported that orthodontists were clearly more critical in their judgments.

Objectively, the esthetic zone was defined as any dentoalveolar segment that is visible upon full smile. Subjectively, the esthetic zone can be defined as any dentoalveolar area of esthetic importance to the patient [14]. Belser et al. [9] evaluated the esthetic outcome of maxillary anterior single-tooth implants using WES/PES. In the study, he reported that no statistically significant correlation was revealed between the PES/WES and VAS scores. However, in our study, the statistical analysis did reveal a statistically significant correlation between patients' esthetic perception and dentists' perception of the anterior tooth. On the other hand, for the first premolar, the statistical analysis did not reveal any statistically significant correlation between patients' esthetic perception and dentists' perception, as mentioned in several other studies [15-19]. This confirms the fact that the patients' esthetic perception of dental restorations differs significantly according to tooth region. The results of the present study highlight the importance of dentists' consideration of the patient's viewpoint when planning and assessing anterior single-tooth implants.

The mean PES was clearly less favorable than the mean WES in this study. This observation is also documented by the fact that the mean PES fell below the threshold of 6, which is the

level of clinical acceptability from the observer's point of view. In addition, the score for the mesial and distal papilla (mean scores of 0.63 and 0.64, respectively) showed the lowest mean score of all five parameters. The scores were less favorable than those found (mean scores of 1.6 and 1.3) by Belser et al. [9]. This differences can be explained by the influence of the timing of implant placement and reasons for tooth extraction. Belser et al. [9] evaluated the esthetic outcome of early placed maxillary anterior single-tooth implants. However, in our study, the implants were placed according to delayed or late placement protocols. Choquet et al. [20] reported that the interproximal crest height determines the presence or absence of peri-implant papilla. In the present study, the most frequent reason of extraction was periodontal disease, which has led to severe marginal bone loss.

In the present study, except for the mesial and distal papilla, the combination variable root convexity/soft tissue color and texture was slightly less favorable than the other parameters. It might be difficult to attain a maximum score for this parameter because it consists of three different aspects to be fulfilled.

If maxillary anterior single-tooth implant therapy is selected, the patient must be informed about the esthetic risk associated with the implant treatment. It is very important to recognize patients who have unrealistic esthetic demands. Because of the complexity of working with hard and soft tissues in implant dentistry, it can be difficult to consistently achieve good esthetics. In our study, one patient who gave VAS score of 30 complained about a black triangular gap where interdental papilla were missing. He could not smile broadly due to this "black triangle." The patient had a thin biotype and high smile line. In general, a patient with the combination of a high lip line and a thin biotype is extremely difficult to treat and should be considered an anatomic risk. Therefore, throughout the consultation, it is appropriate to discretely evaluate the patient's smile line and lip movement during speech [21].

Augmentation of soft tissue masks a defect without addressing the biologic problem and enhances the esthetics of an implant. In this study, three patients who received a connective tissue graft gave a VAS score of 100. Within this study, the connective tissue graft technique showed high patient satisfaction with anterior implant treatment.

In our study, we demonstrated the influence of observer specialization on PES/WES rating and a significant correlation between patients' esthetic perception and dentists' perception of the anterior tooth.

This study has limitations due to the number of observers and implants. Therefore, further studies encompassing a larger number of observers from every dental specialty group and a larger number of implants could help in identifying objective methods of measurement in order to assess esthetic quality.

CONFLICT OF INTEREST

No potential conflict of interest relevant to this article was reported.

REFERENCES

1. Lindh T, Gunne J, Tillberg A, Molin M. A meta-analysis of implants in partial edentulism. *Clin Oral Implants Res* 1998; 9:80-90.
2. Wyatt CC, Zarb GA. Treatment outcomes of patients with implant-supported fixed partial prostheses. *Int J Oral Maxillofac Implants* 1998;13:204-11.
3. Noack N, Willer J, Hoffmann J. Long-term results after placement of dental implants: longitudinal study of 1,964 implants over 16 years. *Int J Oral Maxillofac Implants* 1999; 14:748-55.
4. Naert I, Koutsikakis G, Duyck J, Quirynen M, Jacobs R, van Steenberghe D. Biologic outcome of implant-supported restorations in the treatment of partial edentulism. part I: a longitudinal clinical evaluation. *Clin Oral Implants Res* 2002;13:381-9.
5. Albrektsson T, Zarb G, Worthington P, Eriksson AR. The long-term efficacy of currently used dental implants: a review and proposed criteria of success. *Int J Oral Maxillofac Implants* 1986;1:11-25.
6. Buser D, Martin W, Belser UC. Optimizing esthetics for implant restorations in the anterior maxilla: anatomic and surgical considerations. *Int J Oral Maxillofac Implants* 2004; 19 Suppl:43-61.
7. Smith DE, Zarb GA. Criteria for success of osseointegrated endosseous implants. *J Prosthet Dent* 1989;62:567-72.
8. Furhauser R, Florescu D, Benesch T, Haas R, Mailath G, Watzek G. Evaluation of soft tissue around single-tooth implant crowns: the pink esthetic score. *Clin Oral Implants Res* 2005;16:639-44.
9. Belser UC, Grutter L, Vailati F, Bornstein MM, Weber HP, Buser D. Outcome evaluation of early placed maxillary anterior single-tooth implants using objective esthetic criteria: a cross-sectional, retrospective study in 45 patients with a 2- to 4-year follow-up using pink and white esthetic scores. *J Periodontol* 2009;80:140-51.
10. Gehrke P, Lobert M, Dhom G. Reproducibility of the pink esthetic score--rating soft tissue esthetics around single-implant restorations with regard to dental observer specialization. *J Esthet Restor Dent* 2008;20:375-84.
11. Fardal O, Johannessen AC, Linden GJ. Patient perceptions of periodontal therapy completed in a periodontal practice. *J Periodontol* 2002;73:1060-6.
12. Czochorowska EM, Stenvik A, Bjercke B, Zachrisson BU. Outcome of tooth transplantation: survival and success rates 17-41 years posttreatment. *Am J Orthod Dentofacial Orthop* 2002;121:110-9.
13. Wolfart S, Thormann H, Freitag S, Kern M. Assessment of dental appearance following changes in incisor proportions. *Eur J Oral Sci* 2005;113:159-65.
14. Belser U, Buser D, Higginbottom F. Consensus statements and recommended clinical procedures regarding esthetics in implant dentistry. *Int J Oral Maxillofac Implants* 2004;19 Suppl:73-4.
15. An KY, Lee JY, Kim SJ, Choi JI. Perception of maxillary anterior esthetics by dental professionals and laypeople and survey of gingival topography in healthy young subjects. *Int J Periodontics Restorative Dent* 2009;29:535-41.
16. Flores-Mir C, Silva E, Barriga MI, Lagravere MO, Major PW. Lay person's perception of smile aesthetics in dental and facial views. *J Orthod* 2004;31:204-9.
17. Miller CJ. The smile line as a guide to anterior esthetics. *Dent Clin North Am* 1989;33:157-64.
18. Kokich VO Jr, Kiyak HA, Shapiro PA. Comparing the perception of dentists and lay people to altered dental esthetics. *J Esthet Dent* 1999;11:311-24.
19. Brisman AS. Esthetics: a comparison of dentists' and patients' concepts. *J Am Dent Assoc* 1980;100:345-52.
20. Choquet V, Hermans M, Adriaenssens P, Daelemans P, Tarnow DP, Malevez C. Clinical and radiographic evaluation of the papilla level adjacent to single-tooth dental implants. A retrospective study in the maxillary anterior region. *J Periodontol* 2001;72:1364-71.
21. Renouard F, Rangert B. Risk factors in implant dentistry: simplified clinical analysis for predictable treatment. 2nd ed. Chicago: Quintessence International; 2008.