



Recommendation and Guideline

J Liver Cancer 2024;24(2):131-144
pISSN 2288-8128 • eISSN 2383-5001
<https://doi.org/10.17998/jlc.2024.08.04>



Local ablation for hepatocellular carcinoma: 2024 expert consensus-based practical recommendation of the Korean Liver Cancer Association

Seungchul Han^{1*}, Pil Soo Sung^{2*}, Soo Young Park³, Jin Woong Kim⁴, Hyun Pyo Hong⁵, Jung-Hee Yoon⁶, Dong Jin Chung⁷, Joon Ho Kwon⁸, Sanghyeok Lim⁹, Jae Hyun Kim¹⁰, Seung Kak Shin¹¹, Tae Hyung Kim¹², Dong Ho Lee¹⁰, Jong Young Choi²;

Research Committee of the Korean Liver Cancer Association

¹Department of Radiology, Samsung Medical Center, Seoul; ²Department of Internal Medicine, Seoul St. Mary's Hospital, The Catholic University of Korea, Seoul; ³Department of Internal Medicine, Kyungpook National University Hospital, School of Medicine, Kyungpook National University, Daegu; ⁴Department of Radiology, Chosun University Hospital, Chosun University College of Medicine, Gwangju; ⁵Department of Radiology, Kangbuk Samsung Hospital, Sungkyunkwan University School of Medicine, Seoul; ⁶Department of Radiology, Inje University Haeundae Paik Hospital, Inje University College of Medicine, Busan; ⁷Department of Radiology, Yeouido St. Mary's Hospital, The Catholic University of Korea, Seoul; ⁸Department of Radiology, Research Institute of Radiological Science, Severance Hospital, Yonsei University College of Medicine, Seoul; ⁹Department of Radiology, Soonchunhyang University Hospital Bucheon, Soonchunhyang University College of Medicine, Bucheon; ¹⁰Department of Radiology, Seoul National University Hospital, Seoul National University College of Medicine, Seoul; ¹¹Department of Internal Medicine, Gil Medical Center, Gachon University College of Medicine, Incheon; ¹²Department of Internal Medicine, Hallym University Sacred Heart Hospital, Anyang, Korea

Local ablation for hepatocellular carcinoma (HCC), a non-surgical option that directly targets and destroys tumor cells, has advanced significantly since the 1990s. Therapies with different energy sources, such as radiofrequency ablation, microwave ablation, and cryoablation, employ different mechanisms to induce tumor necrosis. The precision, safety, and effectiveness of these therapies have increased with advances in guiding technologies and device improvements. Consequently, local ablation has become the first-line treatment for early-stage HCC. The lack of organized evidence and expert opinions regarding patient selection, pre-procedure preparation, procedural methods, swift post-treatment evaluation, and follow-up has resulted in clinicians following varied practices. Therefore, an expert consensus-based practical recommendation for local ablation was developed by a group of experts in radiology and hepatology from the Research Committee of the Korean Liver Cancer Association in collaboration with the Korean Society of Image-guided Tumor Ablation to provide useful information and guidance for performing local ablation and for the pre- and post-treatment management of patients. (**J Liver Cancer 2024;24:131-144**)

Keywords: Hepatocellular carcinoma; Hepatoma; Liver cancer; Local ablation; Practical recommendation; Guideline; Guidance

Received Aug. 2, 2024 • Accepted Aug. 4, 2024

Corresponding author: Dong Ho Lee

Department of Radiology, Seoul National University Hospital, Seoul National University College of Medicine, 101 Daehak-ro, Jongno-gu, Seoul 03080, Korea

E-mail: dhlee.rad@gmail.com

*These two authors contributed equally to this work.

**This article is being published jointly in *Gut and Liver*, *Journal of Liver Cancer*, and *Korean Journal of Radiology*.

Copyright © 2024 by The Korean Liver Cancer Association.

This is an Open Access article distributed under the terms of the Creative Commons Attribution Non-Commercial License (<http://creativecommons.org/licenses/by-nc/4.0/>) which permits unrestricted non-commercial use, distribution, and reproduction in any medium, provided the original work is properly cited.

INTRODUCTION

Local ablation is a treatment modality wherein tumor necrotization is induced by delivering energy or injecting chemicals directly into the tumor. Radiofrequency ablation (RFA), microwave ablation (MWA), cryoablation, and injection of chemicals (e.g., percutaneous ethanol injection) have been used (Fig. 1). RFA is the most widely used modality for the treatment of hepatocellular carcinoma (HCC), with numerous studies providing high levels of evidence.

Two prospective randomized controlled trials and meta-analyses have reported that RFA yields survival rates equivalent to those of surgical resection in the treatment of HCC nodules measuring ≤ 3 cm.¹⁻³ Consequently, the 2022 guidelines published by the Korean Liver Cancer Association and the National Cancer Center (KLCA-NCC) deemed RFA as an optimal method, equivalent to surgical resection, for the treatment of small HCC nodules of a single lesion ≤ 3 cm in size.⁴⁻⁶ Moreover, RFA is recommended as an optimal treatment alongside transarterial chemoembolization (TACE) and liver transplantation for the treatment of up to three small HCC nodules, each measuring

≤ 3 cm.⁴⁻⁶ RFA is also used to treat recurrent HCC nodules measuring ≤ 3 cm.⁷

Local ablation techniques, including RFA, play an important role in the treatment of early-stage HCC. Thus, systematically organizing academic evidence and expert consensus on the selection of appropriate patients for treatment, pre-procedural preparation, procedural methods, post-treatment evaluation, and follow-up will increase the safety and effectiveness of these techniques, thereby improving the survival rates of patients with HCC. A survey of experts was conducted by the KLCA, in collaboration with the Korean Society of Image-guided Tumor Ablation (KSITA), to assess the current status and methodologies of local ablation treatment in Korea. Additionally, we reviewed and critically analyzed previous studies and guidelines related to local ablation, and established a consensus on the methodologies for performing local ablation treatments through discussions between expert panels and public hearings.

EXPERT SURVEY

Two separate online surveys targeting operators from the KSI-

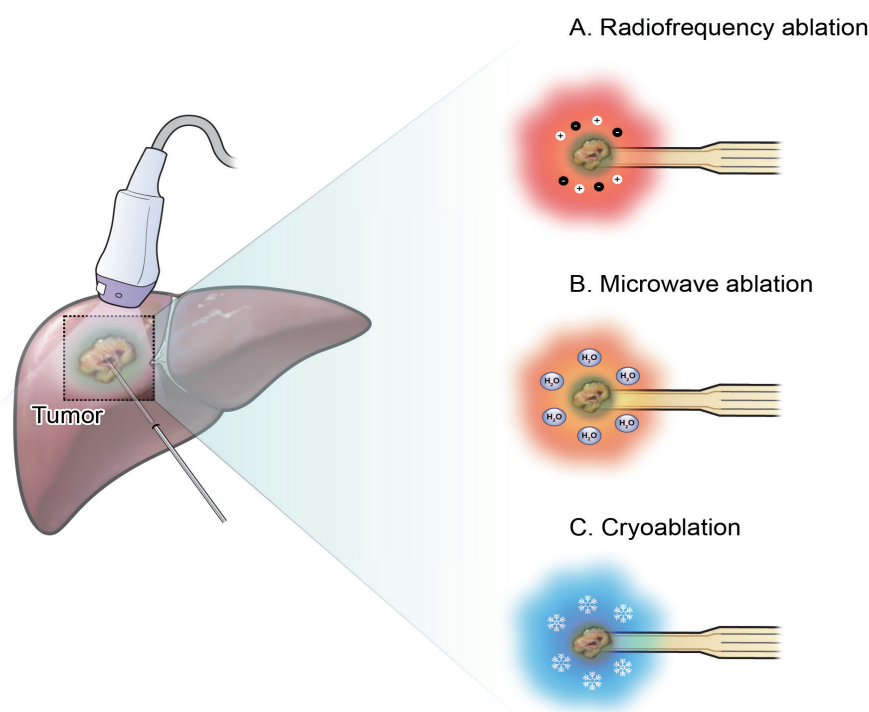


Figure 1. Schematic of local ablation techniques. The applicator was positioned in the tumor under guidance. (A) With radiofrequency ablation, the electrode delivers alternating radiofrequency energy, inducing friction among nearby molecules, thereby raising the tissue temperature and inducing tumor necrosis. (B) With microwave ablation, the antenna transmits microwave energy and increases the vibration of the surrounding water molecules, increasing the temperature and inducing tumor necrosis. (C) In cryoablation, high-pressure gas is passed through a probe, lowering the surrounding temperature to induce tumor necrosis.

TA who performed local ablation and hepatologists from the KLCA were conducted between July 25 and August 20, 2023. Among the 99 registered members of the KSITA, those who had undergone at least one local ablation procedure per month were invited to participate in the survey. Among the 35 members (response rate, 35.4%) who participated, 85.7% had >10 years of experience in the field of radiology, and 88.6% worked in hospitals with >500 beds. An additional survey targeting 63 hepatologists with at least 8 years of experience working in university hospitals, who are also members of the KLCA, was conducted. Twenty-two of the 63 hepatologists (34.9%) participated in the survey.

PATIENT SELECTION

Local ablation therapy is recommended as a curative non-surgical strategy for the treatment of early-stage HCCs in patients with a preserved general condition and no vascular invasion or extrahepatic metastases. International treatment guidelines, including the 2022 KLCA-NCC guidelines, endorse this recommendation.^{4-6,8,9} Compared with surgical resection, local ablation therapy is easier to perform, requires shorter hospital stays, and induces tumor necrosis while preserving the normal liver parenchyma,¹⁰⁻¹⁵ consequently, it is widely used as a non-surgical strategy for the treatment of HCC. However, similar to surgery or interventional radiological procedures, local ablation therapy is contraindicated in the following cases: those with an uncorrectable risk of severe bleeding, those where a safe route for the insertion of therapeutic devices (applicators) is unavailable, and those where irreversible damage to the adjacent organs is expected despite the application of preventive measures, such as artificial ascites or pleural effusion.¹⁶⁻¹⁸ Poor treatment outcomes and a higher incidence of procedure-related complications have been observed in patients with tumors located in the perihilar, perivascular, peribiliary, subcapsular, subphrenic, and subcardiac areas and in patients with tumors located adjacent to organs vulnerable to heat damage, such as the colon or gallbladder. Therefore, the location of the tumor must be carefully considered before commencing treatment (Fig. 2).^{16,19-25} Primary care physicians should refer patients identified as candidates for local ablative therapy to operators through multidisciplinary discussions or consultations. A planning session accompanied by ultrasonography (US) screening should also be scheduled to determine the feasibility of the treatment and establish a treatment plan for image-guided procedures.

Notably, 74.3% of operators reported recommending local ab-

lative therapy alone to treat solitary HCC tumors of ≤ 3 cm in size, assuming that no other considerations were present. Furthermore, 62.9% of respondents reported recommending local ablative therapy alone for the treatment of multifocal HCC with up to three tumors, provided that each tumor had a size <3 cm (Supplementary Fig. 1). In addition to the size, number of tumors, and staging, all respondents considered the location of the tumor and its relationship with the surrounding organs, vessels, and biliary tract. These respondents also considered ancillary imaging findings of the tumor that suggested a poor prognosis after treatment, such as irregular tumor margins and peritumoral arterial enhancement, when deciding to apply local ablative therapy. In addition to the size, number, and location of the tumors, all hepatologist respondents also considered liver function, and 74.3% of the respondents recommended treatment strategies based on the previous treatment history of the patient. Furthermore, 42.9% of the respondents considered tumor marker levels when deciding on local ablation therapy. Thus, the findings of previous research and the current survey results suggest that patients with well-preserved liver function presenting with a solitary HCC <3 cm in size located within the liver parenchyma that is not adjacent to major vessels, bile ducts, gallbladder,

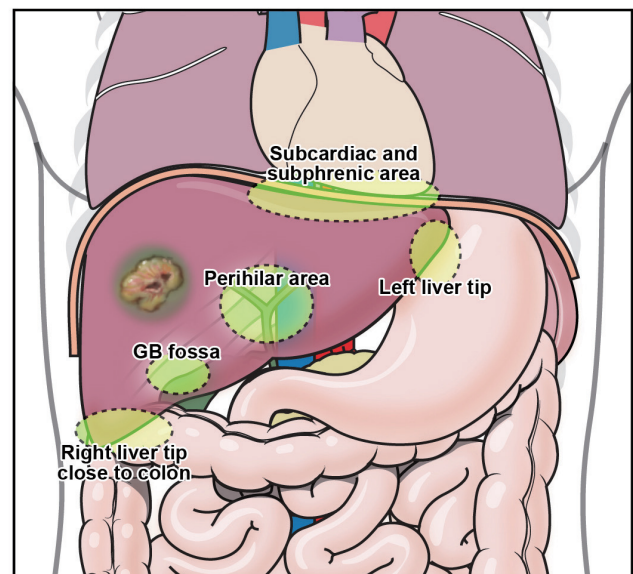


Figure 2. Locations which require caution before performing local ablation therapy. Tumors located in areas such as the perihilar region (which encompasses major vessels and bile ducts), subcardiac and subphrenic areas, near the colon at the right liver tip, GB fossa, and left liver tip, often result in less favorable treatment outcomes and an increase in the incidence of procedure-related complications. Therefore, the tumor location should be meticulously evaluated before proceeding with treatment. GB, gallbladder.

or gastrointestinal tract, and that can be accurately identified via US guidance, are ideal candidates for local ablative therapy.

Compared with local ablation alone, combination therapy comprising local ablation and TACE increases survival rates without increasing the complication rates in patients with a single HCC >3 cm in diameter.^{26,27} Notably, 48.6% of the respondents indicated that they performed combination therapy for lesions >3 cm in size in cases of a single HCC, with no other considerations. TACE (80.0%) and external beam radiation therapy (34.3%) were the therapies most commonly combined with local ablation.

In conclusion, when deciding whether to perform local ablation for HCC, it is important to consider various factors that can impact the effectiveness and safety of the treatment strategy. These factors include tumor size and number, staging, feasibility of image guidance based on tumor location, patient's liver function and overall health, underlying disease, risk factors for complications, history of previous treatments such as liver resection, and availability of other treatment options. Taking a multidisciplinary approach and providing collaborative care will help in making personalized decisions.

[Recommendations]

1. The indications for local ablation follow the guidelines set by the 2022 KLCA-NCC for HCC treatment. In addition to the stage of the disease, factors such as the location of the tumor, the feasibility of image guidance, whether combination therapy is used, the patient's liver function, previous treatment history, and overall health status should be considered in an individualized approach.

PRE-TREATMENT IMAGING STUDY

Dynamic contrast-enhanced computed tomography (CT) or magnetic resonance imaging (MRI) is performed before local ablation. These CT and MRI examinations are complementary. Notably, the acquisition of CT images is faster and less expensive than that of MR images. Furthermore, CT images possess a better spatial resolution and cover a wider scanning range, making them more advantageous for determining the presence of extrahepatic metastases. In contrast, MRI yields better tissue contrast than CT, facilitating the detection of smaller intrahepatic tumors, which aids in accurate staging.^{24,25}

Information from hepatobiliary images acquired using hepatocyte-specific contrast agents can be used to assess imaging features that suggest poor prognosis after treatment, such as peritumoral hyposignal intensity and irregular tumor margins.^{28,29} A

survey conducted to determine the preference of operators for using CT and MRI as pre-treatment imaging modalities before local ablation as the initial treatment for HCC revealed that 68.6% of the respondents preferred using both modalities. Studies on the optimal timing for pre-treatment imaging are lacking; however, the interval between imaging and the local ablation procedure should not be prolonged, owing to the possibility of lesion progression and the need for accurate post-treatment response assessment. The survey results revealed that 65.7% of operators and 86.4% of hepatologists preferred conducting imaging examinations within 1 month. Notably, all respondents agreed that the interval should not exceed 2 months. Furthermore, 88.6% of operators and 90.9% of hepatologists reported that they would repeat dynamic contrast-enhanced CT or MRI examinations if the pre-treatment imaging examination comprised single-phase CT or MRI, as single-phase CT or MRI is not sufficient for diagnosing liver cancer.⁵ Moreover, dynamic contrast-enhanced CT or MRI facilitates the interpretation of the relationship between the tumor and surrounding vascular structures.

Pre-treatment planning US plays an important role in assessing the feasibility of local ablation and predicting treatment efficacy and safety.³⁰ The results of the survey revealed that 91.4% of operators performed pre-treatment planning US; of these, 68.8% and 31.2% of operators respectively performed the procedure in an outpatient setting before admission and on the day of the procedure after hospital admission. However, it should be noted that planning US may not be able to detect HCC tumors <2 cm in size. In these cases, US-CT/MRI fusion imaging and contrast-enhanced ultrasonography (CEUS) can increase the detection rate of HCC and improve the success rate of the procedure.^{31,32} Notably, 58.1% of operators performed CEUS or US-CT/MRI fusion imaging as needed during US planning. A Kupffer agent, the use of which is preferred in the post-vascular phase, can confirm the location of HCC.³² This type of agent was used by 78.3% of operators when CEUS was employed during planning US.

[Recommendations]

1. Dynamic contrast-enhanced CT and MRI should be performed as pre-treatment imaging tests for local ablation, and the interval between imaging and the procedure should preferably be within 1 month.
2. Pre-treatment planning US examinations should be performed to assess the feasibility of local ablation and establish a treatment plan.

PREPARATION BEFORE LOCAL ABLATION

Prophylactic use of antibiotics

Small-scale retrospective studies have investigated the efficacy of prophylactic antibiotics before local ablation. In a previous study, no significant differences were observed between groups that did and did not receive prophylactic antibiotics in terms of the incidence of infectious complications after the procedure.³³ The application of local ablation as a one-time treatment is limited by various clinical factors, including tumor size, leading to an infrequent incidence of infectious complications. Surgical wounds can be classified into four categories: clean, clean-contaminated, contaminated, and dirty. Wounds created by local ablation are classified as clean. As a result, concerns regarding infections caused by local ablation are limited.³⁴ In contrast, fever is a common complication of local ablation. A recently published retrospective study revealed that fever was observed in 18.4% of the patients after ablation procedures; however, bacteremia was observed in only 4.8% of these patients.³⁵

Direct communication between the biliary tract and gastrointestinal system due to previous cholangiojejunostomy or endoscopic sphincterotomy increases the risk of developing liver abscesses after local ablation. Prophylactic administration of empirical antibiotics can reduce this risk;³⁶ therefore, it should be considered in patients with a history of biliary tract procedures undergoing local ablation. Reports have suggested that antibiotics should be used from the day before the procedure to a maximum of 2 days after the procedure, provided that no direct communication exists between the biliary and gastrointestinal systems. However, if direct communication is present, antibiotics should be administered for at least 10 days. Nevertheless, international guidelines for the type and duration of prophylactic antibiotic use have not yet been established. Therefore, further studies are warranted.

The survey of HCC experts revealed that 8.6% of respondents administered antibiotics prophylactically to most patients before local treatment and that 62.9% of respondents administered antibiotics prophylactically to select patients in high-risk groups. Patients in the high-risk group receiving antibiotics prophylactically included older patients, immunocompromised patients, and those with a medical history related to biliary tract or bile duct invasion of HCC (87.5%), liver abscesses (50.0%), or liver cirrhosis (33.3%). Cephalosporins (88.3%) were the most commonly administered preventive antibiotics.

Discontinuation of antiplatelet and anticoagulant agents

The incidence of HCC and various underlying diseases increases with age. Consequently, the number of patients receiving antiplatelet or anticoagulant drugs has increased. Local ablation is a high-risk procedure associated with the risk of bleeding because it can penetrate the liver parenchyma. Therefore, antiplatelet and anticoagulant drugs must be discontinued prior to the procedure. In such cases, the risk of thrombosis and/or embolism owing to an underlying disease must be considered. Furthermore, prior consultation with the clinician who has been treating the underlying disease is recommended.^{18,37} Nevertheless, international guidelines providing clear criteria for discontinuation of antiplatelet and anticoagulant drugs before local ablation remain to be established.

Different treatment guidelines suggest different standards and discontinuation periods. Thus, the criteria for discontinuing antiplatelet and anticoagulant drugs recommended before commencing high-risk endoscopic procedures, such as gastric endoscopic submucosal dissection or interventional radiology procedures, can be referred to before local ablation (Supplementary Table 1).

Transfusion of platelets, fresh frozen plasma, or cryoprecipitate

Most patients with HCC who undergo local ablation have chronic liver disease, with liver cirrhosis accounting for the majority of cases. Coagulation disorders such as thrombocytopenia and prolonged prothrombin time are commonly observed in patients with liver cirrhosis. Therefore, prophylactic transfusion of platelets, fresh frozen plasma, or cryoprecipitate may be initiated at the discretion of the clinician to reduce the risk of bleeding due to local ablation. However, excessive preventive measures may be unnecessary, as patients with liver cirrhosis often achieve a new equilibrium in hemostasis owing to concurrent reductions in both coagulation and anticoagulation factor levels.⁹ Previous studies have shown that prolonged prothrombin time or international normalized ratio (INR) does not necessarily indicate a bleeding tendency in patients with liver disease. Thus, the INR standard cannot be used as evidence for supplementation with fresh frozen plasma.³⁸

The 2022 KLCA-NCC practice guidelines for HCC recommend exercising caution while evaluating bleeding during the procedure if the platelet count is $<5,000/\text{mm}^3$, the prothrombin time is $<50\%$, or the INR is >1.5 - 1.8 .⁴⁻⁶ However, the Inter-

national Society of Interventional Radiology recommends separate criteria for patients with chronic liver disease, stating that interventional radiology procedures should be performed after satisfying the following criteria: INR <2.5 , platelet count $>30,000/\text{mm}^3$ and fibrinogen level $>100 \text{ mg/dL}$.¹⁸ Therefore, preventive measures against bleeding should be implemented by referring to these standards, based on the benefits and risks for each patient. If necessary, a relevant specialist must be consulted. Moreover, the possibility of bleeding must be clearly explained to patients in advance.

[Recommendations]

1. Prophylactic administration of antibiotics should be considered while performing local ablation in patients with a history of biliary tract-related medical conditions.
2. The patient's bleeding tendency should be reviewed, and any antiplatelet or anticoagulant agent being taken by the patient should be discontinued before local ablation.

PERFORMING LOCAL ABLATION

Image guiding modality

US imaging enables identification of the location of hepatic tumors and ablation devices in real time, as well as real-time assessment of the ablation area owing to the formation of highly echogenic bubbles during RFA and MWA. Thus, it is an effective imaging-guided technique for local ablation. The survey re-

sults revealed that 74.3% of operators always used US as an image-guiding technique during local ablation. However, US cannot distinguish some tumors from the surrounding liver parenchyma, as they may be obscured by the base of the lung or intestines or have poor visibility owing to poor sonic windows. In such cases, CT or fluoroscopic imaging can be used as a guiding technique to enable the procedure to be performed on tumors that are not clearly visible on US.

Auxiliary image guiding technique

US-CT/MR fusion technique

Aligning the positions of US images and images acquired using other modalities, such as CT and MRI, can often be challenging when performing procedures under US guidance due to differences in imaging planes. US-CT/MRI fusion can enhance local ablation outcomes in such cases.³⁹⁻⁴² This technique reconstructs patient-specific cross-sectional images into a 3D volume and creates a magnetic field over the corresponding area, which facilitates the detection of the position of the US probe. This enables the current US image to be synchronized with cross-sectional images (Fig. 3) and assists in identifying tumors detected on cross-sectional images. Furthermore, this technique aids in understanding the proximity of the tumor to critical structures such as the major hepatic veins, portal veins, and bile ducts.^{39,40,42} The survey results revealed that 42.9% of operators always used fusion imaging, whereas 42.8% used it only as needed.

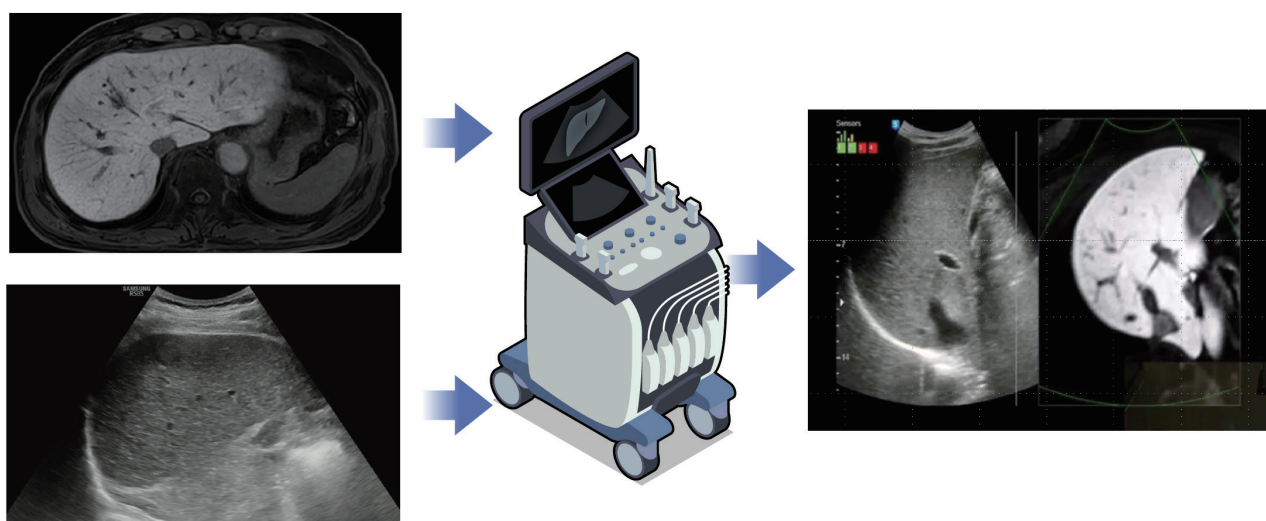


Figure 3. Schematic of the US-CT/MRI fusion technique. This technique involves aligning cross-sectional images (shown as MRI images) with real-time US images, matching the relevant anatomical structures, and synchronizing their positions. Real-time US images are subsequently aligned with the cross-sectional images and evaluated simultaneously. US, ultrasonography; CT, computed tomography; MRI, magnetic resonance imaging.

CEUS

US contrast agents enhance the contrast between tumors and the liver parenchyma. Furthermore, they can display the hemodynamic characteristics of tumors in real time, assisting local ablation procedures under certain circumstances.^{43–46} The survey results revealed that 74.3% of the operators used CEUS when necessary. US contrast agents can be classified into two main types: pure blood pool agents and Kupffer agents. Kupffer agents are taken up by the Kupffer cells in the liver, resulting in contrast enhancement of the liver parenchyma, which is sustained for a longer period. This results in increased lesion and parenchymal contrast, aiding the procedure.^{47,48} The survey results revealed that 84.6% of the operators preferred the use of Kupffer agents over the use of pure blood pool agents.

Use of artificial ascites/pleural effusion

If necessary, fluid can be artificially introduced into the abdominal or thoracic cavity during local ablation. This improves the sonic window, protects surrounding organs from thermal damage, and reduces pain (Fig. 4).^{49–52} The survey results revealed that 97.1% of the operators induced artificial ascites when necessary. Notably, 5% dextrose water was the most commonly used fluid, accounting for 73.5% of cases. Furthermore, 17.6% of the operators considered using normal saline for inducing ascites in patients with diabetes. Only 45.7% of the operators reported using artificial pleural effusion when necessary.

Anesthesia and patient monitoring

Thermal-based local ablation stimulates the nerve bundles distributed around the liver capsule and portal triad, which can cause pain. Thus, appropriate anesthetic management plays an important role in reducing patient discomfort and enabling the operator to perform the procedure safely with patient cooperation.^{53,54} The survey results revealed that 74.3% of the operators used local anesthesia and intravenous sedation; in contrast, 17.1% of the operators used only local anesthesia, primarily during cryoablation procedures. Notably, 62.9% of the operators administered anesthesia themselves, whereas 31.4% performed procedures in the presence of an anesthesiologist specializing in pain management. Complications such as bleeding, pain-related bradycardia, and side effects of intravenous anesthesia (e.g., apnea) can occur during this procedure. Therefore, it is essential to monitor the patient's vital signs, including oxygen saturation, pulse rate, blood pressure, and electrocardiographic findings. Furthermore, resuscitation equipment including oxygen and crash carts must be readily available during emergencies.

Local ablation techniques

Selection among RFA, MWA, and cryoablation

The survey results revealed that 100%, 62.9%, and 25.7% of operators reported the availability of RFA, MWA, and cryoablation, respectively, at their practicing institutions. Post-treatment tumor response, survival rates, and complications are critical considerations when selecting a local ablation technique. Large-

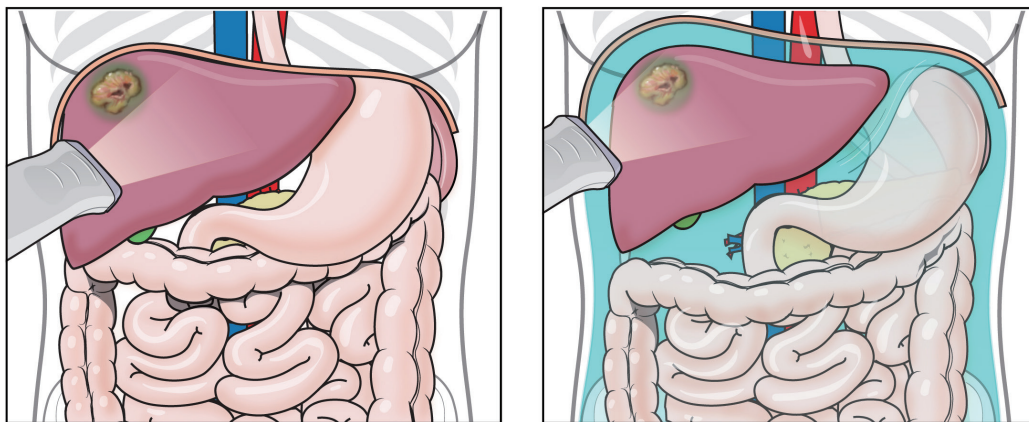


Figure 4. Schematic of artificial injection of ascites. Subphrenic tumors may not be clearly visible on ultrasonographic imaging owing to poor sonic windows. Injecting artificial ascites creates a space between the diaphragm and liver, improving the sonic window by filling this space with fluid. Creating and filling the spaces between the liver and diaphragm, the liver and abdominal wall, the gastrointestinal tract, and other nearby organs can reduce the risk of inadvertent damage to adjacent organs during local ablation procedures.

scale prospective randomized controlled trials or meta-analyses comparing all local ablation techniques remain lacking; however, previous studies have shown that RFA, MWA, and cryoablation exhibit similar therapeutic effects.^{5,13,14,55,56} RFA, the most widely used local ablation technique, is known for its extensive treatment experience and superior predictability of ablation zones. MWA can achieve a larger ablation area within a relatively short time. Furthermore, it is less affected by heat-sink effects. Compared with heat-based techniques such as MWA and RFA, cryoablation induces less pain and damage to adjacent organs. Therefore, the local ablation technique must be selected appropriately based on the location and size of the tumor, proximity of the blood vessels and major bile ducts, unique characteristics of the energy source, and operator's experience. Furthermore, track ablation must be performed to prevent post-procedural bleeding and tumor seeding. The survey results revealed that 100% of the operators performed track ablation.

Selection of electrode (RFA), antenna (MWA), probe (cryoablation), energy, and ablation time

Electrodes ranging from 15 to 17 G are commonly used for RFA, with thicker electrodes increasing the ablation range. The length of the active tip, which determines the ablation range, ranges from 1 to 3 cm, enabling the operator to adjust the ablation range by selecting the thickness and length of the active tip and the number of electrodes inserted. The energy used ranges from 30 to 200 W depending on the experience of the operator. In addition, the electrodes can be repositioned after the initial ablation to perform additional ablation, if necessary. The survey results revealed that the minimum energy used by the operators to initiate ablation varied from 20 to 200 W, with the maximum energy used ranging from 120 to 200 W, depending on the operator. Notably, 64.7% of the respondents reported that they terminated local ablation when the planned safety margin was achieved and 1-2 instances of power roll-off occurred, regardless of time. Nevertheless, the ablation time varied depending on the size and number of the tumors. The survey results revealed that the average ablation time using RFA for a single 2-cm HCC nodule was approximately 9.5 minutes.

Compared to the use of a single electrode, performing RFA with multiple electrodes is advantageous because it improves the efficiency of energy delivery, achieves a larger ablation area per unit time, and provides a flexible configuration of the ablation zone based on the structures surrounding the tumor. However, an increase in the number of needle insertions can increase the risk of complications.⁵⁷⁻⁵⁹ The survey results revealed that 88.2%

of the operators used multiple electrodes when necessary, with 93.3% using up to three electrodes. Recent studies on the no-touch RFA technique, wherein multiple electrodes are positioned beyond the tumor margin, have reported a lower local recurrence rate than that associated with conventional tumor puncture RFA.⁶⁰⁻⁶² Multiple electrodes must be positioned around the tumor in no-touch RFA; therefore, securing multiple safe electrode insertion paths is necessary. Insufficient safe paths were secured for multiple electrode insertions in 8.6% of the cases in recent prospective multicenter studies, leading to a switch to conventional tumor-puncture RFA during the procedure.⁶² However, further studies must be conducted to determine whether the survival rates of no-touch RFA are superior to those of conventional tumor puncture RFA. The survey results revealed that 82.4% of the operators preferred performing no-touch RFA if possible.

MWA is typically performed using 13-15 G antennas. Unlike RFA, the length of the active part is fixed in MWA, and the ablation range is determined based on the energy and duration of ablation. Energy levels ranging from 60 to 100 W are used for ablation, and the position of the antenna is typically readjusted after the initial ablation to perform additional ablation if needed. The survey results revealed that the minimum energy used by the operators to initiate ablation was 60-75 W, whereas the maximum energy used varied from 75 to 100 W, depending on the preferences of the operator. As a primary criterion for discontinuing local ablation, 55.6% of the operators reported that they terminated ablation after an appropriate duration of time had passed. Similar to RFA, the ablation duration for MWA varies according to the tumor size and number. The survey results revealed that the average ablation time for treating a single 2-cm HCC nodule was approximately 5.3 minutes.

Cryoablation typically uses probes ranging in size from 14 to 17 G. Various types of probes are manufactured based on the size of the ice balls created. The type and number of probes used can be adjusted according to the ablation range, and the general ablation process involves repeating a freeze-thaw cycle at least twice. The survey results revealed that all operators terminated ablation after two cycles of freezing and thawing and that a combination of passive and active thawing was the most commonly used method. As for ablation time, it varied depending on the size and number of the tumors. The survey results revealed that the average ablation time for treating a single 2-cm HCC nodule was approximately 33.6 minutes. Similar to RFA, the simultaneous use of multiple probes is possible in cryoablation. Thus, a larger ablation area can be achieved; however, this

can theoretically increase the frequency of complications.⁶³ The survey results revealed that 87.5% of the operators used multiple probes, and 57.1% used up to three probes.

In conclusion, each local ablation technique utilizes various types of electrodes, antennas, or probes, facilitating a wide range of applications based on the size and location of the tumor, proximity to adjacent organs, and experience and preferences of the operator. Furthermore, the energy levels and duration of ablation can be adjusted based on real-time monitoring of the ablation process and the judgment of the operator.

Swift post-procedure imaging and evaluation

Post-procedural imaging plays an important role in detecting treatment-related complications and assessing the technical success of local ablation procedures. The survey results revealed that 94.3% of the respondents performed post-procedure imaging immediately after the procedure (88.6%) or on the following day (11.4%). All respondents reported that performing contrast-enhanced CT for post-procedure imaging could detect complications such as bleeding. However, the use of iodine-based contrast agents in contrast-enhanced CT is associated with a low risk of hypersensitivity reactions and renal impairment, particularly in high-risk patients. Thus, the risks and use of premedication should be carefully considered when indicated.

Technical success of local ablation is defined as complete inclusion of the tumor within the ablation zone, regardless of the width of the safety margin (Fig. 5).^{64,65} The frequency of local tumor progression can be decreased by creating a wider safety margin; however, this may also increase the risk of damage to surrounding structures and the frequency of complications. Thus, the safety margin must be secured by following an individualized approach based on the location of each tumor and its relationship with nearby structures. A band-like enhancement around the ablation area can sometimes be observed on postprocedural contrast-enhanced CT images acquired immediately after the procedure. The presence of this band-like enhancement is mostly indicative of changes in the surrounding liver parenchyma due to local ablation; however, distinguishing it from the remaining tumor tissue can be difficult, limiting the assessment of the safety margin. Follow-up imaging studies must be conducted to accurately evaluate safety margins in such cases.

Local ablation procedures are associated with a short recovery period, which facilitates repeated treatment within a short duration if the initial therapy is unsuccessful. The survey results revealed that 74.3% of operators performed re-treatment or other

additional therapies during the same hospitalization period if post-procedure imaging revealed the presence of residual HCC after ablation. Furthermore, 20% of the operators reported performing re-treatment or other additional therapies during the same hospitalization period if a safety margin of at least 5 mm was not achieved, despite full coverage of the tumor within the ablation zone.

[Recommendations]

1. Local ablation procedures can be effectively performed under US guidance. Assistance can be provided through the use of CT, fluoroscopy, US/CT-MRI fusion techniques, US contrast agents, and artificial ascites/pleural effusion as needed.
2. Appropriate local and sedative anesthetic agents should be administered during the procedure to alleviate pain and ensure safe progress.
3. To prevent complications from the procedure and anesthesia, and to perform appropriate emergency measures, vital signs, including oxygen saturation, pulse rate, blood pressure, and electrocardiogram should be monitored, and equipment necessary for resuscitation, including oxygen and a crash cart, should be prepared.
4. Swift post-procedure imaging is required to determine the technical success and the occurrence of complications. Re-treatment or additional treatment may be performed based on the outcome.

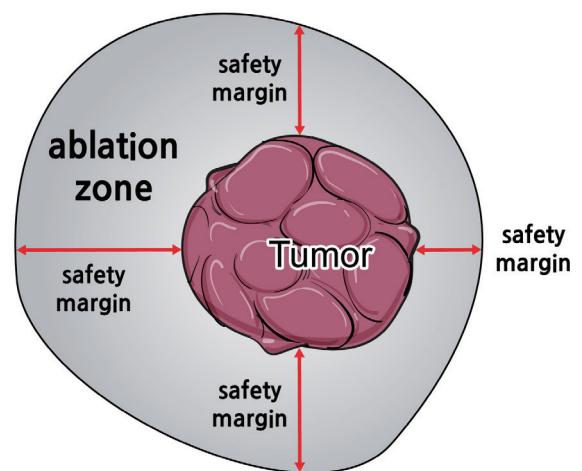


Figure 5. Post-procedural ablation zone evaluation. Technical success in local ablation is achieved when the tumor is fully encompassed within the ablation zone. Meanwhile, the safety margin refers to the distance between the tumor boundary and the ablation margin. In the figure provided, the tumor is completely included in the ablation zone, which signifies technical success. It is worth noting that the safety margin is smallest at the 3 o'clock position and largest at the 9 o'clock position.

PATIENT MANAGEMENT AFTER LOCAL ABLATION

Adverse reactions related to local treatment vary in type and frequency based on the clinical characteristics of each patient and the treatment method. Post-ablation syndrome is the most common adverse reaction to local ablation. Symptoms such as nausea, vomiting, mild abdominal pain, shoulder pain, and mild fever may develop 24–48 hours after completion of treatment in approximately 30–40% of cases.^{66,67} The severity and duration of symptoms vary based on the volume of the necrotic tissue and the patient's general medical condition. Appropriate evaluation, including additional imaging studies, must be performed, if necessary, to discriminate between serious complications and simple post-ablation syndrome based on the clinical pattern if symptoms persist, even when no complications are observed in studies performed immediately after the procedure. Most local ablation-related complications, such as bleeding, develop immediately after the procedure. However, caution must be exercised as the presence of infection, damage to nearby organs, or delayed bleeding cannot be confirmed on imaging studies performed immediately after the procedure; these complications may become apparent on delayed follow-up imaging studies.^{68,69}

Approximately 5% of patients develop complications after local ablation.^{16,19,70} Major complications include liver abscesses, hemoperitoneum, hemothorax, pneumothorax, intestinal perforation, bilomas, hepatic infarction, and tumor cell seeding.^{16,21} No significant differences in the overall incidence of major complication have been observed among RFA, MWA, and cryoablation.^{12,14,15,71} However, caution is needed with cryoablation due to the potential risk of complications from hypothermia following the procedure, although it is associated with a lower incidence of complications during the treatment of HCCs located near the biliary tract or blood vessels compared to RFA.^{72–74}

The responses of HCC experts regarding patient management after local ablation revealed several complications, including post-treatment syndromes, bleeding, liver abscesses, bilomas, intestinal perforation, and pneumothorax. Other complications mentioned were hepatic infarction, liver failure, cardiac tamponade, and thermal injury to the diaphragm. According to the survey results, 27.3% of the respondents performed careful monitoring of vital signs for 4–6 hours after local ablation, while 22.7% performed such monitoring for 2–3 hours. The majority (94.3%) of HCC experts used post-procedure contrast-enhanced abdominal CT to detect complications after local ablation. Additionally, blood tests, such as liver function tests and complete

blood counts, along with plain chest and abdominal imaging, were performed.

In terms of antiemetics used for post-ablation syndrome-related nausea or vomiting, 72.7% of respondents reported administering metoclopramide, and 59.1% reported administering 5-HT₃ receptor antagonists. The survey also found that 77.3% of respondents administered tramadol for pain management. Other drugs used for pain management included acetaminophen, narcotic analgesics, and nonsteroidal anti-inflammatory drugs. The European Association for the Study of the Liver recommends monitoring the side effects of opioids metabolized in the liver when controlling pain in patients with cirrhosis, as their liver metabolism may be impaired.⁸ Most patients with well-maintained liver function undergo local ablation to compensate for cirrhosis or chronic hepatitis. However, it is important to monitor the side effects of opioids, such as tramadol and morphine.

The survey results revealed that 86.4% of the respondents administered third-generation cephalosporins such as ceftriaxone and cefotaxime when infection was suspected. A retrospective study that evaluated the frequency and risk factors for liver abscesses after local ablation revealed that liver abscesses were detected in 1.7% of cases after the procedure.⁷⁵ *Clostridium perfringens*, *Staphylococcus aureus*, *Aeromonas hydrophila*, and *Klebsiella pneumoniae* were identified as the causative bacteria in a culture test performed using abscess aspiration. The presence of *Enterococcus* species and gram-negative bacilli was confirmed by blood culture. Therefore, the possibility of infection with aerobic and anaerobic bacteria must be considered when selecting empirical antibiotics.⁷⁵

[Recommendations]

1. Appropriate evaluation, including additional imaging studies, must be performed to rule out serious complications if persistent abnormal symptoms and clinical signs are reported after local ablation.

FOLLOW-UP AFTER LOCAL ABLATION

Follow-up measures

Regular follow-up visits to outpatient clinics must be scheduled to detect delayed complications and recurrences after discharge from the hospital following local ablation. In addition, imaging and blood tests should be performed. Follow-up imaging examinations must be performed using dynamic contrast-enhanced CT or alternating dynamic contrast-enhanced CT and MRI. Furthermore, blood tests must be performed to determine tu-

mor marker levels. The guidelines followed the 2022 KLCA-NCC practice guidelines for HCC.^{4,6}

Follow-up interval

The 2022 KLCA-NCC practice guidelines for HCC should be followed during follow-up. These guidelines recommend follow-up examinations at intervals of 2–6 months during the first 2 years after local ablation. If recurrence does not occur after 2 years, an individualized approach must be implemented based on symptoms, tumor marker levels, and experience of the clinician.^{4,6} The results of a survey targeting attending physicians and operators revealed that most doctors (81.3%) had patients visiting the first outpatient clinic 1 month after local ablation. Follow-up examinations were performed at intervals of ≤ 3 months (34.3%) or 3–6 months (60.0%) until 2 years after the procedure. Follow-up examinations were also conducted at intervals of 3–6 months (45.7%) or ≥ 6 months (54.3%) starting 2 years after the procedure if recurrence did not occur.

Treatment response evaluation

Treatment responses after local ablation for HCC can be assessed based on the findings of postprocedural imaging examinations. Tumor marker levels can be used as a reference in cases where tumors with high tumor marker levels are present before the procedure. The survey results revealed that 71.4% of respondents considered complete radiological response to be a complete response regardless of the tumor marker levels, whereas 28.6% considered complete radiological response and tumor marker normalization as a complete response.

Local tumor progression was defined as the presence of a tumor adjacent to the ablation area after complete ablation on one or more follow-up imaging examinations, excluding those performed immediately after the procedure. However, it is unclear whether additional MRI examinations should be performed when local tumor progression is suspected based on CT findings. The survey results revealed that 45.7% of respondents considered CT findings alone to be sufficient for diagnosis, whereas 37.1% said that an additional MRI examination was required.

[Recommendations]

1. Regular follow-up is necessary after local ablation, including imaging studies such as contrast-enhanced CT or MRI examinations, as well as blood tests that include tumor markers. It is also important to establish follow-up intervals based on the guidelines outlined in the 2022 KLCA-NCC practice guideline. Additionally, an individualized approach that takes into account the patient's symptoms and tumor marker levels is required.

Acknowledgements

The authors thank the members of the advisory committee for this work. The members of the advisory committee were as follows: Dong Jin Chung (President of KSITA, Radiology, The Catholic University of Korea), Kyung Sik Kim (The Next President of KLCA, Surgery, Yonsei University), Jong Young Choi (President of KLCA, Hepatology, Hepatology, The Catholic University of Korea), Kwang Cheol Koh (Former President of KLCA, Hepatology, Sungkyunkwan University), Young Nyun Park (Former President of KLCA, Pathology, Yonsei University), Jin Wook Chung (Former President of KLCA, Radiology, Seoul National University), Seung Kew Yoon (Former President of KLCA, Hepatology, The Catholic University of Korea), Joong-Won Park (Former President of KLCA, Hepatology, Myongji Hospital), Jinsil Seong (Former President of KLCA, Radiation Oncology, Yonsei University), Kyung-Suk Suh (Former President of KLCA, Surgery, Seoul National University), Hyunchul Rhim (Former President of KLCA, Radiology, Sungkyunkwan University), Young Seok Kim (Vice President of KLCA, Hepatology, Soonchunhyang University), Jeong Won Jang (Secretary General of KLCA, Hepatology, The Catholic University of Korea), Eileen L Yoon (Insurance Director of KLCA, Hepatology, Hanyang University).

Conflict of Interest

Dong Ho Lee received research grants from Canon Medical Systems. Soo Young Park reports on sponsored lectures on Gilead, Abbvie, and consultant/advisory roles for Bayer. The authors declare no conflicts of interest.

Ethics Statement

Not applicable.

Funding Statement

This study was supported by Korea Liver Cancer Association.

Data Availability

Not applicable.

ORCID

Seungchul Han	https://orcid.org/0000-0002-7276-0370
Pil Soo Sung	https://orcid.org/0000-0002-5780-9607
Soo Young Park	https://orcid.org/0000-0002-4944-4396
Jin Woong Kim	https://orcid.org/0000-0003-4725-5687
Hyun Pyo Hong	https://orcid.org/0000-0003-1451-3141
Jung-Hee Yoon	https://orcid.org/0000-0001-5152-6668
Dong Jin Chung	https://orcid.org/0000-0002-3250-142X
Joon Ho Kwon	https://orcid.org/0000-0002-6178-7252
Sanghyeok Lim	https://orcid.org/0000-0002-1607-3744
Jae Hyun Kim	https://orcid.org/0000-0002-6691-3932
Seung Kak Shin	https://orcid.org/0000-0002-5120-5300
Tae Hyung Kim	https://orcid.org/0000-0002-7747-4293
Dong Ho Lee	https://orcid.org/0000-0001-8983-851X
Jong Young Choi	https://orcid.org/0000-0001-7833-0307

Author Contributions

Conceptualization: DHL

Data curation: SH, PSS, SYP, JWK, HPH, JHY, DJC, JHK, SL, JHK, SKS, THK

Funding acquisition: DHL, JYC

Methodology: DHL

Supervision: DHL, JYC

Writing - original draft: SH, PSS

Writing - review & editing: all authors

Supplementary Material

Supplementary data can be found with this article online

<https://doi.org/10.17998/jlc.2024.08.04>.

REFERENCES

- Chen MS, Li JQ, Zheng Y, Guo RP, Liang HH, Zhang YQ, et al. A prospective randomized trial comparing percutaneous local ablative therapy and partial hepatectomy for small hepatocellular carcinoma. *Ann Surg* 2006;243:321-328.
- Feng K, Yan J, Li X, Xia F, Ma K, Wang S, et al. A randomized controlled trial of radiofrequency ablation and surgical resection in the treatment of small hepatocellular carcinoma. *J Hepatol* 2012;57:794-802.
- Wang Y, Luo Q, Li Y, Deng S, Wei S, Li X. Radiofrequency ablation versus hepatic resection for small hepatocellular carcinomas: a meta-analysis of randomized and nonrandomized controlled trials. *PLoS One* 2014;9:e84484.
- Korean Liver Cancer Association (KLCA), National Cancer Center (NCC) Korea. 2022 KLCA-NCC Korea practice guidelines for the management of hepatocellular carcinoma. *J Liver Cancer* 2023;23:1-120.
- Korean Liver Cancer Association (KLCA), National Cancer Center (NCC) Korea. 2022 KLCA-NCC Korea practice guidelines for the management of hepatocellular carcinoma. *Korean J Radiol* 2022;23:1126-1240.
- Korean Liver Cancer Association (KLCA), National Cancer Center (NCC) Korea. 2022 KLCA-NCC Korea practice guidelines for the management of hepatocellular carcinoma. *Clin Mol Hepatol* 2022;28:583-705.
- Lee DH, Lee JM, Lee JY, Kim SH, Han JK, Choi BI. Radiofrequency ablation for intrahepatic recurrent hepatocellular carcinoma: long-term results and prognostic factors in 168 patients with cirrhosis. *Cardiovasc Intervent Radiol* 2014;37:705-715.
- European Association for the Study of the Liver. EASL clinical practice guidelines: management of hepatocellular carcinoma. *J Hepatol* 2018;69:182-236.
- European Association for the Study of the Liver. EASL clinical practice guidelines on prevention and management of bleeding and thrombosis in patients with cirrhosis. *J Hepatol* 2022;76:1151-1184.
- Lencioni R, Cioni D, Crocetti L, Franchini C, Pina CD, Lera J, et al. Early-stage hepatocellular carcinoma in patients with cirrhosis: long-term results of percutaneous image-guided radiofrequency ablation. *Radiology* 2005;234:961-967.
- Shiina S, Teratani T, Obi S, Sato S, Tateishi R, Fujishima T, et al. A randomized controlled trial of radiofrequency ablation with ethanol injection for small hepatocellular carcinoma. *Gastroenterology* 2005;129:122-130.
- Luo W, Zhang Y, He G, Yu M, Zheng M, Liu L, et al. Effects of radiofrequency ablation versus other ablating techniques on hepatocellular carcinomas: a systematic review and meta-analysis. *World J Surg Oncol* 2017;15:126.
- Violi NV, Duran R, Guiu B, Cercueil JP, Aubé C, Digkila A, et al. Efficacy of microwave ablation versus radiofrequency ablation for the treatment of hepatocellular carcinoma in patients with chronic liver disease: a randomised controlled phase 2 trial. *Lancet Gastroenterol Hepatol* 2018;3:317-325.
- Gupta P, Maralakunte M, Kumar-M P, Chandel K, Chaluvashetty SB, Bhujade H, et al. Overall survival and local recurrence following RFA, MWA, and cryoablation of very early and early HCC: a systematic review and Bayesian network meta-analysis. *Eur Radiol* 2021;31:5400-5408.
- Yu Q, Liu C, Navuluri R, Ahmed O. Percutaneous microwave ablation versus radiofrequency ablation of hepatocellular carcinoma: a meta-analysis of randomized controlled trials. *Abdom Radiol (NY)* 2021;46:4467-4475.
- Patel IJ, Rahim S, Davidson JC, Hanks SE, Tam AL, Walker TG, et al. Society of Interventional Radiology consensus guidelines for the periprocedural management of thrombotic and bleeding risk in patients undergoing percutaneous image-guided interventions-part II: recommendations: endorsed by the Canadian Association for Interventional Radiology and the Cardiovascular and Interventional Radiological Society of Europe. *J Vasc Interv Radiol* 2019;30:1168-1184.e1.
- Tripodi A, Primignani M, Mannucci PM, Caldwell SH. Changing concepts of cirrhotic coagulopathy. *Am J Gastroenterol* 2017;112:274-281.
- Rhim H, Yoon KH, Lee JM, Cho Y, Cho JS, Kim SH, et al. Major complications after radio-frequency thermal ablation of hepatic tumors: spectrum of imaging findings. *Radiographics* 2003;23:123-134; discussion 134-136.
- de Baère T, Risse O, Kuoch V, Dromain C, Sengel C, Smayra T, et al. Adverse events during radiofrequency treatment of 582 hepatic tumors. *AJR Am J Roentgenol* 2003;181:695-700.
- Lencioni RA, Allgaier HP, Cioni D, Olschewski M, Deibert P, Crocetti L, et al. Small hepatocellular carcinoma in cirrhosis: randomized comparison of radio-frequency thermal ablation versus percutaneous ethanol injection. *Radiology* 2003;228:235-240.
- Shiina S, Tateishi R, Arano T, Uchino K, Enooku K, Nakagawa H, et al. Radiofrequency ablation for hepatocellular carcinoma: 10-year outcome and prognostic factors. *Am J Gastroenterol* 2012;107:569-577; quiz 578.
- Kang TW, Lim HK, Lee MW, Kim YS, Rhim H, Lee WJ, et al. Aggressive intrasegmental recurrence of hepatocellular carcinoma after radiofrequency ablation: risk factors and clinical significance. *Radiology* 2015;276:274-285.

23. Lee S, Kang TW, Cha DI, Song KD, Lee MW, Rhim H, et al. Radiofrequency ablation vs. surgery for perivascular hepatocellular carcinoma: Propensity score analyses of long-term outcomes. *J Hepatol* 2018;69:70-78.
24. Song KD, Lim HK, Rhim H, Lee MW, Kang TW, Paik YH, et al. Hepatic resection vs percutaneous radiofrequency ablation of hepatocellular carcinoma abutting right diaphragm. *World J Gastrointest Oncol* 2019;11:227-237.
25. Lee MW, Kang D, Lim HK, Cho J, Sinn DH, Kang TW, et al. Updated 10-year outcomes of percutaneous radiofrequency ablation as first-line therapy for single hepatocellular carcinoma <3 cm: emphasis on association of local tumor progression and overall survival. *Eur Radiol* 2020;30:2391-2400.
26. Ni JY, Liu SS, Xu LF, Sun HL, Chen YT. Meta-analysis of radiofrequency ablation in combination with transarterial chemoembolization for hepatocellular carcinoma. *World J Gastroenterol* 2013;19:3872-3882.
27. Wang X, Hu Y, Ren M, Lu X, Lu G, He S. Efficacy and safety of radiofrequency ablation combined with transcatheter arterial chemoembolization for hepatocellular carcinomas compared with radiofrequency ablation alone: a time-to-event meta-analysis. *Korean J Radiol* 2016;17:93-102.
28. Lee S, Kim SH, Lee JE, Sinn DH, Park CK. Preoperative gadoxetic acid-enhanced MRI for predicting microvascular invasion in patients with single hepatocellular carcinoma. *J Hepatol* 2017;67:526-534.
29. Choi SH, Lee SS, Park SH, Kim KM, Yu E, Park Y, et al. LI-RADS classification and prognosis of primary liver cancers at gadoxetic acid-enhanced MRI. *Radiology* 2019;290:388-397.
30. Rhim H, Choi D, Kim YS, Lim HK, Choe BK. Ultrasonography-guided percutaneous radiofrequency ablation of hepatocellular carcinomas: a feasibility scoring system for planning sonography. *Eur J Radiol* 2010;75:253-258.
31. Lee MW, Rhim H, Cha DI, Kim YJ, Lim HK. Planning US for percutaneous radiofrequency ablation of small hepatocellular carcinomas (1-3 cm): value of fusion imaging with conventional US and CT/MR images. *J Vasc Interv Radiol* 2013;24:958-965.
32. Lee MW, Lim HK, Rhim H, Cha DI, Kang TW, Song KD, et al. Percutaneous radiofrequency ablation of small (1-2 cm) hepatocellular carcinomas inconspicuous on B-mode ultrasonographic imaging: usefulness of combined fusion imaging with MRI and contrast-enhanced ultrasonography. *Can J Gastroenterol Hepatol* 2018;2018:7926923.
33. Bhatia SS, Spector S, Echenique A, Froud T, Suthar R, Lawson I, et al. Is antibiotic prophylaxis for percutaneous radiofrequency ablation (RFA) of primary liver tumors necessary? results from a single-center experience. *Cardiovasc Intervent Radiol* 2015;38:922-928.
34. Chehab MA, Thakor AS, Tulin-Silver S, Connolly BL, Cahill AM, Ward TJ, et al. Adult and pediatric antibiotic prophylaxis during vascular and IR procedures: a Society of Interventional Radiology practice parameter update endorsed by the Cardiovascular and Interventional Radiological Society of Europe and the Canadian Association for Interventional Radiology. *J Vasc Interv Radiol* 2018;29:1483-1501.e2.
35. Chen PY, Tsai TJ, Yang HY, Chou CK, Chang LJ, Chen TH, et al. The incidence of bacteremia and risk factors of post-radiofrequency ablation fever for patients with hepato-cellular carcinoma. *Cancers (Basel)* 2021;13:5303.
36. Hoffmann R, Rempp H, Schmidt D, Pereira PL, Claussen CD, Clasen S. Prolonged antibiotic prophylaxis in patients with bilioenteric anastomosis undergoing percutaneous radiofrequency ablation. *J Vasc Interv Radiol* 2012;23:545-551.
37. Lim H, Gong EJ, Min BH, Kang SJ, Shin CM, Byeon JS, et al. Clinical practice guideline for the management of antithrombotic agents in patients undergoing gastrointestinal endoscopy. *Clin Endosc* 2020;53:663-677.
38. Rockey DC, Caldwell SH, Goodman ZD, Nelson RC, Smith AD; American Association for the Study of Liver Diseases. Liver biopsy. *Hepatology* 2009;49:1017-1044.
39. Ahn SJ, Lee JM, Lee DH, Lee SM, Yoon JH, Kim YJ, et al. Real-time US-CT/MR fusion imaging for percutaneous radiofrequency ablation of hepatocellular carcinoma. *J Hepatol* 2017;66:347-354.
40. Lee MW, Rhim H, Cha DI, Kim YJ, Choi D, Kim YS, et al. Percutaneous radiofrequency ablation of hepatocellular carcinoma: fusion imaging guidance for management of lesions with poor conspicuity at conventional sonography. *AJR Am J Roentgenol* 2012;198:1438-1444.
41. Park HJ, Lee MW, Lee MH, Hwang J, Kang TW, Lim S, et al. Fusion imaging-guided percutaneous biopsy of focal hepatic lesions with poor conspicuity on conventional sonography. *J Ultrasound Med* 2013;32:1557-1564.
42. Song KD, Lee MW, Rhim H, Cha DI, Chong Y, Lim HK. Fusion imaging-guided radiofrequency ablation for hepatocellular carcinomas not visible on conventional ultrasound. *AJR Am J Roentgenol* 2013;201:1141-1147.
43. Huang JX, Shi CG, Xu YF, Fu J, Zhong Y, Liu LZ, et al. The benefit of contrast-enhanced ultrasound in biopsies for focal liver lesions: a retrospective study of 820 cases. *Eur Radiol* 2022;32:6830-6839.
44. Wu W, Jing X, Xue GQ, Zhu XL, Wang J, Du RQ, et al. A multicenter randomized controlled study of contrast-enhanced US versus US-guided biopsy of focal liver lesions. *Radiology* 2022;305:721-728.
45. Masuzaki R, Shiina S, Tateishi R, Yoshida H, Goto E, Sugioka Y, et al. Utility of contrast-enhanced ultrasonography with Sonazoid in radiofrequency ablation for hepatocellular carcinoma. *J Gastroenterol Hepatol* 2011;26:759-764.
46. Dohmen T, Kataoka E, Yamada I, Miura K, Ohshima S, Shibuya T, et al. Efficacy of contrast-enhanced ultrasonography in radiofrequency ablation for hepatocellular carcinoma. *Intern Med* 2012;51:1-7.
47. Lee JY, Minami Y, Choi BI, Lee WJ, Chou YH, Jeong WK, et al. The AF-SUMB consensus statements and recommendations for the clinical practice of contrast-enhanced ultrasound using sonazoid. *Ultrasonography* 2020;39:191-220.
48. Yanagisawa K, Moriyasu F, Miyahara T, Yuki M, Iijima H. Phagocytosis of ultrasound contrast agent microbubbles by Kupffer cells. *Ultrason Med Biol* 2007;33:318-325.
49. Huang Q, Li J, Zeng Q, Tan L, Zheng R, He X, et al. Value of artificial ascites to assist thermal ablation of liver cancer adjacent to the gastrointestinal tract in patients with previous abdominal surgery. *BMC Cancer* 2020;20:763.
50. Rhim H, Lim HK, Kim YS, Choi D. Percutaneous radiofrequency ablation with artificial ascites for hepatocellular carcinoma in the hepatic dome: initial experience. *AJR Am J Roentgenol* 2008;190:91-98.
51. Park SJ, Lee DH, Han JK. Reducing pain by artificial ascites infusion during radiofrequency ablation for subcapsular hepatocellular carcinoma. *Cardiovasc Intervent Radiol* 2021;44:565-573.
52. Koda M, Ueki M, Maeda Y, Mimura K, Okamoto K, Matsunaga Y, et al. Percutaneous sonographically guided radiofrequency ablation with artificial pleural effusion for hepatocellular carcinoma located under the diaphragm. *AJR Am J Roentgenol* 2004;183:583-588.
53. Nakamura S, Nouse K, Onishi H, Kuwaki K, Hagihara H, Takeuchi Y, et al. Prevention of vagotonia and pain during radiofrequency ablation of liver tumors. *Hepatol Res* 2014;44:1367-1370.
54. Yokoyama K, Ikeda O, Kawanaka K, Nakasone Y, Inoue S, Tamura Y, et al. Pain control in patients with hepatocellular carcinoma treated by percutaneous radiofrequency ablation: comparison of the efficacy of one-shot and continuous intravenous fentanyl delivery. *Acta Radiol* 2014;55:1219-1225.
55. Dou Z, Lu F, Ren L, Song X, Li B, Li X. Efficacy and safety of microwave ablation and radiofrequency ablation in the treatment of hepatocellular carcinoma: a systematic review and meta-analysis. *Medicine (Baltimore)* 2022;101:e29321.
56. Wang C, Wang H, Yang W, Hu K, Xie H, Hu KQ, et al. Multicenter randomized controlled trial of percutaneous cryoablation versus radiofrequency ablation in hepatocellular carcinoma. *Hepatology* 2015;61:1579-1590.
57. Huang GL, Liu M, Zhang XE, Liu BX, Xu M, Lin MX, et al. Multiple-

- electrode switching-based radiofrequency ablation vs. conventional radiofrequency ablation for single early-stage hepatocellular carcinoma ranging from 2 to 5 cm. *Front Oncol* 2020;10:1150.
58. Lee J, Lee JM, Yoon JH, Lee JY, Kim SH, Lee JE, et al. Percutaneous radiofrequency ablation with multiple electrodes for medium-sized hepatocellular carcinomas. *Korean J Radiol* 2012;13:34-43.
59. Laeseke PF, Frey TM, Brace CL, Sampson LA, Winter TC 3rd, Ketzler JR, et al. Multiple-electrode radiofrequency ablation of hepatic malignancies: initial clinical experience. *AJR Am J Roentgenol* 2007;188:1485-1494.
60. Suh YS, Choi JW, Yoon JH, Lee DH, Kim YJ, Lee JH, et al. No-touch vs. conventional radiofrequency ablation using twin internally cooled wet electrodes for small hepatocellular carcinomas: a randomized prospective comparative study. *Korean J Radiol* 2021;22:1974-1984.
61. Park SJ, Cho EJ, Lee JH, Yu SJ, Kim YJ, Yoon JH, et al. Switching monopolar no-touch radiofrequency ablation using octopus electrodes for small hepatocellular carcinoma: a randomized clinical trial. *Liver Cancer* 2021;10:72-81.
62. Lee DH, Lee MW, Kim PN, Lee YJ, Park HS, Lee JM. Outcome of no-touch radiofrequency ablation for small hepatocellular carcinoma: a multicenter clinical trial. *Radiology* 2021;301:229-236.
63. Ei S, Hibi T, Tanabe M, Itano O, Shinoda M, Kitago M, et al. Cryoablation provides superior local control of primary hepatocellular carcinomas of >2 cm compared with radiofrequency ablation and microwave coagulation therapy: an underestimated tool in the toolbox. *Ann Surg Oncol* 2015;22:1294-1300.
64. Ahmed M, Solbiati L, Brace CL, Breen DJ, Callstrom MR, Charboneau JW, et al. Image-guided tumor ablation: standardization of terminology and reporting criteria--a 10-year update. *Radiology* 2014;273:241-260.
65. Crocetti L, de Baere T, Lencioni R. Quality improvement guidelines for radiofrequency ablation of liver tumours. *Cardiovasc Intervent Radiol* 2010;33:11-17.
66. Dodd GD 3rd, Napier D, Schoolfield JD, Hubbard L. Percutaneous radiofrequency ablation of hepatic tumors: postablation syndrome. *AJR Am J Roentgenol* 2005;185:51-57.
67. Carrafiello G, Laganà D, Ianniello A, Dionigi G, Novario R, Recaldini C, et al. Post-radiofrequency ablation syndrome after percutaneous radiofrequency of abdominal tumours: one centre experience and review of published works. *Australas Radiol* 2007;51:550-554.
68. Kim JW, Shin JH, Kim PN, Shin YM, Won HJ, Ko GY, et al. Embolization for bleeding after hepatic radiofrequency ablation. *J Vasc Interv Radiol* 2017;28:356-365.e2.
69. Chang IS, Kim YJ, Park SW, Park HS, Jeon HJ, Chang SH, et al. Delayed hepatic rupture after radiofrequency ablation for colorectal hepatic metastasis: management with transcatheter arterial embolization. *Ann Surg Treat Res* 2014;87:41-43.
70. Livraghi T, Meloni F, Di Stasi M, Rolle E, Solbiati L, Tinelli C, et al. Sustained complete response and complications rates after radiofrequency ablation of very early hepatocellular carcinoma in cirrhosis: is resection still the treatment of choice? *Hepatology* 2008;47:82-89.
71. Tan W, Deng Q, Lin S, Wang Y, Xu G. Comparison of microwave ablation and radiofrequency ablation for hepatocellular carcinoma: a systematic review and meta-analysis. *Int J Hyperthermia* 2019;36:264-272.
72. Kim R, Kang TW, Cha DI, Song KD, Lee MW, Rhim H, et al. Percutaneous cryoablation for perivascular hepatocellular carcinoma: therapeutic efficacy and vascular complications. *Eur Radiol* 2019;29:654-662.
73. Ko SE, Lee MW, Rhim H, Kang TW, Song KD, Cha DI, et al. Comparison of procedure-related complications between percutaneous cryoablation and radiofrequency ablation for treating periductal hepatocellular carcinoma. *Int J Hyperthermia* 2020;37:1354-1361.
74. Song KD. Percutaneous cryoablation for hepatocellular carcinoma. *Clin Mol Hepatol* 2016;22:509-515.
75. Choi D, Lim HK, Kim MJ, Kim SJ, Kim SH, Lee WJ, et al. Liver abscess after percutaneous radiofrequency ablation for hepatocellular carcinomas: frequency and risk factors. *AJR Am J Roentgenol* 2005;184:1860-1867.