

Three-Column Fracture in the Thoracolumbar Junction Caused by Low-Energy Trauma in a Patient with Baastrup Disease - A Case Report -

In Keun Park, M.D., Jun-Ku Lee, M.D., Jung Gook Seo, M.D.

J Korean Soc Spine Surg 2019 Dec;26(4):166-171.

Originally published online December 31, 2019;

<https://doi.org/10.4184/jkss.2019.26.4.166>

Korean Society of Spine Surgery

SMG-SNU Boramae Medical Center, 20, Boramae-ro 5-gil, Dongjak-gu, Seoul 07061, Korea

Tel: +82-2-831-3413 Fax: +82-2-831-3414

©Copyright 2017 Korean Society of Spine Surgery

pISSN 2093-4378 eISSN 2093-4386

The online version of this article, along with updated information and services, is
located on the World Wide Web at:

<http://www.krspine.org/DOIx.php?id=10.4184/jkss.2019.26.4.166>

This is an Open Access article distributed under the terms of the Creative Commons Attribution Non-Commercial License (<http://creativecommons.org/licenses/by-nc/4.0>) which permits unrestricted non-commercial use, distribution, and reproduction in any medium, provided the original work is properly cited.

Three-Column Fracture in the Thoracolumbar Junction Caused by Low-Energy Trauma in a Patient with Baastrup Disease - A Case Report -

In Keun Park, M.D., Jun-Ku Lee, M.D., Jung Gook Seo, M.D.

Department of Orthopedic Surgery, Inje University Seoul Paik Hospital, Seoul, Korea

Study Design: Case report.

Objectives: We report a case of 3-column fracture caused by low-energy trauma in a patient with Baastrup disease who complained of acute radiating pain and motor weakness in the lower limbs after 3 weeks of conservative treatment. Subsequently, posterior fusion surgery was performed.

Summary of Literature Review: Baastrup disease is characterized by enlargement and close approximation of adjacent spinous processes, and it mostly affects the L4-5 level of the spine. In patients with Baastrup disease affecting multiple levels of the lumbar spine, low-energy trauma can cause an unstable 3-column fracture with neurological compromise. Early recognition and surgical treatment prior to the emergence of a neurological deficit are required.

Materials and Methods: An 84-year-old woman presented with back pain after falling down backward and colliding with the edge of a shelf at ground level. Considering the patient's general condition and age, she was initially treated with close observation and placement of a spinal brace with serial radiographic follow-up.

Results: Computed tomography found 3-column fracture at the T11 level, which is quite rare in cases of minor trauma. At a 3-week follow-up, she complained of gradual lower extremity weakness, and her general lower extremity motor function decreased to grade 1–2. The patient underwent posterior fusion 2 levels above and below the affected vertebral body (T9-10-12-L1). Surgery was uneventful and the patient's motor function recovered.

Conclusions: In patients with Baastrup disease affecting multiple levels of the lumbar spine, based on our experience, low-energy trauma can cause an unstable 3-column fracture with neurological compromise. We highly recommend scrutiny of the interspinous space in elderly patients, especially those with a spinal fracture caused by low-energy trauma.

Key words: Baastrup's disease, Kissing spine, Three-column fracture, Posterior fusion

Baastrup's disease, also known as "kissing spine syndrome," is characterized by enlargement and close approximation of adjacent spinous processes, and mostly affects the L4–5 level of the spine. Patients with this condition often complain of back pain increased with extension and relieved by flexion due to pathognomonic curvature of spine. In patients with Baastrup's disease, excessive lordosis of the spine increases the mechanical pressure on the spinous process and may lead to repetitive shearing stress on the interspinous ligament, causing degeneration and collapse.^{1–3)} Consequently, the repetitive shearing movement with contact of the spinous process causes further inflammation of an adventitious bursa, constructional

distortion, sclerosis, and cyst formation.^{1–3)}

Received: August 19, 2019

Revised: September 10, 2019

Accepted: December 4, 2019

Published Online: December 31, 2019

Corresponding author: Jung Gook Seo, M.D.

ORCID ID: Junku Lee: <https://orcid.org/0000-0003-4640-9357>

Jeong Gook Seo: <https://orcid.org/0000-0001-7804-8432>

Department of Orthopaedic Surgery, Seoul Paik Hospital,
Inje University, Jeon-Dong 2 Ga 85 Jung-Gu, Seoul, 04551 Korea

TEL: +82-2-2270-0066, **FAX:** +82-2-2270-0023

E-mail: hd1404@hanafos.com

There have been many pathologic and radiologic studies about Bastrup's disease, but only a few studies exist about its vulnerability to low-energy trauma.⁴⁻⁷ This case report describes a 3-column fracture of the T11 vertebral body in a patient with Bastrup's disease caused by low-energy trauma. To our knowledge, this is the first report of such a case in the literature.

Case Report

The patient provided informed consent for publication of the data concerning the case.

An 84-year-old woman presented to the emergency room with pain of the lower back after falling down backward and sustaining mild trauma of the spine due to contact with the edge of a shelf at ground level. Previously, the patient had not been diagnosed with any other orthopedic disease. Tapping tenderness on the T-L junction was remarkable and analgesic was ineffective, suggesting fracture around the T-L junction level.

A simple lateral radiograph demonstrated remarkable

degenerative disc disease and extreme approximation of the adjacent spinous processes with eburnation of the superior and inferior margins of the spinous process with more manifestation on 3-dimensional computed tomography (CT) (Fig. 1). Laboratory study including HLA-B27 was performed to exclude systemic and systemic disease such as ankylosing spondylitis, confirming negative. The CT scan confirmed the fracture at the T11 level. The fracture included the vertebral body and both lamina with posterior vertebral wall bulging, confirming that it was not a simple compression fracture, but a 3-column fracture of the T11 level, which is quite rare in cases of minor trauma (Fig. 2). We also performed a bone mineral density test to rule out severe osteoporosis (T score of the L-spine, -1.1). Magnetic resonance imaging was also

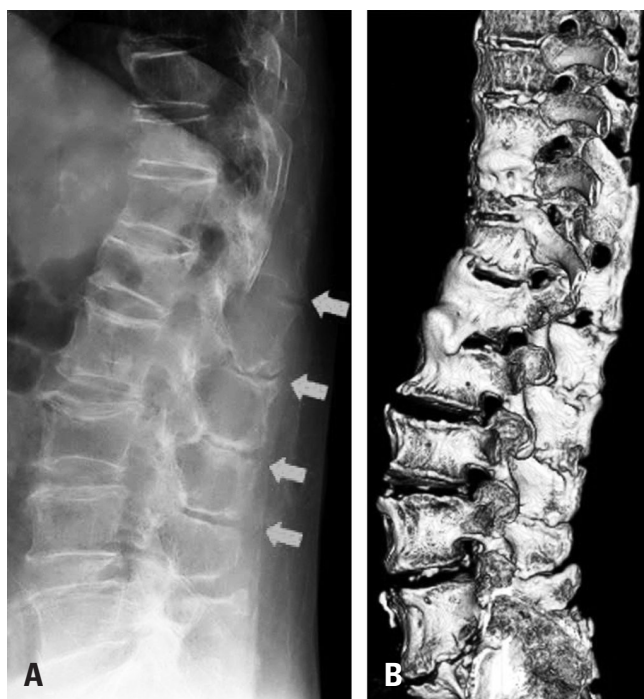

Fig. 1. (A) Initial radiographs showing severe narrowing of the interspinous process (red arrows). (B) Three-dimensional reconstruction of computed tomography images showing Bastrup disease (kissing spine).

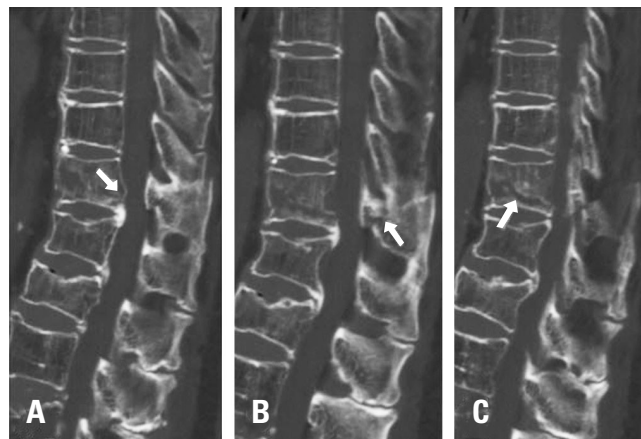


Fig. 2. Serial sagittal computed tomography images showing the 3-column fracture with (A) posterior vertebral wall bulging (red arrow), (B) a displaced posterior column fracture, and (C) a collapsing vertebral body.

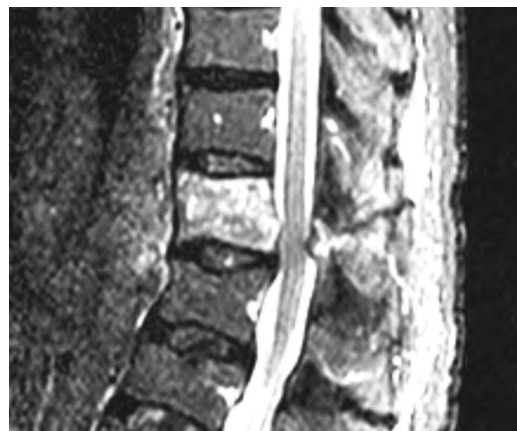

Fig. 3. Magnetic resonance imaging scan showing a mild cord-compressing lesion with buckling of the ligamentum flavum.

performed to determine if there was a cord-compressing lesion, and it showed a clearly delineated acute fracture with a mild cord-compromising lesion at the T11 level (Fig. 3).

Considering the patient's general condition and age, close observation and placement of a spinal brace was performed with serial radiographic follow-up. At the 3-week follow-up, she complained of gradual lower extremity weakness that lasted for 3 days, and the general lower extremity motor grade decreased to grade 1 or 2. Sensory functions may have also been slightly decreased. Therefore, we conducted follow-up CT immediately, and the scan showed progression of canal-compromising lesion to 50% (Fig. 4).

Surgical treatment was performed on the next day after the follow-up CT scan was obtained. Upon initial intraoperative visualization, we found that a portion of the interspinous ligament was shallow throughout the whole T-L spine area, and the adjacent spinous processes were nearly fused. Based on principles of the posteriorly fused spine such as in patients with ankylosing spondylitis and non-specific unstable fracture, posterior fusion was performed above and below 2 levels of the vertebral bodies (T9-10-12-L1) with additional allogenic bone graft (60 cc) to enhance stability (Fig. 5).

At 1 week postoperatively, the patient started walking with assistance of a walker, and lower leg motor function recovered to grade IV. At 2 weeks postoperatively, the patient was able to perform daily activities and advanced physical training

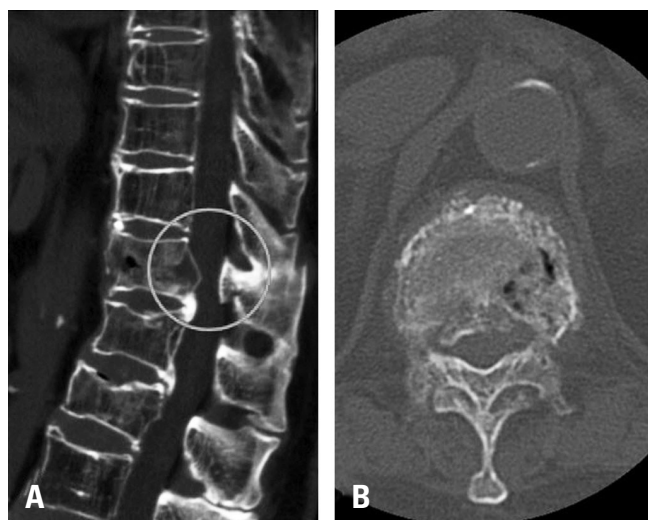


Fig. 4. Progression of the canal-compromising lesion on follow-up (A) sagittal and (B) axial computed tomography images.

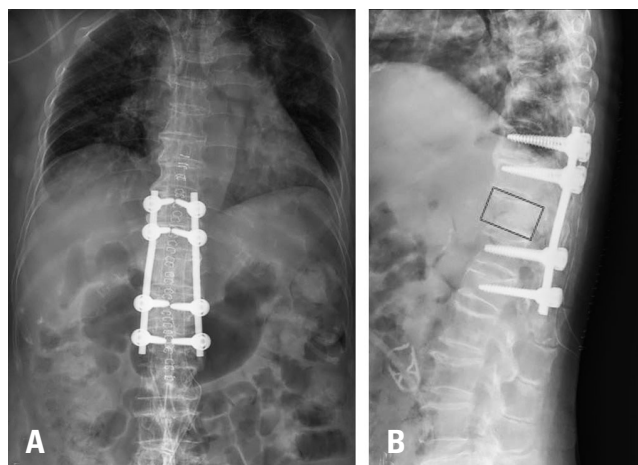


Fig. 5. (A) Simple radiograph after posterior fusion at the T9-10-12-L1 levels. (B) Restored height of the T11 vertebral body on a lateral view (red box).

including bicycling. On post-operative 3 months, the patient declared activity of daily which was same condition of pre-injured level without any displacement on plain x-ray.

This study received an exemption by the Institutional Review Board of our institute.

Discussion

Our patient sustained 3-column fracture at the T11 level caused by low-energy trauma. We hypothesize that the extremely stiff spine caused by chronic approximation of adjacent spinous processes in multiple levels of the lumbar spine with Baastrup's disease facilitated this fracture. In most of the cases, Baastrup's disease is associated with degenerative condition such as height loss of disc space, spondylolisthesis, and spondylosis with osteophyte formation, and these conditions can increase the stiffness of spine. Close observation with possible operative stabilization is necessary for this type of fracture.

Baastrup's disease was first described in 1933 as chronic contact or neoarthrosis between spinous processes in the lumbar spine that causes various clinical symptoms and structural deformity with radiologic findings.⁸⁾ Most patients with Baastrup's disease are elderly with a known degenerative spine disease or hyperlordosis. The incidence of Baastrup's disease is more common than expected. Kwong et al. reported that based on computed tomography, 413 (41.0%)

patients could be classified as having Baastrup's disease with an incidence of 81.3% among patients older than 80 years of age.²⁾ Maes et al. also reported an overall incidence of 8.2% with the presence of a bursa between the spinous processes as a diagnostic criteria based on magnetic resonance imaging.³⁾ Until now, there has been a lack of understanding regarding the pathogenesis of this disease entity, and previous studies focused on explaining the source of back pain and how to alleviate the symptom, low back pain.⁴⁻⁷⁾

Baastrup's disease usually affects the lumbar spine, with the L4/5 level being most commonly affected by a lesion.^{2,3)} One-level involvement is more frequent (35.4%); however, as many as 5 levels were found to be affected in 4.1% of patients.⁵⁾ The entire lumbar spine was affected in our patient, as shown on initial radiographs in Figure 1A. During the operation, we confirmed the lack of an interspinous interval distance, and the adjacent spinous processes were nearly fused, especially at the level of the lumbar spine. According to previous knowledge of spinal ankylosing disorders including ankylosing spondylitis, disseminated hyperostosis of the spine, and end-stage spondylosis, there is a risk of thoracolumbar fractures and ligamentous injuries even after trivial trauma that lead to neurologic deteriorations.⁹⁾ Regarding injury force that is strong enough to fracture osteopenic bone, stiffness makes the spine more vulnerable to sustaining advanced fracture. We assumed that less mobility in the lumbar spine due to Baastrup's disease caused fracture of the T11 vertebral body after low-energy trauma, and this very unstable fracture affected 3 vertebral columns. Given the patient's older age, we chose conservative management of the spine with brace immobilization. However, the fractured posterior vertebral body, the middle column, involved the spinal canal, resulting in neurologic compromise. After immediate posterior fusion and screw instrumentation to restore the vertebral height, the patient gradually recovered from the neurologic deficit. Besides, the fusion levels needed to extend above and below 2 vertebral bodies considering the fused spine. We are not aware of any previous studies in the literature that describe an unstable 3-column fracture in a patient with Baastrup's disease.

In Baastrup's disease that affects multiple levels of the lumbar spine, based on our experience, low-energy trauma can cause an unstable 3-column fracture with neurologic compromise. The limitation of this report is that initial plain

radiograph shows suspicious disseminated idiopathic skeletal hyperostosis (DISH) condition which is known to cause unstable fracture in elderly by minor trauma, and it is hard to prove what develops first because they usually present in combined condition.¹⁰⁾ However, considering high prevalence of DISH in male patients, we assumed that severe condition of Baastrup's disease provoked the hyperostosis of thoracic spine. Therefore, we highly recommend scrutiny of the interspinous space in elderly patients first, especially those with spine fracture caused by low-energy trauma.

REFERENCES

1. Bywaters EG, Evans S. The lumbar interspinous bursae and Baastrup's syndrome. An autopsy study. *Rheumatol Int.* 1982; 2(2):87-96
2. Kwong Y, Rao N, Latief K. MDCT findings in Baastrup disease: disease or normal feature of the aging spine? *AJR Am J Roentgenol.* 2011 May;196(5):1156-9. DOI: 10.2214/AJR.10.5719.
3. Maes R, Morrison WB, Parker L, et al. Lumbar interspinous bursitis (Baastrup disease) in a symptomatic population: prevalence on magnetic resonance imaging. *Spine (Phila Pa 1976).* 2008 Apr 1;33(7):E211-5. DOI: 10.1097/BRS.0b013e318169614a.
4. Pinto PS, Boutin RD, Resnick D. Spinous process fractures associated with Baastrup disease. *Clin Imaging.* 2004 May-Jun;28(3):219-22. DOI: 10.1016/S0899-7071(03)00156-6.
5. Alonso F, Bryant E, Iwanaga J, et al. Baastrup's Disease: A Comprehensive Review of the Extant Literature. *World Neurosurg.* 2017 May;101:331-4. DOI: 10.1016/j.wneu.2017.02.004.
6. Beks JW. Kissing spines: fact or fancy? *Acta Neurochir (Wien).* 1989;100(3-4):134-5.
7. Jacobson HG, Tausend ME, Shapiro JH, et al. The sway-back syndrome. *Am J Roentgenol Radium Ther Nucl Med.* 1958 Apr;79(4):677-83.
8. Baastrup CI. On the Spinous Processes of the Lumbar Vertebrae and the Soft Tissues Between them, and on Pathological Changes in that Region. *Acta Radiologica.* 1933;14(1):52-5. DOI: 10.3109/00016923309132353.
9. Rustagi T, Drazin D, Oner C, et al. Fractures in Spinal An-

kylosing Disorders: A Narrative Review of Disease and Injury Types, Treatment Techniques, and Outcomes. *J Orthop Trauma*. 2017 Sep;31 Suppl 4:S57–s74. DOI: 10.1097/bot.0000000000000953.

10. Mata S, Fortin PR, Fitzcharles MA, et al. A controlled study of diffuse idiopathic skeletal hyperostosis. Clinical features and functional status. *Medicine (Baltimore)*. 1997 Mar; 76(2):104–17. DOI: 10.1097/00005792-199703000-00003.

극돌기간 관절형성증 환자에서 저에너지 손상에 의해 발생한 흉요추부의 삼주 골절 - 증례 보고 -

박인근 · 이준구 · 서정국

인제대학교 서울백병원 정형외과학교실

연구 계획: 증례 보고

목적: 본 증례 보고는 Bastrup's disease를 가진 환자에서 저에너지 손상으로 발생한 삼주골절의 3주간의 보존적 치료 후 하지 방사통과 근력 감소로 후방 고정술을 시행한 증례에 대한 보고이다.

선행 연구문헌의 요약: Bastrup's disease는 주로 제 4, 5요추를 침범하는 가시돌기의 거대화과 가시돌기 간격의 협착을 특징으로 하는 질환이다. 이 Bastrup's disease 가 요추의 여러 층을 침범하는 경우, 저에너지 손상에 의해서도 불안정한 삼주골절이 발생 할 수 있다. 신경학적 결손이 발생하기 전 이 질병의 조기 발견과 적절한 수술적 처치가 필요할 것으로 생각된다.

대상 및 방법: 84세 여성 환자로 뒤로 넘어지며 선반 모서리에 등을 부딪힌 후 발생한 요통을 주소로 내원하였다. 특별한 과거력은 없었으며, 환자의 연령과 전신 상태를 고려하여 척추 보호대를 착용하며 방사선 촬영을 추시 하였다.

결과: 촬영한 CT 영상에서 저에너지 손상에서 드문 삼주골절이 제 11흉추에서 발견되었다. 보존적 치료를 시행한 지 3주 후 환자는 점진적인 하지 근력의 감소를 호소하였고, 골절 부위의 위, 아래 각각 2레벨(제 9,10,12흉추 및 제 1요추) 을 고정하는 후방 고정술을 시행하였다. 수술은 특별한 일 없이 마쳤으며 근력은 회복되었다.

결론: 저자들의 경험에 비추어 보았을 때, 척추의 여러층을 침범한 Bastrup's disease는 저에너지 손상에도 신경손상이 동반된 불안정한 삼주골절이 발생 할 수 있다. 고령 환자에 있어서 저에너지 손상으로 발생한 척추 골절이 있을 시 가시돌기 간격에 대한 철저한 평가가 필요할 것으로 생각된다.

색인 단어: 삼주골절, 후방 유합술, 극돌기간 관절형성증

약칭 제목: 극돌기간 관절형성증 환자의 삼주 골절

접수일: 2019년 8월 19일

수정일: 2019년 9월 10일

게재확정일: 2019년 12월 4일

교신저자: 서정국

서울시 중구 마른내로 9(저동2가 85) 인제대학교 서울백병원 정형외과학교실

TEL: 02-2270-0066

FAX: 02-2270-0023

E-mail: hd1404@hanafos.com