

Vertebral Body Fracture after Oblique Lumbar Interbody Fusion in 2 Patients - A Case Report -

Sang-Bum Kim, M.D., You-Gun Won, M.D., Jae-Shin Lee, M.D.,
Jae-Sung Ahn, M.D., Chan Kang, M.D., Gi-Soo Lee, M.D.

J Korean Soc Spine Surg 2018 Mar;25(1):35-39.

Originally published online March 31, 2018;

<https://doi.org/10.4184/jkss.2018.25.1.35>

Korean Society of Spine Surgery

Asan Medical Center 88, Olympic-ro 43 Gil, Songpa-gu, Seoul, 05505, Korea

Tel: +82-2-483-3413 Fax: +82-2-483-3414

©Copyright 2017 Korean Society of Spine Surgery

pISSN 2093-4378 eISSN 2093-4386

The online version of this article, along with updated information and services, is
located on the World Wide Web at:

<http://www.krspine.org/DOIx.php?id=10.4184/jkss.2018.25.1.35>

This is an Open Access article distributed under the terms of the Creative Commons Attribution Non-Commercial License (<http://creativecommons.org/licenses/by-nc/4.0>) which permits unrestricted non-commercial use, distribution, and reproduction in any medium, provided the original work is properly cited.

Vertebral Body Fracture after Oblique Lumbar Interbody Fusion in 2 Patients - A Case Report -

Sang-Bum Kim, M.D., You-Gun Won, M.D., Jae-Shin Lee, M.D.,

Jae-Sung Ahn, M.D.*, Chan Kang, M.D.*, Gi-Soo Lee, M.D.*

Department of Orthopedic Surgery, Konyang University College of Medicine

**Department of Orthopaedic Surgery, Chungnam National University School of Medicine*

Study Design: Although the frequency of the oblique lumbar interbody fusion (OLIF) procedure has increased in recent years, reports on its complications remain rare. We report 2 cases of vertebral fracture after OLIF.

Objectives: We aimed to report 2 cases of coronal vertebral fracture after an OLIF procedure in non-osteoporotic patients without significant trauma, and to review the complications of OLIF.

Summary of Literature Review: There is a growing but limited literature describing early postoperative complications after OLIF.

Materials and Methods: Patient 1 was an obese woman who underwent 2-level OLIF with posterior instrumentation procedures and subsequently experienced 2-level coronal plane fractures. Patient 2 was an elderly man who underwent 3-level OLIF without posterior instrumentation and experienced 1 coronal vertebral fracture. We report vertebral body fracture as a complication of OLIF through these 2 cases.

Results: Patient 1 was treated nonsurgically after the fractures. The fractures healed uneventfully. However, patient 2 underwent posterior instrumented fusion and had a solid bridging bone above and below the fracture. Factors potentially contributing to these fractures are discussed.

Conclusions: OLIF is an effective procedure for several spinal diseases. However, fracture can occur after OLIF even in non-osteoporotic patients. Factors such as intraoperative end-plate breach, subsidence, cage rolling, and inadequate posterior instrumentation could contribute to the development of fractures after oblique interbody fusion.

Key words: Oblique lumbar interbody fusion, Coronal vertebral fracture, Complication

Lumbar interbody fusion (LIF) is an effective procedure for the management of various spinal diseases, including lumbar degenerative diseases, spinal deformities, trauma, infections, and neoplasms.¹⁾ There are many approaches to performing LIF, each with its own advantages and disadvantages. But, some authorities have reported complication rates as high as 37.5% for initial posterior LIF surgery, whereas others have quoted rates of new radiculopathy ranging from 13.0% to 16.4%. Adjacent segment degeneration, graft migration or subsidence, collapse of the intervertebral space with resultant neuroforaminal stenosis, and the potential for segmental instability or pseudarthrosis are among the complications that may be associated with this type of surgery.²⁾

Oblique LIF (OLIF) is a new technique that allows fusion of the lumbar spine through a single small incision, with faster

surgery times and an easier approach than any previous technique.³⁾ Although the frequency of OLIF has increased in recent years, reports on its complications remain rare. We report on two cases of coronal vertebral fracture after OLIF in two patients without significant trauma, and reviewed the complications of OLIF.

Received: October 31, 2017

Revised: November 7, 2017

Accepted: February 13, 2018

Published Online: March 31, 2018

Corresponding author: Gi-Soo Lee, M.D.

ORCID ID: Gi-Soo Lee: <https://orcid.org/0000-0002-4085-5674>

Sang-Bum Kim: <https://orcid.org/0000-0002-7497-9077>

Department of Orthopedic Surgery, Chungnam National University Hospital, 282, Munhwa-ro, Jung-gu, Daejeon, Republic of Korea

TEL: +82-42-338-2438, **FAX:** +82-42-545-2373

E-mail: gs1899@hanmail.net

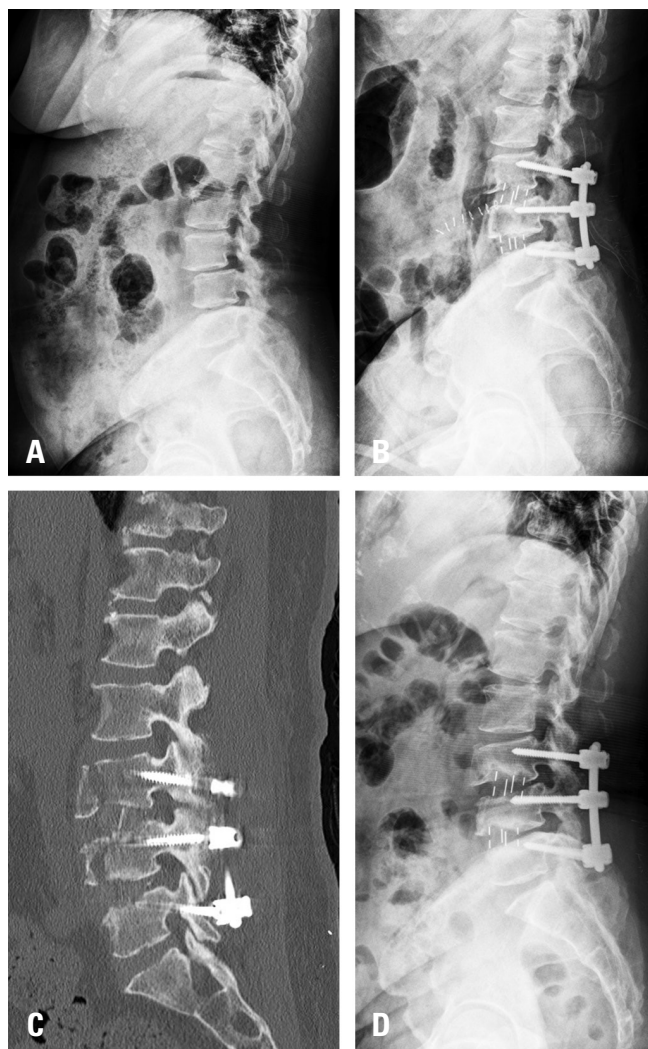


Fig. 1. (A) Preoperative and (B) immediate postoperative lateral radiographs of a 60-year-old female patient. (C) Computed tomography scans showing a L3-4 vertebral coronal fracture at 1 week postoperatively. The fracture site showed union at 6 months postoperatively. (D) The fracture site showed union at 6 months postoperatively.

Case Report

Patient 1 was a 60-year-old woman (body mass index [BMI] 32, osteopenia T-score -1.1) presenting with back pain, radiating pain from the posterior area of both thighs to the calves, and neurogenic claudication for 6 months. Preoperative radiography, computed tomography (CT), and magnetic resonance imaging (MRI) demonstrated L3-L4, L4-L5 spinal stenosis and L3-L4 spondylolisthesis. The preoperative disc height was 10mm at L3-4 and 9.5mm at L4-5. She underwent surgery including OLIF at L3-L4, L4-L5 with decompression

and posterior instrumentation at L3-L5. L3-4 used 6 degrees, 14mm height cage and L4-5 used 6 degrees, 12mm height cage. Back pain occurred 1 week postoperatively. Radiologic and CT images showed coronal fracture at L3 and L4 vertebra. The patient had no radiculopathy symptoms, and radiologically, no neuroforaminal stenosis associated with fracture was deemed to have occurred and we decided to treat it conservatively. She was followed up and allowed to walk with wearing orthosis. Bone union was seen without any complication at 6 months postoperatively (Fig. 1).

Patient 2 was a 68-year-old man (BMI 24, osteopenia T-score -1.3) presenting with back pain, radiating pain from the right calf to the foot, and claudication for 2 years. He underwent right L4-L5 and left L5-S1 laminotomy in 2007. Preoperative radiography and MRI demonstrated L3-L5, L5-S1 spinal stenosis. The preoperative disc height was 10mm at L3-4, 10.5mm at L4-5 and 8mm at L5-S1. He underwent surgery including three-level OLIF, L3-L5 and L5-S1, without posterior instrumentation. L3-4 used 6 degrees and 12mm height cage, L4-5 used 12 degrees and 14mm height cage and L5-S1 used 12 degrees and 12 mm interbody spacer. The posterior instrument was planned to be performed two weeks later. At 10 days postoperatively, without inciting trauma, he developed acute severe back pain. CT demonstrated coronal plane fracture of the L4 vertebral body. Neuroforaminal space narrowing findings are seen. Thus, he underwent posterior instrumentation and distraction at L3-L5, L5-S1 (Fig. 2). On the follow-up, some neural compression due to cage migration and vertebral fracture are continued, but the symptoms are mildly observed.

The two patients were supplemented with Solera (Medtronic, Memphis, TN, USA) posterior instrumentation by using the cortical bone trajectory. Anterior polyether ether ketone cages (Clydesdale, Medtronic) and demineralized bone matrix (Sofamor Danek, Medtronic) was mixed with bone marrow aspirate.

This paper has been reviewed since IRB approval (KYUH 2017-11-011).

Discussion

Recently, the frequency of OLIF has increased and various groups have provided early evidence supporting

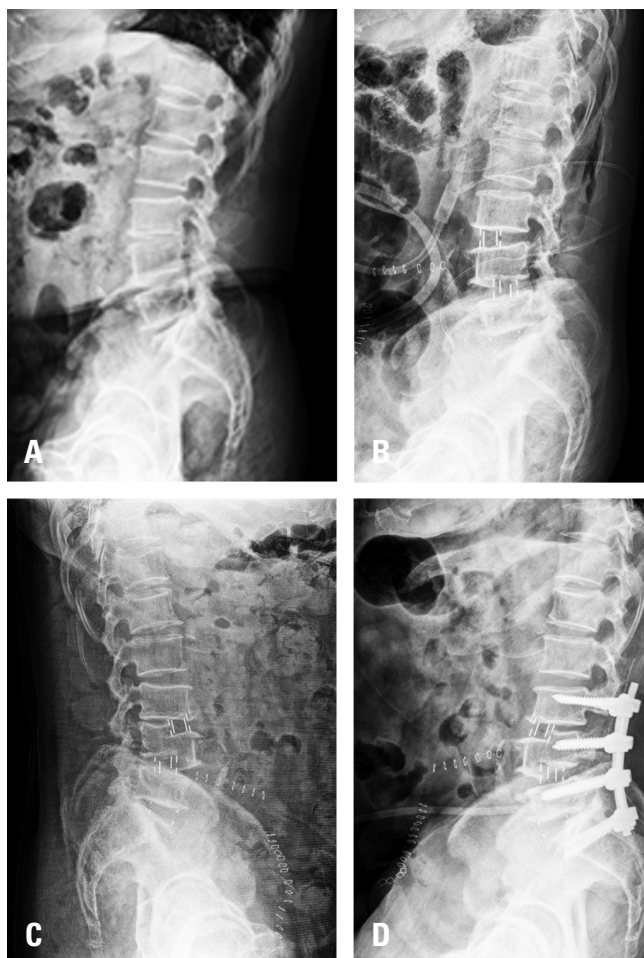

Fig. 2. (A) Preoperative and (B) immediate postoperative lateral radiographs of a 68-year-old male patient. (C) At 2 weeks postoperatively, a radiograph showed a L4 vertebral body coronal fracture. (D) Additional posterior instrumentation was performed.

OLIF as a viable alternative to existing LIF techniques, by showing radiologic and clinical improvements in patients with degenerative lumbar diseases, including degenerative spondylolisthesis, kyphoscoliosis, and discogenic pain.⁴⁾

Author performed a total of 39 cases OLIF procedure. The average operating time of OLIF was 85.1 min, mean blood loss was 185 mL, and average length of postoperative hospital stay was 10.3 days. Indirect spinal canal decompression, independent of posterior laminectomy, after OLIF surgery has been described with a 19.0%–28.5% increase in cross-sectional thecal sac area and a 51.0%–78.3% increase in disc height on MRI. Vertebral body fracture complications occurred in 2 cases (5.13%).

Although OLIF has recently been used with good results, there are few reports on complications related to OLIF. Woods et al.³⁾ reported the complication and fusion rates in a study comprising 137 patients surgically treated with the oblique lateral interbody fusion approach. They observed a complication rate of 11.7%, which included subsidence, postoperative ileus, and vascular injury (2.9%). There were no neurologic, ureteral, or visceral injuries. The fusion rate was 97.9% at 6 months after surgery.

Li et al.⁴⁾ reported an incidence of intraoperative complications of 1.5% and that of postoperative complications of 9.9%. Major vessel injury was observed in 0.9% of cases and was the most common intraoperative complication; others included peritoneal injury, dural tear, and transient motor electrophysiology deficits.

However, some studies reported higher complications than the above studies. Abe et al.⁵⁾ reported the development of complications during the perioperative period after oblique lateral interbody fusion surgery in 155 patients. The complication rate was 48.3%. The most common complication was endplate fracture/subsidence (18.7%), and other complications included transient psoas weakness and thigh numbness (13.5%) and segmental artery injury (2.6%). Almost all complications were transient, except for 1.9% that involved neurologic and ureter injuries.

Despite a report showing that most complications were significantly reduced with OLIF compared with previous surgical procedures,⁶⁾ there are no established results yet.

Karan et al.⁷⁾ reported vertebral body fracture in patients with osteoporosis undergoing extreme lateral interbody fusion. However, few cases of vertebral fracture caused by the interbody cage after OLIF in patients with relatively low osteoporosis, as in our cases, have been reported. So, we discuss the complications of OLIF and factors that may cause complications.

Some biomechanical scenarios may have resulted in this coronal vertebral fracture pattern. Interbody fusion cages concentrate stress at the interface between the cage and the adjacent end plates. This places a stress riser in an area of stress concentration, possibly resulting in fracture. And, if the OLIF cage subsides into the vertebral end plates, some settling of the instrumented segment and loss of disc height will result. As the disc space loses height, the OLIF screws would tend to cut

through the vertebral bodies in the coronal plane, leading to fracture.

Coronal plane vertebral fractures can occur in non-osteoporotic patients treated with OLIF. Factors such as obesity, osteopenia, intraoperative end-plate breach, graft subsidence, destruction by screws, cage rolling because of the cage aspect ratio, overdistraction, oversized graft placement, and inadequate construct stability in the sagittal plane could contribute to the development of vertebral body fractures after OLIF.⁸⁾

In the author's case, the two patient may have caused a fracture of the vertebral body using a relatively large cage compared to the disc height. Complications may occur in the OLIF in relation to the cage size. An attempt at inserting an oversized cage may also lead to nerve root injury. It is critical that care be taken to protect the dural sac and exiting nerve root during discectomy, end-plate preparation, and cage insertion. But, failure to achieve adequate distraction of the annulus fibrosus and undersizing the cage can risk pseudarthrosis and cage migration with potential injury to the neural elements.

The second case was caused by segmental instability immediately after surgery without posterior instrument. In the standing position, 80% of spine loads are transmitted through the anterior column.⁹⁾ The implant or graft must be capable of withstanding these loads to allow fusion to occur. Cage migration rates as high as 8% have been seen after uninstrumented PLIF surgery and often require revision surgery.¹⁰⁾ Spinal posterior instrumentation has been shown to increase the fusion rate by limiting the motion across the fusion segments. The vertebral body fracture was caused by laminotomy in past history and uninstrumentation, and the loading of cage in unbonded state.

In both cases, the lateral release was well performed in all cases, but the absence of anterior longitudinal ligament release was considered to be one of the factors causing the coronal fracture of the vertebral body. Our cases serve to caution surgeons that OLIF is not without risks of postoperative clinical complications, even in non-osteoporotic patients, especially in cage-related fractures of the vertebrae.

REFERENCES

1. Mobbs RJ, Phan K, Malham G, et al. Lumbar interbody fusion: techniques, indications and comparison of interbody fusion options including PLIF, TLIF, MI-TLIF, OLIF/ATP, LLIF and ALIF. *J Spine Surg*. 2015 Dec;1(1):2–18. DOI: 10.3978/j.issn.2414-469X.2015.10.05.
2. Hosono N, Namekata M, Makino T, et al. Perioperative complications of primary posterior lumbar interbody fusion for nonisthmic spondylolisthesis: analysis of risk factors. *J Neurosurg Spine*. 2008 Nov;9(5):403–7. DOI: 10.3171/SPI.2008.9.11.403.
3. Woods KR, Billys JB, Hynes RA. Technical description of oblique lateral interbody fusion at L1–L5 (OLIF25) and at L5–S1 (OLIF51) and evaluation of complication and fusion rates. *Spine J*. 2017 Apr;17(4):545–53. DOI: 10.1016/j.spinee.2016.10.026.
4. Li JX, Phan K, Mobbs R. Oblique lumbar interbody fusion: technical aspects, operative outcomes, and complications. *World Neurosurg*. 2017 Feb;98:113–23. DOI: 10.1016/j.wneu.2016.10.074.
5. Abe K, Orita S, Mannoji C, et al. Perioperative complications in 155 patients who underwent oblique lateral interbody fusion surgery: perspectives and indications from a retrospective, multicenter survey. *Spine (Phila Pa 1976)*. 2017 Jan 1;42(1):55–62. DOI:10.1097/BRS.0000000000001650.
6. Silvestre C, Mac-Thiong J-M, Hilmi R, et al. Complications and Morbidities of Mini-open Anterior Retroperitoneal Lumbar Interbody Fusion: Oblique Lumbar Interbody Fusion in 179 Patients. *Asian Spine J*. 2012 Jun;6(2):89–97. DOI: 10.4184/asj.2012.6.2.89.
7. Dua K, Kepler CK, Huang RC, et al. Vertebral body fracture after anterolateral instrumentation and interbody fusion in two osteoporotic patients. *Spine J*. 2010 Sep;10(9):E11–5. DOI: 10.1016/j.spinee.2010.07.007.
8. Brier-Jones JE, Palmer DK, İnceoğlu S, et al. Vertebral body fractures after transpoas interbody fusion procedures. *Spine J*. 2011 Nov;11(11):1068–72. DOI: 10.1016/j.spinee.2011.07.020.
9. Yang KH, King A. Mechanism of facet load transmission as a hypothesis for low-back pain. *Spine (Phila Pa 1976)*. 1984 Sep;9(6):557–65. DOI: 10.1097/00007632-198409000-00005.
10. Chen L, Yang H, Tang T. Cage migration in spondylolisthesis treated with posterior lumbar interbody fusion using BAK cages. *Spine (Phila Pa 1976)*. 2005 Oct 1;30(19):2171–5. DOI: 10.1097/01.brs.0000180402.50500.5b.

측면 요추간 고정술 이후 발생한 척추체 골절 발생한 두 환자 - 증례 보고 -

김상범 • 원유건 • 이재신 • 안재성* • 강찬* • 이기수*

건양대학교병원 정형외과학교실, *충남대학교병원 정형외과학교실

연구 계획: 최근 측면 척추체간 유합술의 빈도가 증가하고 있으나 합병증에 대한 문헌적 고찰은 적은 현실이다. 이에 측면 척추체간 유합술 후 발생한 척추체 골절에 대하여 보고하고자 한다.

목적: 골다공증이 없는 환자에서 측면 척추체간 유합술 시행 후 저명한 외상 없이 발생한 척추체 골절 두 예 보고 및 이와 관련된 합병증을 고찰 하고자 한다.

선행문헌의 요약: 측면 척추체간 유합술 시행 후 발생한 합병증에 대한 보고가 적은 현실이다.

대상 및 방법: 첫 번째 환자는 두 레벨 측면 척추체간 유합술 및 후방 고정술을 받은 비만의 여성으로 수술 후 척추체 두 레벨에서 골절 소견이 발생하였다. 두 번째 고령의 남성은 후방 고정술 없이 세 레벨의 측면 척추체간 유합술 시행 후 한 레벨의 척추체 골절 소견이 발생하여 보고하고자 한다.

결과: 첫 번째 환자는 비수술적 치료로 잘 치유되었다. 그러나, 두 번째 환자는 후방 고정술을 추가적으로 시행 후 치유 되었다. 이러한 골절 유발 요인은 골다공증 이외에 다른 요인이 있을 수 있으며 이에 대하여 고찰 하여 보았다.

결론: 측면 척추체간 유합술은 여러 척추 질환에서 효과적인 수술법으로 보고 되고 있다. 그러나, 골다공증이 없는 환자에서도 측면 척추체간 유합술 후 척추체 골절이 발생할 수 있다. 수술 중 척추관 골절, 침강, 케이지 구름과 적절하지 못한 후방 고정물 등의 원인에 의하여 척추체 골절이 유발 될 수 있다.

색인 단어: 측면 척추체간 유합술, 관상면 척추체 골절, 합병증

약칭 제목: 측면 척추체간 유합술 후 발생한 척추체 골절

접수일: 2017년 10월 31일

수정일: 2017년 11월 7일

게재확정일: 2018년 2월 13일

교신저자: 이기수

대전광역시 중구 문화로 282 충남대학교병원 정형외과학교실

TEL: 042-338-2438

FAX: 042-545-2373

E-mail: gs1899@hanmail.net