

# Nodular Fasciitis as a Pseudosarcomatous Lesion in the Ligamentum Nuchae - A Case Report -

Seung Hwan Kim, M.D.<sup>\*</sup>, Jung Soo Kim, M.D.<sup>\*</sup>, Ph.D., Kyung Han Nam, M.D.<sup>†</sup>

*Department of Neurosurgery,<sup>\*</sup>*

*Department of Pathology,<sup>†</sup> Haeundae Paik Hospital, Inje University College of Medicine, Busan, Korea*

**Study Design:** A case report.

**Objectives:** Nodular fasciitis is a non-neoplastic soft-tissue lesion located in the deep subcutaneous region; it may be misdiagnosed as a malignant tumor due to its rapid growth and microscopic characteristics. We introduce an unusual case of nodular fasciitis which presented as a posterior neck mass.

**Summary of Literature Review:** Nodular fasciitis is an unusual benign lesion. Because it sometimes shows aggressive microscopic characteristics, (being hypercellular and polymorphic), the condition has the potential to be misdiagnosed as sarcoma.

**Materials and Methods:** A 20-year-old woman presented with a 1-month history of a progressively enlarging mass on her posterior neck. Computed tomography (CT) scans of the neck showed a markedly enhanced, well-defined, ovoid soft tissue mass at the posterior of the spinous process of C2. The patient underwent marginal excision. There was a 2 cm, well-capsulated, pinkish-gray mass.

**Results:** She recovered without any complications. Histopathologic examination showed a spindle cell proliferation, increased cellularity, and nuclear atypia with mitosis. The immunohistochemistry stain showed negative findings. The mass was diagnosed as nodular fasciitis.

**Conclusions:** A diagnosis of nodular fasciitis, not just malignant tumor, should be considered for a rapidly growing posterior neck mass showing aggressive microscopic appearance. Nodular fasciitis is a self-limiting lesion readily treated by marginal excision. However, follow-ups should be increased to watch for recurrence.

**Key Words:** Nodular fasciitis, Neck, Tumor

## Introduction

Nodular fasciitis is a non-neoplastic proliferative soft-tissue lesion that frequently arises in the deep subcutaneous region or in the fascia of the upper extremities, the head and neck, the lower extremities, and trunk<sup>1,2)</sup>. It is infrequently misdiagnosed as a malignant tumor, especially as a sarcomatous lesion because it grows very rapidly without evidence of associated infection. Furthermore it shows histologic findings similar to those seen in malignant tumors, such as high cellularity, increased mitotic activity, and an infiltrative growth pattern. Despite its malignant microscopic appearance, nodular fasciitis is a self-limiting lesion that is cured following marginal excision.

The purpose of this report is to present nodular fasciitis as a pseudosarcomatous lesion occurring in the ligamentum nuchae.

## Case report

A 20-year-old woman presented with a 1-month history of a progressively enlarging, tender mass on her posterior neck. She underwent fine-needle aspiration under ultrasonography at a local hospital. The pathologic diagnosis was spindle cell neoplasm. Then, she was transferred to our hospital. Neck computed tomography (CT) images showed a markedly

**Received:** February 23, 2015

**Revised:** May 6, 2015

**Accepted:** August 12, 2015

**Published Online:** September 30, 2015

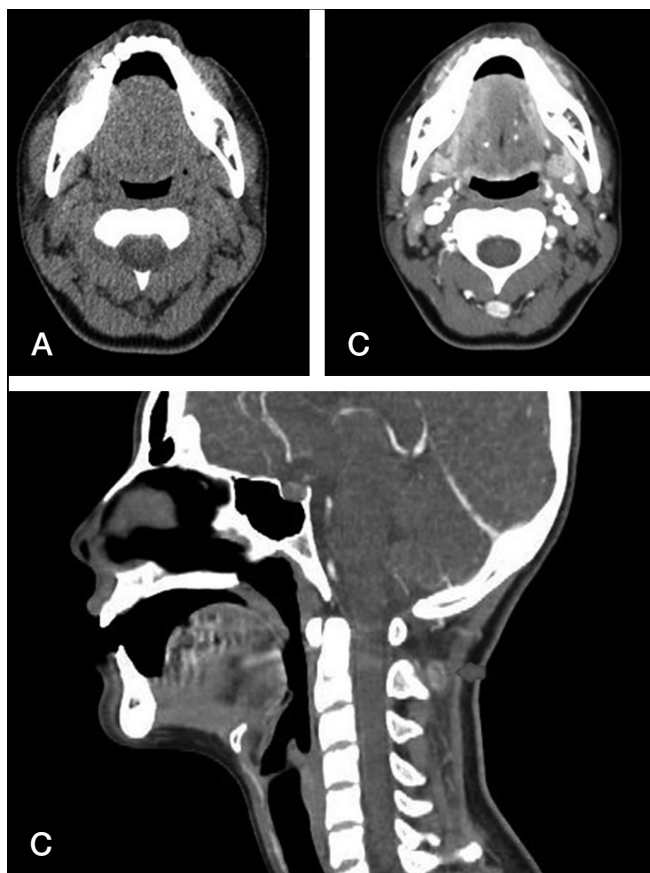**Corresponding author:** Jung Soo Kim, M.D., Ph.D.

Department of Neurosurgery, Haeundae Paik Hospital, Inje University College of Medicine, 875 Haeun-daero, Haeundae-gu, Busan 612-862, Korea

**TEL:** +82-51-797-0628, **FAX:** +82-51-787-0841

**E-mail:** jheaj@paik.ac.kr

enhancing, well-defined, ovoid soft tissue mass posterior to the spinous process of C2 (Fig. 1 A-C). She had no evidence of



**Fig 1.** (A) A CT scan of the soft tissue tomography reveals a 1.2 cm sized oval shaped well-defined mass. (B) A CT scan of the soft tissue tomography with enhancement reveals a strongly enhancing soft tissue mass between the superficial and deep muscle layers of the posterior neck. (C) A CT scan of the soft tissue tomography with sagittal reconstruction shows that the mass is located posterior to the spinous process of C2.

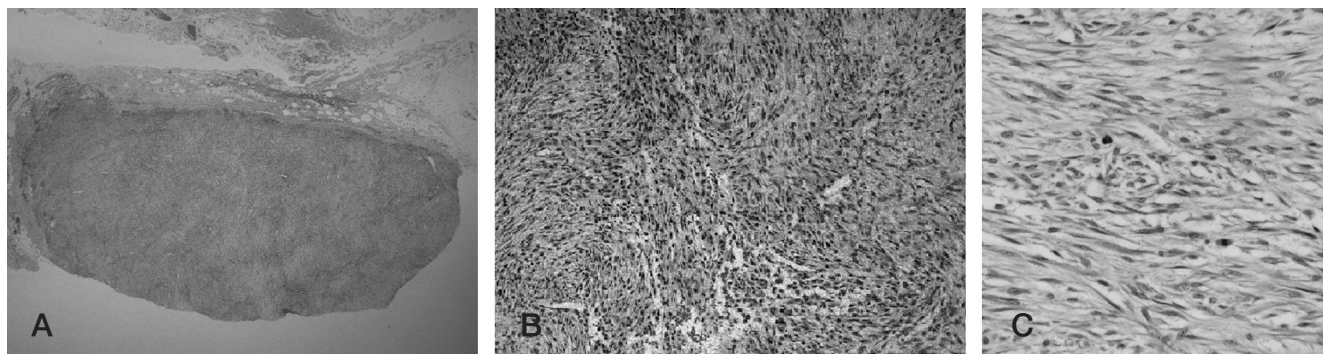
inflammation or any trauma history. She underwent marginal excision. Excised mass was 2 cm-size, non-capsulated and pinkish gray mass (Fig. 2 A).

Histologically, the lesion was composed of interlacing fascicles of plump spindle-shaped fibroblasts/myofibroblasts lacking nuclear pleomorphism. It included prominent vasculatures and intralésional extravasated erythrocytes, and mixed chronic inflammatory cells (Fig. 2 B). The myxoid area, hyalinization, giant cells and bone formation were not seen. Mitoses were present in 6/10 high power fields, but no atypical forms were identified (Fig. 2 C). Immunohistochemical study showed diffuse positive cytoplasmic staining for smooth muscle actin (SMA) that was negative for desmin, S-100, CD34 and C-kit. We finally diagnosed as nodular fasciitis because the lesion occurred along the fascia of the neck muscle and was typically small, approximately 2-3 cm in size.

She recovered without any complications and there has been no evidence of recurrence for 6 months.

## Discussion

Nodular fasciitis is a benign soft tissue lesion composed of fibroblast proliferation.<sup>1)</sup> The lesion is usually a non-encapsulated oval shaped mass and is yellowish-brown to grayish-white in color. It is the most common benign lesion that is misdiagnosed as sarcoma on fine-needle aspiration cytology (FNAC).<sup>3)</sup> Overall, 21-30% of nodular fasciitis cases are misdiagnosed as sarcoma, and 36% of cases are misdiagnosed as other benign lesions.<sup>4-6)</sup> The reason for this is that it grows rapidly without signs of infection or trauma, and histologically it has abundant



**Fig 2.** (A) A longitudinal section of nodular fasciitis (x1.25 magnification). (B) Histopathologic findings under the hematoxylin-eosin stain. The lesion is composed of interlacing fascicles of plump spindle-shaped fibroblasts/myofibroblasts lacking nuclear pleomorphism. The prominent vasculatures, and intralésional extravasated erythrocytes, and mixed chronic inflammatory cells were seen (H&E, x200). (C) Mitoses were present in 6/10 high power fields but no atypical forms were identified (H&E, x400).

**Table 1.** Pathologic Differences Between Nodular Fasciitis and Malignant Sarcomas

Sarcomas (General)	Nodular Fasciitis
Usually over 4 cm	Almost always less than 5 cm
Frequent nuclear pleomorphism	No pleomorphism
pronounced mitotic rate including atypical mitotic figures	Mitotic figures may be plentiful but not atypical forms
Coarse, granular, irregular chromatin	Fine, pale, even chromatin

spindle-shaped cells, increased mitotic activity, and infiltrative borders. Nodular fasciitis is known to be the pseudosarcomatous lesion.

The pathogenesis of nodular fasciitis is still unknown. However, reactive or inflammatory processes have been proposed.<sup>7,8)</sup> Past trauma history has been suggested as a provoking factor, although most cases of nodular fasciitis have been reported to be associated without trauma.<sup>1,9,10)</sup>

Nodular fasciitis is common in young adults between 20 and 40 years of age and occurs equally often in men and women. However, any age group can be affected.<sup>1,7)</sup> It can be found anywhere in the body. Half of these cases involve the upper extremity and approximately 15–20% involve the head and neck.<sup>10)</sup>

The most common clinical presentation of nodular fasciitis is often a solitary, rapidly growing mass that is frequently associated with pain and tenderness within a few weeks. However, slower or no growth with a diameter of 1–3 cm has been reported that in the majority of cases.<sup>1)</sup>

Ultrasonography shows that nodular fasciitis consists of well-defined and solid, hypoechoic, or mixed echoic masses with indistinct posterior margins and distal acoustic shadowing.<sup>7)</sup> On CT and MRI, nodular fasciitis is a well defined, homogeneous soft tissue mass with moderate to strong enhancement.<sup>7)</sup> In most cases, it presents as subcutaneous nodule. Deeper located lesions, which belong to the intramuscular type, are larger and have poorly defined margins. These can invade the adjacent structures including the bone and are likely to suggest a soft tissue malignancy.<sup>1,11)</sup>

Regardless of its aggressive microscopic feature, nodular fasciitis is a self-limiting lesion that is readily treated by marginal excision. Recurrence of nodular fasciitis is rare, if the initial diagnosis is accurate. Recurrent lesions frequently reveal a malignant tumor. Spontaneous regression of nodular fasciitis has occasionally been observed.<sup>12)</sup> Wong et al. reported spontaneous

resolution of nodular fasciitis that occurred in 41 of the 46 cases within 1 to 16 weeks (median, 2 weeks) after FNAC.<sup>13)</sup>

In our case, the result of FNAC at local hospital showed spindle cell neoplasm. We had to suspect both benign and malignant tumor. Because mass was located superficially, small size and well defined, we expected that it could be resectable. We planned to do primary excisional biopsy for diagnostic and treatment purpose rather than to do repeated FNAC or incisional biopsy.

The different pathologic features of nodular fasciitis compared with those of malignant sarcomas are small size (usually less than 5 cm), no pleomorphism, plentiful mitotic figures without atypical forms, and even chromatin (Table 1).<sup>14)</sup>

Although there are no pathognomonic imaging findings, nodular fasciitis should be included in the differential diagnosis of soft tissue masses in the head and neck, especially in patients with a recently developed, rapidly growing mass and a history of recent trauma.

We report a case of nodular fasciitis on the posterior neck. Though nodular fasciitis usually shows aggressive characteristics in microscopic appearance, it is a self-limiting lesion that is readily treated by marginal excision. Nodular fasciitis should be included in the differential diagnosis of soft tissue masses in the head and neck, especially in patients with a recently developed, growing mass. Further follow-up is required for this case to determine recurrence.

## REFERENCES

1. Shin J, Lee H, Cho K-J, et al. Nodular fasciitis of the head and neck: radiographic findings. *Clin Imaging*. 2003;27:31–7.
2. Harrison HC, Motbey J, Kan AE, de Silva M. Nodular fasciitis of the nose in a child. *Int J Pediatr Otorhinolaryngol*. 1995;33:257–64.

3. Powers CN, Berardo MD, Frable WJ. Fine-needle aspiration biopsy: pitfalls in the diagnosis of spindle-cell lesions. *Diagn Cytopathol.* 1994;10:232-40.
4. Montgomery EA, Meis JM. Nodular fasciitis. Its morphologic spectrum and immunohistochemical profile. *Am J Surg Pathol.* 1991;15:942-8.
5. Chung EB, Enzinger FM. Proliferative fasciitis. *Cancer.* 1975;36:1450-8.
6. Plaza J, Mayerson J, Wakely P. Nodular fasciitis of the hand: a potential diagnostic pitfall in fine-needle aspiration cytopathology. *Am J Clin Pathol.* 2005;123:388-93.
7. Koenigsberg RA, Faro S, Chen X, Marlowe F. Nodular fasciitis as a vascular neck mass. *AJNR, Am J Neuroradiol.* 1996;17:567-9.
8. Oshiro Y, Fukuda T, Tsuneyoshi M. Fibrosarcoma versus fibromatoses and cellular nodular fasciitis. A comparative study of their proliferative activity using proliferating cell nuclear antigen, DNA flow cytometry, and p53. *Am J Surg Pathol.* 1994;18:712-9.
9. Kim S, Kim H-J, Park S-W, et al. Nodular fasciitis in the head and neck: CT and MR imaging findings. *AJNR, Am J Neuroradiol.* 2005;26:2617-23.
10. Dahl I, Jarlstedt J. Nodular fasciitis in the head and neck. A clinicopathological study of 18 cases. *Acta otolaryngol.* 1980;90:152-9.
11. Batsakis JG, el Naggat AK. Pseudosarcomatous proliferative lesions of soft tissues. The Annals of otology, rhinology & laryngology. *Ann Otol Rhinol Laryngol.* 1994;103:578-82.
12. DiNardo LJ, Wetmore RF, Potsic WP. Nodular fasciitis of the head and neck in children. A deceptive lesion. *Arch Otolaryngol Head Neck Surg.* 1991;117:1001-2.
13. Wong N, Di F. Pseudosarcomatous fasciitis and myositis: diagnosis by fine-needle aspiration cytology. *Am J Clin Pathol.* 2009;132:857-65.
14. Jo V, Fletcher CDM. WHO classification of soft tissue tumours: an update based on the 2013 (4th) edition. *Pathology.* 2014;46:95-104.

### 육종과 감별이 필요한 후경부의 결절성 근막염 - 증례 보고-

김승환\* · 김정수\* · 남경한†

인제대학교 해운대백병원 신경외과학교실\*, 인제대학교 해운대백병원 병리학교실†

**연구계획:** 증례보고

**목적:** 결절성 근막염은 피하조직에 발생하는 비종양성 연부조직 질환으로 조직학적 특성과 빠른성장속도 때문에 육종으로 오진되는 경우가 있다. 육종과 감별해야 했던 후경부에서 발생한 결절성 근막염의 증례를 보고하고자 한다.

**선행문헌의 요약:** 결절성 근막염은 양성 병변이지만 병리소견에서 악성의 특성을 보이기도 하기때문에 육종으로 오진될 가능성이 있다.

**대상 및 방법:** 20세 여자가 1개월 전부터 커진 후경부 종양으로 내원했다. 목경추부 전산화단층촬영(CT)에서는 2번 경추 가시돌기 후방으로 조영증강 잘되며 경계가 명확한 타원형의 연부조직종양으로 경계부위 절제술을 시행하였다.

**결과:** 조직병리 검사에서 방추세포증식이 관찰되었고 유사분열과 동반된 비정형 핵 및 세포의 증가가 보였으나 면역조직화학검사에서는 특이사항이 없었다. 이 병변은 최종적으로 결절성 근막염으로 진단되었다. 수술 후 환자는 합병증 없이 회복되었으며 현재까지 재발의 증거도 없다.

**결론:** 본 증례와 같이 머리와 목 부위에서 발생하여 빠르게 성장하는 연부조직종양으로 조직학적으로 악성 종양의 특성을 보일 경우에는 악성 연부조직 종양 뿐만 아니라 결절성 근막염도 고려해야 한다. 결절성 근막염은 경계부위 절제술 후 자기한정성으로 치료되는 양성 질환이나 재발에 대한 추적 이 필요하다.

**색인 단어:** 결절성 근막염, 목, 종양

**약칭 제목:** 결절성 근막염