

Intraoperative Spinal Nerve Root Injuries during Surgery for Degenerative Low Back Disease

Byung-Joon Shin, M.D., Jae Chul Lee, M.D., Ki-Hoon Ryu, M.D.,
Ho-Won Jung, M.D., Kyung-Je Kim, M.D., and Yon-Il Kim, M.D.

Department of Orthopaedic Surgery, Soonchunhyang University College of Medicine, Bucheon, Korea

– Abstract –

Study Design : A retrospective study

Objective : To analyze incidence, causes and prognosis of the spinal nerve root injury during the degenerative low back surgery.

Summary of Literature Review : There were very few studies about intraoperative spinal nerve root injuries during low back surgery.

Materials and Methods : Six hundred and twenty seven patients underwent degenerative low back surgery from Jan 1990 to Jan 2001 were included in this study. All patients were operated on by the first author and operation records made by the author himself were reviewed. Eight cases of intraoperative spinal nerve root injury were identified and causes and level of injuries, preoperative diagnosis, types of surgery and follow-up clinical results were analyzed.

Results : Eight cases of nerve root injury were developed during 5 posterior laminotomies for discectomy and 3 instrumentation and fusion. Spinal nerve root injuries were caused by Kerrison punch in 4 cases, pituitary forcep in 2, rongeur in 1, and not certain but probably by Kerrison punch in 1 case. The levels of injuries were 5th lumbar nerve root in 4 cases, and 1st sacral nerve root and 2nd lumbar nerve root in 1 case respectively. Two cases had sacral nerve rootlet injury with paramedian dural tear but the level of root injury was uncertain. Six of 8 patients had symptoms. There were sensory loss in 4 patients, pain in 2, and one patient had both sensory loss and loss of big toe extension power. Neurological symptoms were not improved throughout the follow-up period, but 2 patients who had pain were resolved their symptoms by 3 months.

Conclusions : Incidental spinal nerve root injury occurred in 1.3 percentage of the patients who underwent low back surgery. Half of them had neurologic symptoms and they showed poor prognosis. However motor deficit was relatively uncommon and it might be related to the anatomical characteristics of spinal nerve root.

Key Words : Intraoperative spinal nerve root injury, Lumbar, Degenerative

Address reprint requests to

Byung-Joon Shin, M.D.

Department of Orthopaedic Surgery, Soonchunhyang University College of Medicine

#1174 Bucheon Korea

Tel : 82-32-621-5259, Fax : 82-32-324-9577, E-mail : schsbj@schbc.ac.kr

*

2002

1 . 4
 , 1 .

Mayfield⁷⁾ 5 (1.5%),
 3 (1.0%) .

2% .

가

,
 , , ,
 9) .

가 8
 (Table 1).

Kerrison punch

4 , pituitary forcep

2 , rongeur

1 , Kerrison punch

1 가 Kerrison punch 가

가

5
 2
 4 가 , 1
 1 , 2

(Fig. 1).

26.8

6

가 4 ,

가 2 , 1

가

1990 1 2001 1 1

, ,

,

2 3
 (Table 1).

627

1
 protocol

329 ,

298

627

2% , , 7) .

가 , 8

9) . Bertrand¹⁾

가

(battered root)’

가 .

1.3%

8
 4 , 3 ,

Table 1. Patients profiles

성별	연령	진단	수술방법	원인	손상부위	신경증상	추시(개월)
F	66	HIID	laminotomy	pituitary로 dural tear와 root injury(fascicle 하나가 벌려 나옴)	sacral rootlet (right paramedian)	no	12
F	48	HIID	laminotomy	kerrison으로 root 를 한번 째듯 root injury 확실치 않음.	S1 root, left	S1 sensory 감소	74
M	29	HIID with osteochondral fracture	laminotomy	root 일부 제거됨 disc인 줄 알고 pituitary로 떼어내다 손상됨.	L5 root, right	no	31
M	35	HIID	laminotomy	ligamentum flavum을 작은 rongeur로 뜯다가 dural tear 되며 root 일부 잘려 나옴.	sacral rootlet (left paramedian)	left posterior thigh의 감각 이상 이 나타났다 3개월에 사라짐	24
M	29	stenosis	laminotomy	무엇에 의해 손상되었는지 모름 (kerrison 추정)	L5 root, left	L5 sensory 감소	12
F	51	stenosis	decompression and fusion	kerrison에 의해 fascicle 끊어짐	L5 root, left	심하게 감소. no pain EPH 0, L5 sensory	26
F	54	stenosis	decompression and fusion	kerrison에 의해 fascicle 끊어짐	L2 root, left	L2 sensory 감소	23
F	56	degenerative spondylolisthesis	decompression and fusion	kerrison에 의해 fascicle 몇 개 끊어짐.	L5 root, right	buttock pain이 있었으나 술 후 3m에 사라짐.	12

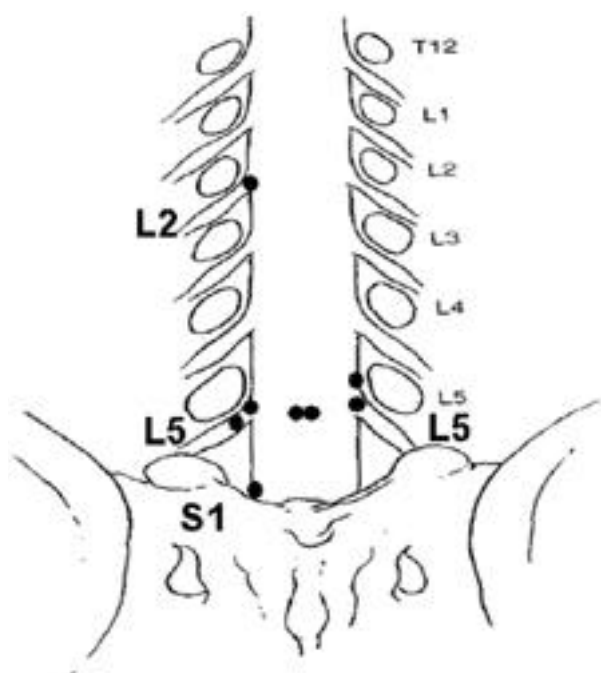


Figure 1. Distribution of nerve root injuries.

Tew Mayfield¹³⁾가
0.4%

가

. Mayfield 1408

2
Kerrison punch

Kerrison punch

가 , 가 . Kerrison

, Penfield

, Matsui ⁶⁾

가

osteotome

osteotome

osteotome

가

Sunderland¹¹⁾

(epineurium)

(perineurium)

REFERENCES

- 1) **Bertrand G** : *The battered root problem. Orthop Clin North Am*, 6:305-310, 1975.
- 2) **Cohen MS, Wall EJ, Olmerker K, Rydevik BL and Garfin SR** : *Anatomy of the spinal nerve roots in the lumbar and lower thoracic spine.*(in Rothman RH and Simeone FA eds. *The spine*, 4th ed., Philadelphia, WB Saunders Co: 83, 1999.)
- 3) **Cohen MS, Wall EJ, Brown RA et al** : *Cauda equina anatomy: extrathecal nerve roots and dorsal root ganglia. Spine* 15:1248-1251, 1990.
- 4) **Gordon RB** : *Complications of lumbar spine surgery.*(in Wiessel SW eds. *The lumbar spine*, 2nd ed, Philadelphia, WB Saunders Co: 1724, 1996.)
- 5) **Jonsson B and Stromqvist B** : *Lumbar spine surgery in the elderly: Complications and surgical results. Spine* 19: 1431-1435, 1994.
- 6) **Matsui H, Kitagawa H, Kawaguchi T and Tsuji H** : *Physiologic changes of nerve root during posterior lumbar discectomy. Spine*, 20:654-659, 1995.
- 7) **Mayfield F** : *Complications of laminectomy. Clin Neurosurg*, 23:435-439, 1975.
- 8) **Shin BJ, Shin YS, Kim YI, Rah SK and Choi CU** : *Conjoined nerve roots associated with congenital absence of lumbosacral articular facet: A case report. J Korean Spine Surg*, 2:290-295, 1995.
- 9) **Stambough JL and Simeone FA** : *Neurogenic complications in spinal surgery.*(in Rothman RH and Simeone FA eds. *The spine*, 4th ed., Philadelphia, WB Saunders Co: 1724, 1999.)
- 10) **Stambough JL and Booth RE** : *Complication in spine surgery as a consequence of anatomic variations.*(in Garfin SR eds. *Complications of spine Surgery*. Baltimore, Williams & Wilkins, 1989.)
- 11) **Sunderland S** : *Advances in diagnosis and treatment of root and peripheral nerve injury. Adv Neurol*, 22:271-305, 1979.
- 12) **Sussman BJ** : *Surgical injury of the cord and its roots. Paraplegia*, 17:298-310, 1978.
- 13) **Tew JM Mayfield FH** : *Surgery of the anterior cervical spine: Prevention of complications.*(in Dunsker SB eds. *Seminars in neurological surgery: Cervical spondylosis*. New York, Raven Press, 1980.)



가 .

:

: 1990 1 2001 1 1 , ,

, . 1 protocol 329 , 298

627 가 , 8 . (26.8)

:

5 (1.5%), 3 (1.0%) .

Kerrison punch 4 가 , pituitary forcep 1

2 , rongeur , Kerrison punch 1 2

5 4 , 1 2 1 , 2

가

6 가 4 , 가 2 , 1

가

2 3 .

: 1.3%

, 가 .

: