



# Ectopic Mediastinal Parathyroid Adenoma in a Patient with Chronic Kidney Disease: A Case Report

만성 신장질환 환자에서 흉선 내에서 발견된 이소성 부갑상선 선종: 증례 보고

Dong Min Choo, MD , Jin Hwan Kim, MD\* , Song Soo Kim, MD

Department of Radiology, Chungnam National University Hospital, Chungnam National University School of Medicine, Daejeon, Korea

We report an ectopic mediastinal parathyroid adenoma in a patient with chronic kidney disease who presented with refractory hypercalcemia. Technetium-99m-sestamibi scintigraphy is a valuable imaging technique for the detection of an ectopic parathyroid adenoma in the mediastinum. The combination of intense contrast enhancement and the identification of a polar vessel on a computed tomography scan will ensure that a radiologist can differentiate a parathyroid adenoma from other pathologies in the mediastinum. By virtue of the advancement of imaging modalities, localization of an ectopic mediastinal parathyroid adenoma prior to surgery is possible and unnecessary neck exploration is avoidable.

**Index terms** Parathyroid Neoplasms; Mediastinal Neoplasms; Hyperparathyroidism

## INTRODUCTION

Herein, we report a case of ectopic mediastinal parathyroid adenoma presented with hyperparathyroidism (HPT) and hypercalcemia refractory to volume expansion and diuretics in a patient with chronic kidney disease (CKD). The authors emphasize the role of radiologists and various imaging modalities in the localization and the differential diagnosis of ectopic mediastinal parathyroid adenoma. Surgery is the treatment of choice and the accurate diagnosis and localization of an ectopic parathyroid adenoma is important to plan appropriate treatment (1).

Received April 10, 2018

Revised May 23, 2018

Accepted June 17, 2018

\*Corresponding author

Jin Hwan Kim, MD  
Department of Radiology,  
Chungnam National University  
Hospital, Chungnam National  
University School of Medicine,  
282 Munhwa-ro, Jung-gu,  
Daejeon 35015, Korea.

Tel 82-42-280-7333

Fax 82-42-253-0061

E-mail michelan@cnu.ac.kr

This is an Open Access article distributed under the terms of the Creative Commons Attribution Non-Commercial License (<https://creativecommons.org/licenses/by-nc/4.0>) which permits unrestricted non-commercial use, distribution, and reproduction in any medium, provided the original work is properly cited.

## ORCID iDs

Jin Hwan Kim

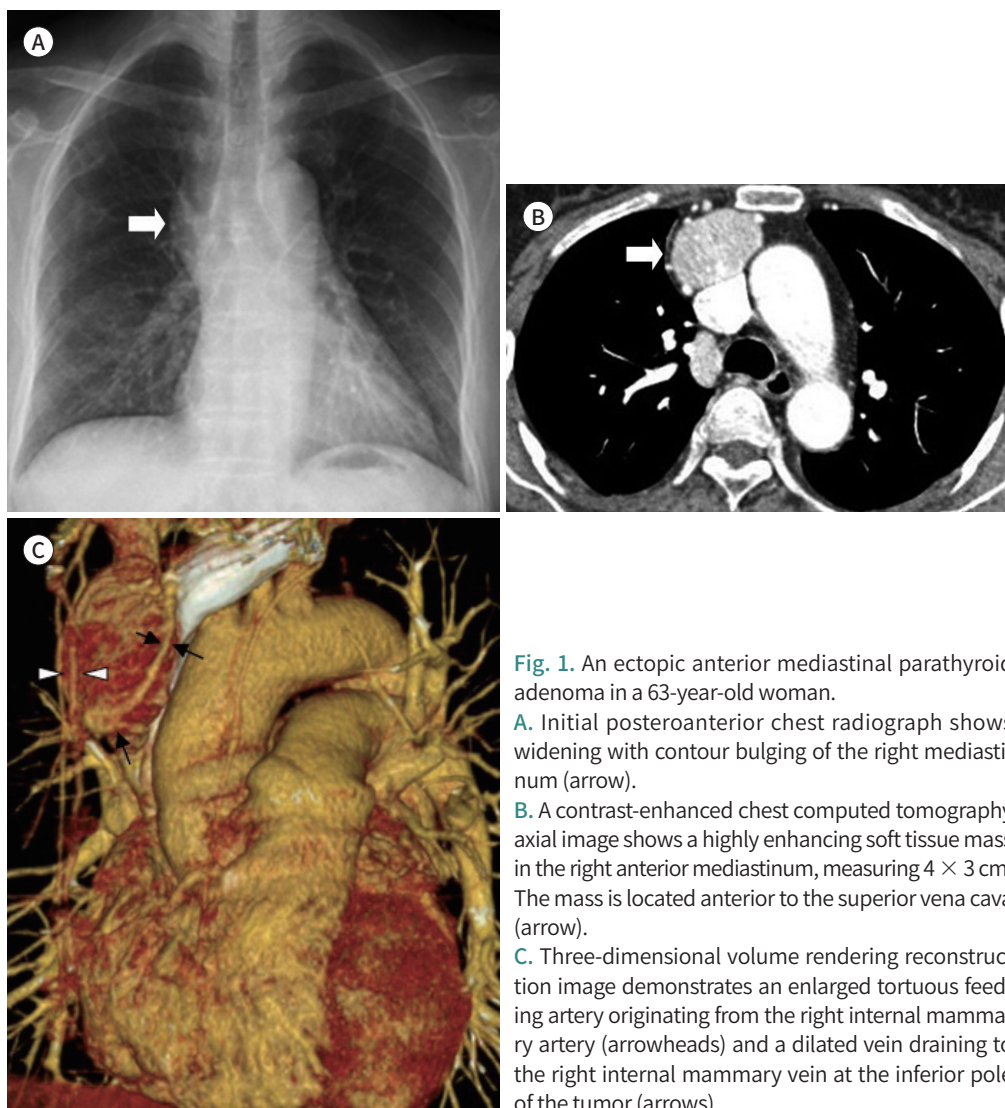
<https://orcid.org/0000-0002-1632-2421>

Dong Min Choo

<https://orcid.org/0000-0002-2731-358X>

## CASE REPORT

A 63-year-old woman with a past medical history of CKD presented to our hospital with worsening nausea, vomiting, and dizziness for a week. On admission, her serum chemistries showed elevated serum creatinine of 1.51 mg/dL (normal range: 0.6–0.9 mg/dL), urea nitrogen of 27 mg/dL (normal range: 8–20 mg/dL), and an estimated glomerular filtration rate of 37.9 mL/min/1.73 m<sup>2</sup> (stage 3 CKD). The patient's serum calcium was 14.6 mg/dL (normal range: 8.7–10.6 mg/dL), and serum phosphate was 1.91 mg/dL (normal range: 2.5–4.7 mg/dL). Physical examinations were normal. Based on her presenting symptoms and serum chemistries, she was initially considered as having acute-on-chronic renal insufficiency. For symptomatic treatment of hypercalcemia, hydration, and diuretics were applied at the emergency department. However, elevation of the serum calcium level of the patient persisted. To evaluate the cause of hypercalcemia, serum parathyroid hormone (PTH) was checked and revealed a strikingly elevated level of 3010 pg/mL (normal range: 10–65 pg/mL).

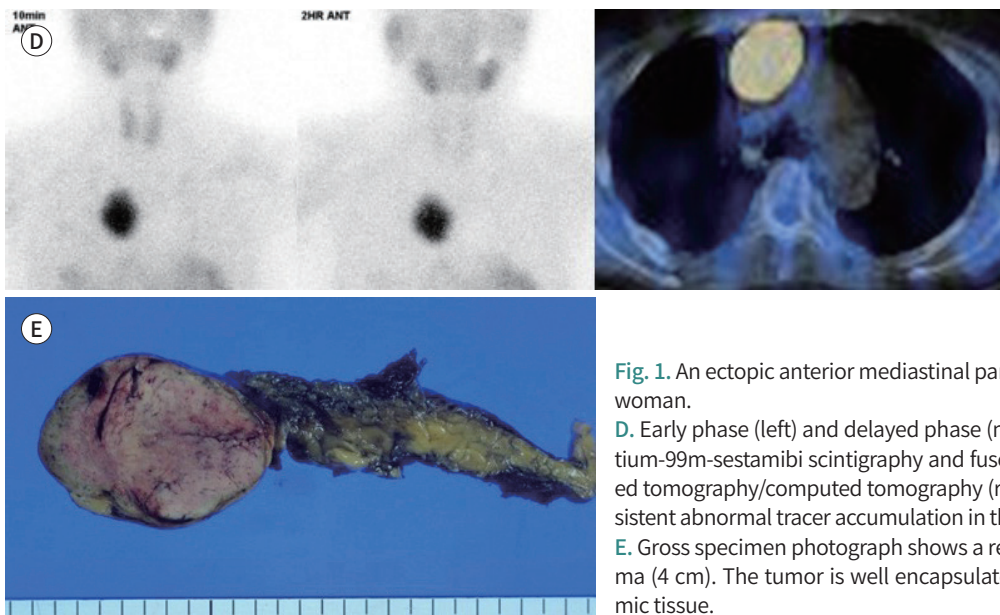


**Fig. 1.** An ectopic anterior mediastinal parathyroid adenoma in a 63-year-old woman.

**A.** Initial posteroanterior chest radiograph shows widening with contour bulging of the right mediastinum (arrow).

**B.** A contrast-enhanced chest computed tomography axial image shows a highly enhancing soft tissue mass in the right anterior mediastinum, measuring 4 × 3 cm. The mass is located anterior to the superior vena cava (arrow).

**C.** Three-dimensional volume rendering reconstruction image demonstrates an enlarged tortuous feeding artery originating from the right internal mammary artery (arrowheads) and a dilated vein draining to the right internal mammary vein at the inferior pole of the tumor (arrows).



**Fig. 1.** An ectopic anterior mediastinal parathyroid adenoma in a 63-year-old woman.

**D.** Early phase (left) and delayed phase (middle) coronal dual-phase Technetium-99m-sestamibi scintigraphy and fused single photon emission computed tomography/computed tomography (right) images depict a focal and persistent abnormal tracer accumulation in the right anterior mediastinal mass.

**E.** Gross specimen photograph shows a resected ectopic parathyroid adenoma (4 cm). The tumor is well encapsulated and firmly adhered to fatty thymic tissue.

At the time of admission, the patient's chest radiograph showed widening with contour bulging of the right mediastinum (Fig. 1A). A week later, a chest computed tomography (CT) scan was performed which showed a well-defined soft tissue mass in the right mediastinum, measuring  $4 \times 3$  cm. The mass was located anterior to the superior vena cava and ascending aorta (Fig. 1B). The tumor was isodense with chest wall muscles (30 HU) on non-contrast CT images, and homogeneous and intense enhancement (160 HU) was revealed after intravenous administration of an iodinated contrast material. An enlarged tortuous feeding artery originating from the right internal mammary artery, and a dilated vein draining to the right internal mammary vein were noted on the periphery of the tumor (Fig. 1C). Dual-phase Technetium-99m ( $^{99m}\text{Tc}$ )-sestamibi with single photon emission computed tomography (SPECT)/CT revealed a localized and persistent abnormal tracer uptake in the anterior mediastinum, indicating an ectopic PTH-releasing tumor (Fig. 1D). A thyroid ultrasonography (US) showed a normal thyroid gland, and  $^{99m}\text{Tc}$ -sestamibi scintigraphy revealed no abnormal tracer uptake in the neck of the patient.

Video-assisted thoracoscopic surgery was performed, and a well-encapsulated mass and thymic tissue were removed (Fig. 1E). Histopathologic review of the mass confirmed a benign parathyroid adenoma (PTA).

The day after surgery, the patient's serum calcium dropped to 9.4 mg/dL with serum PTH 37.63 pg/mL. Over the next two years, the patient maintained normal serum calcium (9.3 mg/dL), phosphate (3.0 mg/dL) and PTH (19.81 pg/mL) levels, and the status of her CKD remained stable.

## DISCUSSION

Severe hypercalcemia affects diverse organs causing various symptoms in patients with CKD; mineral and bone disorder has a strong relationship with both all-cause and cardiovas-

cular-related mortality (2).

The pathogenesis of HPT in CKD is complicated and not entirely understood at present. In a patient with CKD, impaired renal function leads to a decreased synthesis of active vitamin D (1, 25-dihydroxy vitamin D, calcitriol) and a decline in intestinal absorption of calcium. Moreover, advanced CKD results in hyperphosphatemia, and the elevated serum phosphorus binds with calcium as  $\text{CaHPO}_4$  causing hypocalcemia. Finally, the hypocalcemia directly stimulates both PTH synthesis and secretion, which is called secondary HPT. Tertiary HPT is a state of excessive autonomous secretion of PTH after long-standing renal insufficiency and secondary HPT. The chronic stimulation of parathyroid secretion in CKD causes parathyroid gland hyperplasia, and this commonly evolves into a parathyroid tumor. Up to 20% of tertiary HPT patients may have single or multiple PTAs (3).

Approximately 90% of primary HPT is caused by a single PTA. Multiple PTAs, parathyroid gland hyperplasia, parathyroid carcinoma, multiple endocrine neoplasia, and genetic mutations can also be causes of primary HPT. In primary HPT, adenoma size is an important determinant of disease severity (4).

In our patient, the markedly elevated serum PTH concentration (3010 pg/mL) was more typical of secondary or tertiary HPT rather than primary HPT. The high serum PTH concentration and the large size of the adenoma in this case were suggestive of tertiary HPT, or this was possibly an atypical case of primary HPT.

Incidence of ectopic parathyroid glands is reported in 28% to 42% of autopsies, and in 6% to 16% of surgical cases of primary HPT (5). The locations of ectopic parathyroid glands vary according to their embryologic development. Mediastinal PTA was first reported by Churchill in 1932, and the prevalence of mediastinal PTA has been reported to be 5–30% (5). There are typically four parathyroid glands located posterior to the thyroid gland, comprising a superior and an inferior parathyroid gland on either lobe. During the developmental phase, superior glands develop from the fourth pharyngeal pouch, and from this, the thyroid gland originates. This explains why superior parathyroid glands may occasionally be discovered within the thyroid gland. On the other hand, from the third pharyngeal pouch, inferior glands and the thymus develop and advance together (6). Because of this embryologic association, inferior glands can be found neighbouring the thymus or in an intrathymic location.

In the past, it was difficult to diagnose mediastinal PTA before surgical exploration. However, with the advance in imaging modalities, pre-operative localization of an ectopic mediastinal PTA has become possible, and unnecessary invasive surgical neck exploration is avoidable. Roy et al. (7) reported that  $^{99\text{m}}\text{Tc}$ -scintigraphy is the most valuable imaging technique for the detection of an ectopic PTA in the mediastinum including the thymus, and US is the most appropriate imaging tool for the evaluation of intrathyroidal PTAs. A combination of functional information from SPECT and precise anatomic information from CT, SPECT/CT, is known to be superior to conventional scintigraphy in the localization of ectopic mediastinal PTAs (1).

Hypersecreting parathyroid adenomas are mostly hypervascular tumors and show high contrast enhancement on a contrast enhanced CT scan. A prominent feeding artery at the margin of a PTA (polar vessel) was first revealed by angiography and US (8). The enlarged vessels are usually normal vessels, and PTA is parasitic. Four-dimensional CT (4D-CT) for

parathyroid imaging was introduced by Rodgers et al. (9), and Bahl et al. (10) reported that a polar vessel is identified in up to two-thirds of surgically confirmed PTAs on 4D-CT scans. The combination of intense contrast enhancement and the identification of a polar vessel on a CT scan will ensure that a radiologist can differentiate a PTA from other mediastinal pathologies. Surgery is the only curative management for a PTA (5). With the developments in imaging modalities, the precise localization of an ectopic mediastinal PTA before surgery can be achieved with high sensitivity and specificity. This helps to avoid futile invasive surgical exploration and complications.

In conclusion, radiologists should have an understanding of distinctive imaging findings regarding ectopic PTA and can play a key role in the diagnosis and precise localization of the tumor for better surgical management.

### Conflicts of Interest

The authors have no potential conflicts of interest to disclose.

### REFERENCES

1. Eslamy HK, Ziessman HA. Parathyroid scintigraphy in patients with primary hyperparathyroidism: 99mTc sestamibi SPECT and SPECT/CT. *Radiographics* 2008;28:1461-1476
2. Cozzolino M. CKD-MBD KDIGO guidelines: how difficult is reaching the 'target'? *Clinical Kidney J* 2018;11:70-72
3. Yuen NK, Ananthakrishnan S, Campbell MJ. Hyperparathyroidism of renal disease. *Perm J* 2016;20:78-83
4. Lunn MR, Muñoz Mendoza J, Pasche LJ, Norton JA, Ayco AL, Chertow GM. Hyperparathyroidism with hypercalcaemia in chronic kidney disease: primary or tertiary? *NDT Plus* 2010;3:366-371
5. Hu J, Ngiam KY, Parameswaran R. Mediastinal parathyroid adenomas and their surgical implications. *Ann R Coll Surg Engl* 2015;97:259-261
6. Gordon J, Manley NR. Mechanisms of thymus organogenesis and morphogenesis. *Development* 2011;138:3865-3878
7. Roy M, Mazeh H, Chen H, Sippel RS. Incidence and localization of ectopic parathyroid adenomas in previously unexplored patients. *World J Surg* 2013;37:102-106
8. Lane MJ, Dessler TS, Weigel RJ, Jeffrey RB Jr. Use of color and power Doppler sonography to identify feeding arteries associated with parathyroid adenomas. *AJR Am J Roentgenol* 1998;171:819-823
9. Rodgers SE, Hunter GJ, Hamberg LM, Schellingerhout D, Doherty DB, Ayers GD, et al. Improved preoperative planning for directed parathyroidectomy with 4-dimensional computed tomography. *Surgery* 2006;140:932-940; discussion 940-941
10. Bahl M, Muzaffar M, Vij G, Sosa JA, Choudhury KR, Hoang JK. Prevalence of the polar vessel sign in parathyroid adenomas on the arterial phase of 4D CT. *AJNR Am J Neuroradiol* 2014;35:578-581

## 만성 신장질환 환자에서 흉선 내에서 발견된 이소성 부갑상선 선종: 증례 보고

추동민 · 김진환\* · 김성수

저자들은 치료저항성 고칼슘혈증을 주소로 내원한 만성 신장질환 환자에서 진단된 이소성 부갑상선 선종을 보고하고자 한다. Technetium-99m-sestamibi scintigraphy는 종격동에 발생한 이소성 부갑상선선종을 발견하는데 유용한 영상 기법이다. 전산화단층촬영에서 종괴가 조영증강이 매우 잘되고, 종괴 주변에 극혈관 소견이 같이 보이면 영상의학과 전문의가 종격동 내 다른 질환과 이소성 부갑상선 선종을 감별진단하는데 큰 도움을 줄 수 있다. 영상 진단 기술의 진보로 인해 종격동에서 발생하는 이소성 부갑상선 선종을 수술 전에 진단할 수 있게 되었으며, 불필요한 경부 검사와 시술을 피할 수 있게 되었다.

충남대학교 의과대학 충남대학교병원 영상의학과