



Clear Cell Hidradenoma and Hidradenocarcinoma Arising from Benign Hidradenoma: Imaging Findings of Ultrasonography and CT

투명세포땀샘종과 땀샘암종의 초음파 및 전산화단층촬영 영상 소견

Jiyeon Ha, MD¹ , Hye Won Chung, MD^{1*} , Joon Seon Song, MD²

¹Department of Radiology and Research Institute of Radiology, University of Ulsan College of Medicine, Asan Medical Center, Seoul, Korea

²Department of Pathology, University of Ulsan College of Medicine, Asan Medical Center, Seoul, Korea

Clear cell hidradenoma (HA) is a rare tumor of sweat glands. Although this tumor is benign, local recurrence often occurs when the resection margin is insufficiently obtained. The common imaging finding of HA is a mixed solid and cystic mass with or without increased vascularity in the solid portion. Malignant transformation of the tumor is also recognized. Hidradenocarcinoma (HAC), which is a malignant counterpart of benign HA, can develop *de novo* or arise from benign HA. However, imaging findings of HAC are not well established because these tumors are rare and they are commonly excised without imaging study. We present two cases of benign HA and HAC arising from benign HA with characteristic ultrasonography and computed tomography imaging features.

Index terms Soft Tissue Neoplasms; Poroid Hidradenoma; Sweat Gland Neoplasms; Ultrasonography; Computed Tomography, X-Ray

INTRODUCTION

Clear cell hidradenoma (HA) is a rare tumor of sweat glands. While the tumor was traditionally regarded to exhibit eccrine differentiation, it is now accepted that it can exhibit both eccrine and apocrine differentiation (1, 2). HA is also known as solid-cystic HA, nodular HA, eccrine acrospiroma and clear cell acrospiroma. In spite of be-

Received June 14, 2018
Revised August 30, 2018
Accepted September 20, 2018

***Corresponding author**
Hye Won Chung, MD
Department of Radiology and
Research Institute of Radiology,
University of Ulsan College of
Medicine, Asan Medical Center,
88 Olympic-ro 43-gil, Songpa-gu,
Seoul 05505, Korea.

Tel 82-2-3010-4371
Fax 82-2-3010-2768
E-mail chung@amc.seoul.kr

This is an Open Access article distributed under the terms of the Creative Commons Attribution Non-Commercial License (<https://creativecommons.org/licenses/by-nc/4.0>) which permits unrestricted non-commercial use, distribution, and reproduction in any medium, provided the original work is properly cited.

ORCID iDs

Hye Won Chung
<https://orcid.org/0000-0001-5597-8143>
Jiyeon Ha
<https://orcid.org/0000-0003-3496-4134>

nign nature of the tumor, local recurrence often occurs if sufficient resection margin is not obtained at the time of excision and malignant transformation can rarely occur. Hidradenocarcinoma (HAC), which is a malignant counterpart of benign HA, can develop *de novo* or arise from HA.

Typical image findings of HA were recently described, but the imaging features of HAC are not yet reported. It may be because these tumors are rare and imaging studies are often omitted due to superficial location and relatively slow growing nature of the tumor. We describe ultrasonography (US) and computed tomography (CT) features of benign HA and HAC arising from HA.

CASE REPORTS

CASE 1

A 57-year-old female presented with a solitary palpable mass at the medial aspect of the left ankle above the medial malleolus. The mass grew slowly over 3 years. She denied pain or functional impairment. The US (Fig. 1A) showed a 2-cm, well-demarcated, mainly anechoic cystic mass with internal echogenic solid component. The inner solid component or mural nodule arising from the deep portion of the lesion showed increased vascularity on Doppler US examination. On contrast enhanced CT images (Fig. 1B), there was a mass in the subcutaneous fat layer presenting as a non-enhancing hypodense cyst with peripheral mural enhancement and internal enhancing solid nodule as reflected by mixed cystic and solid appearance on the sonography. She underwent tumor excision. During the excision, the cystic component of the tumor contained brownish fluid resembling old hemorrhage. Histological examination (Fig. 1C) showed a cystic mass mixed with solid portion. On hematoxylin-eosin stain, the specimen showed polygonal and short spindle cells with multifocal fibrous stroma, and the solid portion contained vascular channels. The tumor was pathologically confirmed as HA with moderate nuclear atypia.

Fig. 1. A 57-year-old female with clear cell hidradenoma in the left ankle (Case 1).

- A. Transverse ultrasonography image shows a well-defined complex mass with solid and cystic components in the subcutaneous fat layer. Doppler examination shows hypervascularity in the solid component (arrowhead).
 B. Axial CT image shows a well-defined cystic and solid mass with multiple septa and enhancement of the central solid portion (arrow).
 C. Photomicrograph of the specimen (hematoxylin and eosin stain, $\times 100$) shows solid (S) and cystic portions (C) of the mass with vascular channels in the solid portion (arrow).

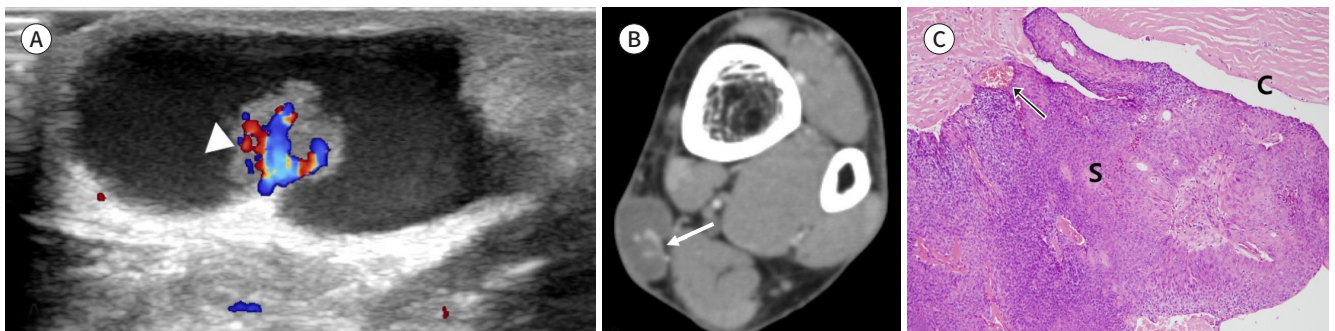
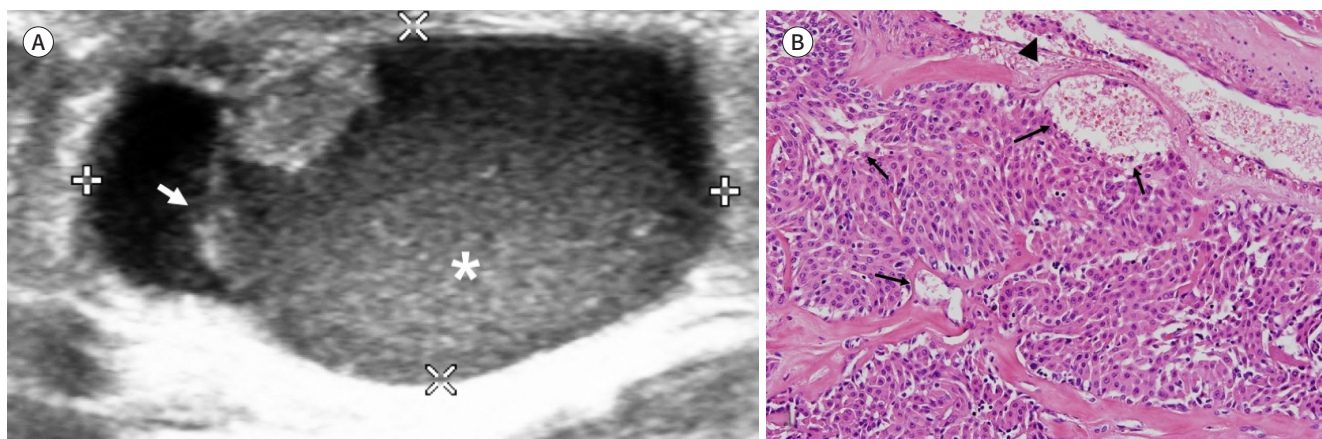


Fig. 2. A 24-year-old female with hidradenocarcinoma in the medial aspect of the left knee (Case 2).

A. Transverse ultrasonography image shows a well-defined cystic mass with a solid mural nodule in the subcutaneous fat layer. The echogenicity of the cystic portion (*) with posterior acoustic enhancement is not that of water reflecting hemorrhagic component. There is a septum-like structure (arrow) in the cystic portion.

B. High-power photomicrograph (hematoxylin and eosin stain, $\times 200$) shows multiple vascular channels (arrows) in the solid component and tumor cells in the vessel (arrowhead).



CASE 2

A 24-year-old female presented with a solitary palpable mass at the medial aspect of her left knee. The lesion was detected 3 years ago, and its size increased recently. The US showed a well-defined, cystic lesion with heterogeneous echogenicity in the subcutaneous fat layer (Fig. 2A). The size of the lesion was 3-cm. The lesion was composed of hypoechoic cyst with posterior acoustic enhancement and an echogenic nodule at the superficial aspect of the mass. The cystic component of the mass was not purely anechoic, suggesting intra-tumoral hemorrhage. It also contained septum like structure between the outer wall and inner echogenic nodular structure. The solid mural nodule did not reveal increased vascularity on Doppler examination. There was no evidence of distant metastasis on the positron emission tomography-CT. Excisional biopsy was performed and specimen revealed a mass with multifocal solid and cystic portions. The tumor cells showed infiltrative growth pattern invading the fibrous stroma. Multiple vascular channels were seen in the solid component of the mass with tumor infiltration within the vascular channels (Fig. 2B). The histopathology was consistent with HAC arising from HA. Additional wide excision was performed after the pathologic diagnosis, but there was no evidence of residual tumor. The patient was followed up for 2 years after the tumor excision with MR, CT, and PET-CT imaging, and there was no evidence of regional tumor recurrence or distant metastasis.

DISCUSSION

HAs are rare tumor classified as a cutaneous tumor of skin appendage. HAs are also known as solid-cystic HA, nodular HA, eccrine acrospiroma and clear cell acrospiroma. They often present as a slowly growing solitary mass, which commonly ranges from 0.5 to 3 cm in its diameter. The tumors are twice more likely to affect female than male. They are most often found in the trunk, lower extremity and head (1, 3). Although this is a benign tumor, local

recurrence often occurs when the resection margin is insufficiently obtained at the time of excision (4).

HAC is a malignant counterpart of HA. HAC can arise *de novo* or secondarily from preexisting HA. The rate of malignant transformation is currently not known. Malignant tumors of sweat gland are extremely rare with overall incidence of less than 0.005% (5). HAC can recur locally or metastasize distantly. Previous study reported the rate of local recurrence in the range of 14% to 20% and the rate of lymphangitic metastasis in the range of 20% to 24%. The prognosis of HAC is very poor and the 5 year post-surgical survival rate has been reported to be less than 30% (6-8).

The US of HA typically shows a mixed cystic and solid component similar to the present case (1, 3, 9). The solid component or echogenic nodular lesion commonly shows hypervascularity on Doppler exam. Increased vascularity in the solid mural nodules is due to the presence of multiple vascular channels confirmed on the histologic exam. Echogenicity of cystic component could be variable because of hemorrhage (1, 3). Septa in the cystic component may reflect the chronicity of the tumor. Recurrent hemorrhage and/or inflammation may account for thickening of outer wall and intra-tumoral septa.

CT image findings are not specific, but it correlates well with the US features. A well-demarcated, cystic and solid lesion is typical as the current case, and they may show enhancing wall and internal solid mural nodule (1).

To our knowledge, the imaging features of HAC have not been previously reported. In our cases, differentiation of HAC from benign HA by imaging examination was difficult. It has been known that differentiation of HAC from HA is difficult both clinically and microscopically (1, 2, 6). Therefore, we suggest performing US-guided core needle biopsy or wide excision of tumors for any HA considering malignant potential. Further imaging evaluation for distant metastasis can be recommended to any HAC after histologic diagnosis.

The differential diagnosis of HAs includes hemangioma, lymphangioma, lymphocele, ganglion cyst, sebaceous cyst, epidermal inclusion cyst, and trichillemmal tumor. However, multiseptated appearance, which is different from the sonographic findings of HA, can easily suggest the diagnosis of hemangioma or lymphangioma (1, 9). Even though lymphocele can be another differential diagnosis of cystic lesion, clinical history such as history of previous surgery can support the diagnosis. A ganglion cyst can also be a differential diagnosis of cystic lesion with septation. However, ganglion cysts occur nearby the joint space and thin stalks communicating with the joint space can be identified. Although epidermal inclusion cyst can present as a well-defined, mild echogenic mass like HA, internal echogenic debris can support the diagnosis of epidermal inclusion cyst. Trichillemmal tumor can present as a cystic and solid mass similar to HA. Intratumoral calcification, which is not common in HA, can be seen in trichillemmal tumor (10).

Given the rarity of these sweat gland origin tumors and lack of well-established imaging findings of HAC, we present two cases of benign HA and HAC with US and CT findings.

Conflicts of Interest

The authors have no potential conflicts of interest to disclose.

REFERENCES

1. Lee JY, Kang BS, Shim HS, Song IH, Kim M, Lee SH, et al. Clear cell hidradenoma: characteristic imaging features on ultrasonography, computed tomography, and magnetic resonance imaging. *J Ultrasound Med* 2018;37:1993-2001
2. Cardoso JC, Calonje E. Malignant sweat gland tumours: an update. *Histopathology* 2015;67:589-606
3. Cho KE, Son EJ, Kim JA, Youk JH, Kim EK, Kwak JY, et al. Clear cell hidradenoma of the axilla: a case report with literature review. *Korean J Radiol* 2010;11:490-492
4. Mullaney PJ, Becker E, Graham B, Ghazarian D, Riddell RH, Salonen DC. Benign hidradenoma: magnetic resonance and ultrasound features of two cases. *Skeletal Radiol* 2007;36:1185-1190
5. Chang CH, Chang KP, Huang SH, Lai YW, Huang WT, Lin SD, et al. Hidradenocarcinoma of the fingertip: a case report and literature review. *Dermatol Surg* 2011;37:704-708
6. Kane B, Adler E, Bhandari T, Rose M, DiGuglielmo N, Sun X. Malignant hidradenocarcinoma in the lower extremity: a case report of a rare tumor. *J Foot Ankle Surg* 2018;57:618-621
7. Chauhan K, Garg M, Dadwal E. Hidradenocarcinoma presenting with multiple site metastases. *Int J Histopathol Interpret* 2017;6:11-13
8. Ryu WC, Lee YH, Koh IC, Sohn JS, Jang SM. Hidradenocarcinoma of the dorsum of the hand. *Chin Med J* 2017;130:1755-1756
9. Wortsman X, Reyes C, Ferreira-Wortsman C, Uribe A, Misad C, Gonzalez S. Sonographic characteristics of apocrine nodular hidradenoma of the skin. *J Ultrasound Med* 2018;37:793-801
10. Kim HJ, Kim TS, Lee KH, Kim YM, Suh CH. Proliferating trichilemmal tumors: CT and MR imaging findings in two cases, one with malignant transformation. *AJNR Am J Neuroradiol* 2001;22:180-183

투명세포땀샘종과 땀샘암종의 초음파 및 전산화단층촬영 영상 소견

하지연¹ · 정혜원^{1*} · 송준선²

투명세포땀샘종은 땀샘에서 기원하는 매우 드문 종양으로 양성이지만 드물게 재발하거나 국소침윤성 병변으로 발현할 수 있다. 투명세포땀샘종의 영상 소견은 낭종성 병변과 고형종괴가 혼합된 형태로 고형종괴 부분의 혈류 증가는 동반되는 경우도 있으나 그렇지 않은 경우도 있는 것으로 알려져 있다. 투명세포땀샘종에서 악성 종양인 땀샘암종으로 발전하는 경우가 보고되어 있으며, 악성도는 절제 전 구분이 어려운 것으로 알려져 있다. 투명세포땀샘종과 땀샘암종은 모두 표재성 위치와 다소 천천히 자라는 특성으로 충분한 영상검사 없이 절제되는 경우가 많아 특징적 영상 소견이 정립되어 있지 않다. 따라서 저자들은 투명세포땀샘종과 이에서 기원한 땀샘암종의 증례를 초음파 및 전산화단층촬영 소견에 초점을 맞추어 보고한다.

¹울산대학교 의과대학 서울아산병원 영상의학과, 영상의학연구소,

²울산대학교 의과대학 서울아산병원 병리학과