



Palliative Transcatheter Arterial Chemoembolization for Relieving Metastatic Bone Pain due to Hepatocellular Carcinoma:

A Case Report

간세포암에서 유래한 골전이의 통증 완화를 위한 고식적 경동맥 화학색전술: 증례 보고

Hye Ji Ryu, MD¹, Sung Nam Moon, MD^{1*}, Nam Kyu Chang, MD²

¹Department of Radiology, Wonkwang University School of Medicine & Hospital, Iksan, Korea

²Department of Radiology, Yeonggwang Medical Center, Yeonggwang, Korea

Bone metastasis is the third most common extrahepatic metastasis from hepatocellular carcinoma (HCC), following lung and lymph node metastasis. Although transcatheter arterial chemoembolization (TACE) is widely used for the treatment for unresectable HCC in the liver, its effects on bone metastasis from HCC have not been well described in past literature. We report a case of a patient with a metastatic bone lesion from an HCC treated with TACE. After the procedure, the patient's pain and narcotic requirement significantly decreased without major complications.

Index terms

Chemoembolization, therapeutic
Hepatocellular Carcinoma
Bone Neoplasm

Received September 12, 2017

Revised May 15, 2018

Accepted May 22, 2018

*Corresponding author: Sung Nam Moon, MD
Department of Radiology, Wonkwang University
School of Medicine & Hospital, 895 Muwang-ro,
Iksan 54538, Korea.

Tel. 82-63-859-1920 Fax. 82-63-859-4749

E-mail: msnrage23@naver.com

This is an Open Access article distributed under the terms of the Creative Commons Attribution Non-Commercial License (<https://creativecommons.org/licenses/by-nc/4.0>) which permits unrestricted non-commercial use, distribution, and reproduction in any medium, provided the original work is properly cited.

INTRODUCTION

Hepatocellular carcinoma (HCC) is the sixth most common malignancy and the third cause of cancer related deaths in the world (1). As treatment methods of HCC such as surgical resection, liver transplantation, percutaneous radiofrequency ablation (RFA), transcatheter arterial chemoembolization (TACE) have been developed, the survival rate of HCC patients and incidence of extrahepatic metastasis including bone metastasis has increased (2). Because bone metastasis usually manifests as intolerable pain and decreases quality of life, palliative treatment for bone metastasis are critical for patients' quality of life. Although TACE is widely used for controlling unresectable HCC in liver, it is rarely used for treatment for bone metastasis from HCC and few studies have been reported about the effec-

tiveness of TACE for bone metastasis of various primary origins (3-5).

We report a successful case of controlling intolerable pain with palliative TACE in a patient with bone metastasis from HCC.

CASE REPORT

A 66-year-old man with a history of bone metastasis from HCC visited our hospital with persistent right shoulder pain. He was first diagnosed HCC 5 years ago and since then, he has undergone surgical resection and RFA for HCC lesion of the liver. Although there was no HCC recurrence in the liver after treatment, the patient developed right shoulder pain 1 year ago and CT revealed a 7.1 × 3.7 cm sized hypervascular mass involv-

ing right posterior 3rd rib and T2, T3 vertebral body, confirmed by pathology to be a bone metastasis from HCC. For treatment of bone metastasis, the patient received radiotherapy and chemotherapy with reduced dose (600 mg for a day) of sorafenib (Nexavar; Bayer Korea, Seoul, Korea) because of grade 3 hand-foot skin reaction, a side effect of sorafenib.

Despite treatment, the metastatic bone lesion increased from 7.1×3.7 cm to 8.8×4.1 cm with narrowing of the spinal canal of T3 level on follow-up CT after a year. Right shoulder pain worsened and the patient took Codeine 10 mg/ Ibuprofen 20

mg/acetaminophen 25 mg twice daily (Mypol Cap; Sungwon Adcock Pharm, Seoul, Korea) and Oxycodone hydrochloride 5 mg tab every 8 hours (IRcodone; Unimed Pharm, Seoul, Korea).

Because other therapeutic options were needed for the patient's pain relief, he was referred to interventional radiology for treatment of metastatic bone lesion from HCC. We planned conventional TACE using doxorubicin hydrochloride 20 mg (Adriamycin RDF; Ildong, Seoul, Korea) mixed with emulsion of iodized oil 10 cc (Lipiodol; Delpharm tours, Rue Paul Langevin, France) and Gelatin sponge particle (Gelfoam 1000–1400

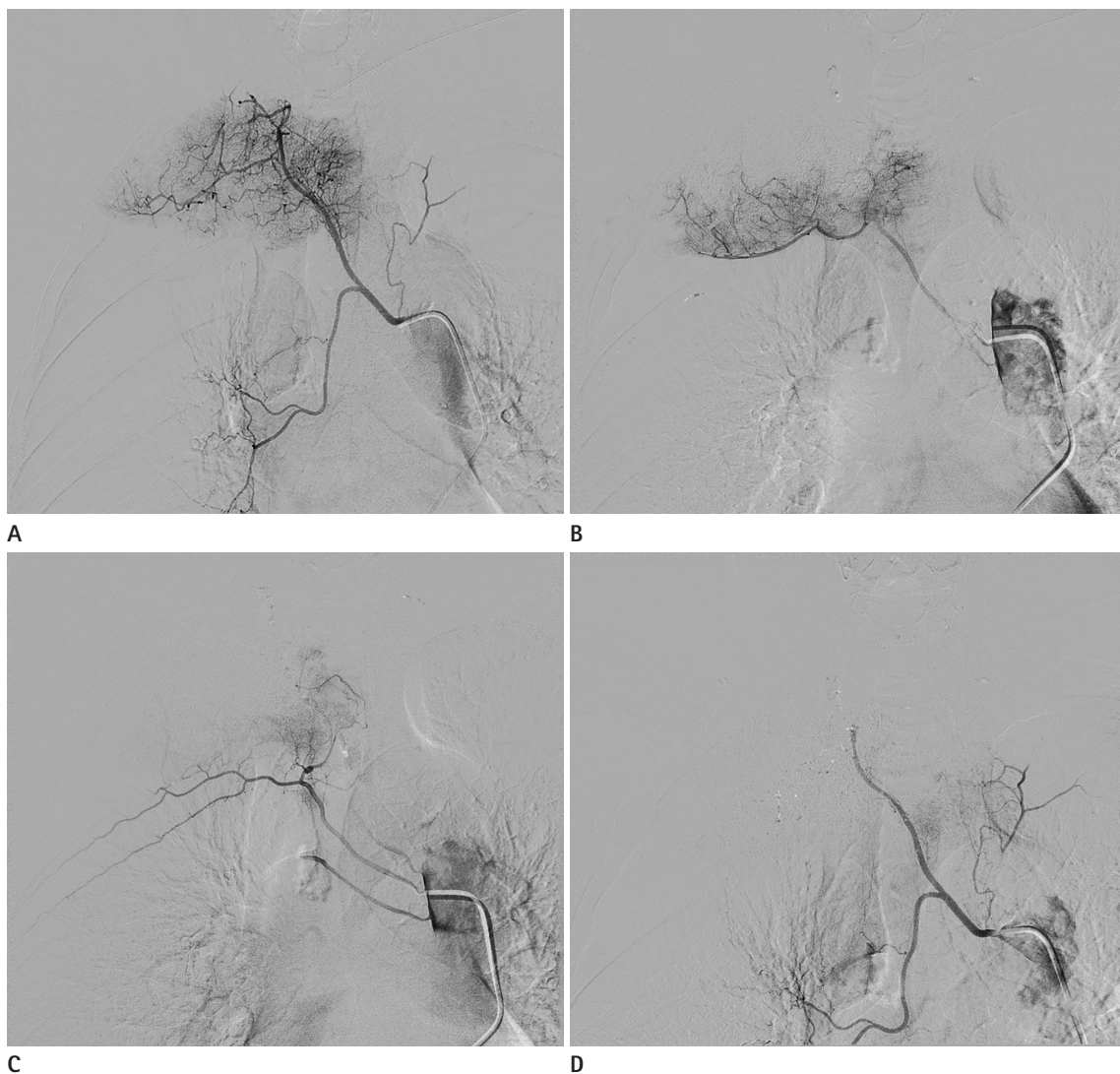
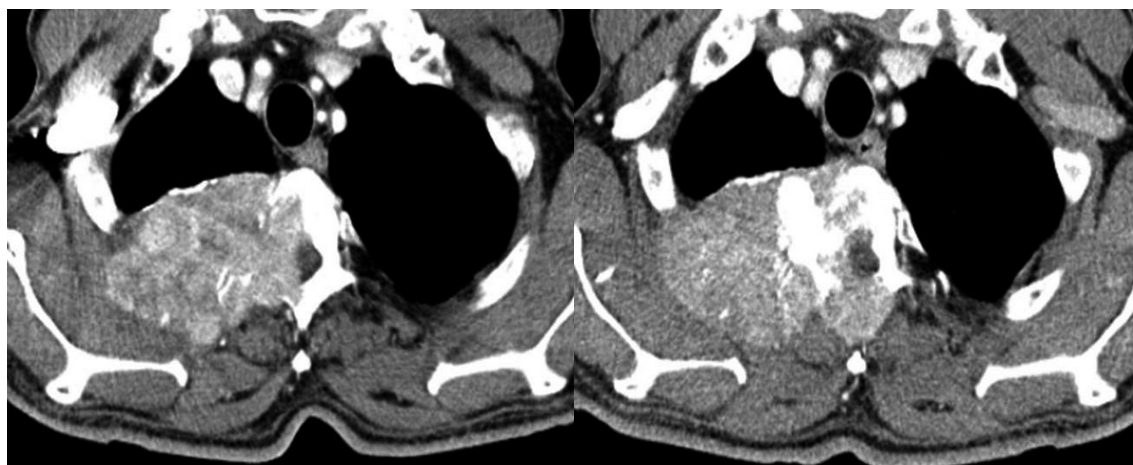


Fig. 1. TACE of symptomatic bone metastasis from hepatocellular carcinoma in a 66-year-old man.

A–C. In the selective arteriogram of the right intercostobronchial trunk (**A**), right 3rd (**B**), 4th and 5th (**C**) intercostal arteries, tumoral staining that correspond to the bone metastasis are seen.

D. Completion angiogram after TACE using chemomixture of Adriamycin and lipiodol and gelfoam particle reveals > 75% reduction of tumor blush, which means technical success.

TACE = transcatheter arterial chemoembolization



E

Fig. 1. TACE of symptomatic bone metastasis from hepatocellular carcinoma in a 66-year-old man.

E. On follow-up CT after 3 months of TACE (right), size of the mass narrowing T3 spinal canal decreases and marginal shape of the mass changes to concave compared to CT before TACE (left).

TACE = transcatheter arterial chemoembolization

µm; Alicon, Hangzhou, China). On the right intercostobronchial trunk and intercostal artery angiography using 5 Fr angiographic catheter (A&A M.D., Seongnam, Korea), there was tumoral staining in destructing bone lesion of the right 2nd, 3rd rib and vertebral body, fed by the right intercostobronchial trunk and right 3rd, 4th, 5th intercostal arteries (Fig. 1A-C). After superselection of these tumoral feeders with 2.4 Fr microcatheter (Renegade STC; Boston Scientific, Marlborough, MA, USA), chemoembolization was conducted carefully under fluoroscopic guidance to prevent reflux of chemoembolization agent to non-target regions. Because we view TACE as palliative treatment, we did not find and embolize all tumoral feeders but focused instead on main feeders supplying medial side of the tumor, thought to have more impact on the patient's painful and neurological symptoms by the compressing or invading spinal cord. A completion angiography revealed >75% reduction of tumor blush (Fig. 1D) and was categorized as grade 1 technical success according to devascularization grade described in the previous study (3). C-arm cone-beam computed tomography after the procedure also revealed lipiodol uptake in most of metastatic lesion, especially the medial side of the tumor.

On the day of TACE, the patient experienced severe pain intermittently and received additional morphine sulfate 2 mg IV (BCworld Pharm, Seoul, Korea) three times and Fentanyl patch (Matrifem; Daewoong Pharm, Seongnam, Korea) two times for pain relief. However, the day after TACE, pain started to de-

crease and three days later, was surprisingly improved to take only Mypol cap. He discharged without complications.

On follow-up CT after 3 months of TACE, total size of the metastatic mass had increased to 11 × 5 cm. However, with remaining lipiodol uptake at the medial portion of the metastatic mass, size of the mass narrowing T3 spinal canal significantly decreased and marginal shape of the mass changed from flat to concave (Fig. 1E). Although pain was assessed based on subjective reports instead of a numeric rating scale during follow up period, the patient's pain dramatically decreased as compared to before the procedure and narcotic requirement significantly decreased and was maintained without need of medication for breakthrough pain (Fig. 2).

DISCUSSION

In HCC patients, bone metastasis is common after lung and lymph node metastasis, ranging from 4–20% and frequently found in vertebrae, pelvis and ribs (2). Characteristic features of bone metastasis from HCC are hypervascular, osteolytic, expansile extraskeletal mass (2).

Osteolytic bone metastasis often causes pain but its mechanism for pain without fracture is not well understood. Various mechanisms such as stretching of periosteum, mechanical stress within the bone, compression of nerve by tumor & collapsed vertebrae, microfracture, release of chemical mediators,

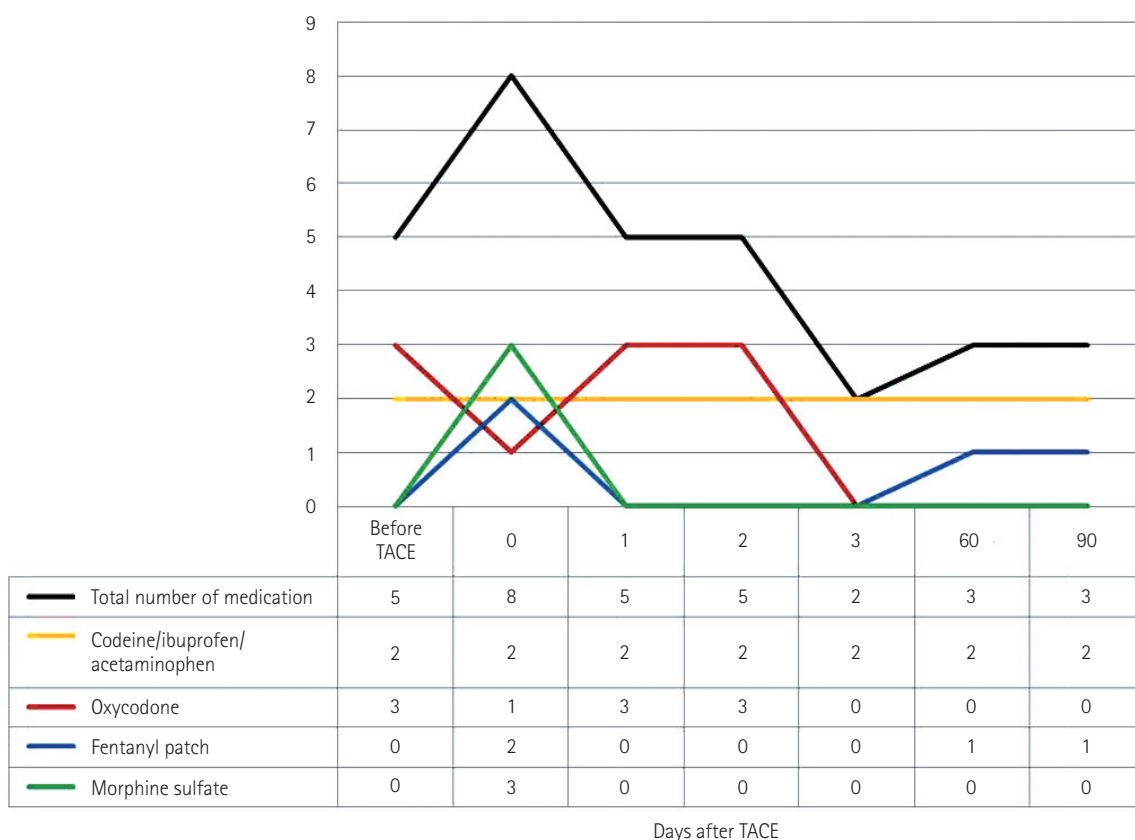


Fig. 2. Total number of medication decreased with improved patient's pain after TACE as depicted in this graph.
TACE = transcatheter arterial chemoembolization

reactive muscle spasm, nerve root infiltration are associated with painful bone metastasis (6). Because pain caused by bone metastasis is often severe and decreases a patient's quality of life, various treatments including mainly radiotherapy have been used. Although TACE is not usually considered a treatment for bone metastasis, hypervascular nature of bone metastasis from HCC makes TACE a possible therapeutic option.

TACE has additional effect over transcatheter arterial embolization (TAE). It induces hypoxic necrosis by decreasing tumoral blood supply and kills tumor cells by increasing local concentration of cytotoxic chemotherapeutic agent. In bone metastasis, it can relieve metastatic bone pain by reducing periosteal distention and compression effect on adjacent structures and finally decreases the need for opioid analgesics that reduce pain perception by acting as an agonist on opioid receptors predominant in the central nervous system (7).

Efficacy of TACE in metastatic bone pain is not clearly established. A previous study by Chiras et al. (4) using carboplatin and pirarubicin mixed with polyvinyl alcohol reported 83% of

patients with metastatic bone lesion from various primary origins (kidney, soft tissue tumor, breast, etc, except liver) had significant pain relief after the procedure and pain relief duration was mean 12 months, that was longer than TAE that rarely exceeded 6 months. Another study by Koike et al. (3) using various embolic and chemotherapeutic agents for hypervascular bone metastasis revealed TACE/TAE were rapid acting as much as radiotherapy, that could relieve pain within 48 hours after therapy and expected to be effective in radiologic response of metastatic bone lesion in addition to pain relief.

In our experience, pain decreased three days after TACE with reduced dose of opioid analgesics. Although the total size of the mass involving 3rd rib, T2–5 vertebral body and adjacent muscle increased on follow up CT images after 3 months of the procedure, the patient's opioid analgesic requirement significantly decreased with the reduced size of mass portion invading the spinal canal of T3 level. In our opinion, infiltration and compression of spinal cord was the most significant contributing factor to our patient's metastatic bone pain.

One of the major complications of TACE in metastatic spinal tumors is the ischemic injury of spinal cord, caused by non-target embolization of anterior spinal arteries. It also has been reported that ischemic edema of the target tumor region after TAE could cause spinal cord compression and neurologic symptoms mimicking spinal cord injury (8). Postembolization syndrome, one of the common complications of solid organ embolization, is variously reported to range from 18–72% in bone embolization according to previous literature (9, 10). In our case, no significant complication was observed except postprocedural pain controlled by analgesics on the day of TACE.

Although follow up period after TACE was brief for 3 months in our patient, his metastatic bone pain was considerably relieved without major complications. In conclusion, our case report demonstrates palliative TACE for bone metastasis from HCC could be effective in relieving bone pain, especially for patients with limitation of other therapeutic options.

REFERENCES

1. Ferlay J, Shin HR, Bray F, Forman D, Mathers C, Parkin DM. Estimates of worldwide burden of cancer in 2008: GLOBOCAN 2008. *Int J Cancer* 2010;127:2893–2917
2. Fukutomi M, Yokota M, Chuman H, Harada H, Zaitzu Y, Funakoshi A, et al. Increased incidence of bone metastases in hepatocellular carcinoma. *Eur J Gastroenterol Hepatol* 2001;13:1083–1088
3. Koike Y, Takizawa K, Ogawa Y, Muto A, Yoshimatsu M, Yagihashi K, et al. Transcatheter arterial chemoembolization (TACE) or embolization (TAE) for symptomatic bone metastases as a palliative treatment. *Cardiovasc Intervent Radiol* 2011;34:793–801
4. Chiras J, Adem C, Vallée JN, Spelle L, Cormier E, Rose M. Selective intra-arterial chemoembolization of pelvic and spine bone metastases. *Eur Radiol* 2004;14:1774–1780
5. Kato T, Nemoto R, Mori H, Takahashi M, Harada M. Arterial chemoembolization with mitomycin C microcapsules in the treatment of primary or secondary carcinoma of the kidney, liver, bone and intrapelvic organs. *Cancer* 1981;48:674–680
6. Mercadante S. Malignant bone pain: pathophysiology and treatment. *Pain* 1997;69:1–18
7. Stein C. Opioids, sensory systems and chronic pain. *Eur J Pharmacol* 2013;716:179–187
8. Uemura A, Fujimoto H, Yasuda S, Osaka I, Goto N, Shinozaki M, et al. Transcatheter arterial embolization for bone metastases from hepatocellular carcinoma. *Eur Radiol* 2001;11:1457–1462
9. Barton PP, Waneck RE, Karnel FJ, Ritschl P, Kramer J, Lechner GL. Embolization of bone metastases. *J Vasc Interv Radiol* 1996;7:81–88
10. Sun S, Lang EV. Bone metastases from renal cell carcinoma: preoperative embolization. *J Vasc Interv Radiol* 1998;9:263–269

간세포암에서 유래한 골전이의 통증 완화를 위한 고식적 경동맥화학색전술: 증례보고

류혜지¹ · 문성남^{1*} · 장남규²

골전이는 폐와 림프절 다음으로 간세포암의 3번째로 흔한 간외전이이다. 경동맥화학색전술이 절제불가능한 간내 간세포암의 치료에 널리 사용되고 있지만 간세포암의 골전이에서의 효과에 대해서는 잘 알려져 있지 않다. 이에 본 저자들은 간세포암의 골전이가 있었던 환자에서 경동맥화학색전술로 치료하였던 증례를 보고하고자 한다. 시술 후 주요 합병증 없이 환자의 통증과 마약성 진통제 필요량이 감소하였다.

¹원광대학교 의과대학 원광대학교병원 영상의학과, ²영광종합병원 영상의학과