



Functional Magnetic Resonance Imaging to Evaluate Patient Satisfaction Following Bimaxillary Surgery: A Preliminary Study

양악수술 후 환자만족도 평가를 위한 기능적 자기공명영상: 예비연구

Jae-Seung Kim, DDS¹, Mina Park, MD², Moon-Jung Hwang, PhD³, Won-Jin Moon, MD^{2*}

¹Department of Dentistry, Konkuk University Medical Center, Seoul, Korea

²Department of Radiology, Konkuk University Medical Center, Konkuk University School of Medicine, Seoul, Korea

³GE Healthcare, Seoul, Korea

Although bimaxillary surgery enhances patients' self-esteem and mood by improving their facial appearance, surgical outcome assessments for this procedure are limited. This preliminary study investigated differences in brain activity on functional magnetic resonance imaging (fMRI) during self-face evaluation before and after bimaxillary surgery. Three patients (1 man and 2 women, age range: 20–27 years) underwent fMRI while viewing self-face images before and after bimaxillary surgery for maxillofacial deformity. The activation in the left postcentral gyrus, and medial orbital frontal cortex was significantly great in response to after-surgery self-face images compared to before-surgery images. Our preliminary results may facilitate the development of an objective measure for patient satisfaction after orthognathic surgery including bimaxillary surgery.

Index terms

Facial Recognition
Functional Magnetic Resonance Imaging
Orthognathic Surgery
Reward
Treatment Outcome

INTRODUCTION

With the development of advanced plastic surgery techniques and increasing interest in facial attractiveness in modern society, the number of facial plastic surgeries has dramatically increased over the past decade. Approximately 5000 cosmetic bimaxillary surgeries are reportedly performed annually in Korea (1). Bimaxillary surgery or orthognathic surgery is a unique category of surgery that improves both the patient's appearance and dental occlusal function by correcting maxillo-facial deformity. Accordingly, bimaxillary surgery has a tremendous effect on patient self-esteem and well-being (2). At present, the surgical outcome of bimaxillary procedures is only assessed via sub-

jective patient responses to a questionnaire (3). Thus, there is a need for a more objective tool for measuring surgical outcomes and patient satisfaction in the field of orthognathic surgery.

With the advent of functional magnetic resonance imaging (fMRI), blood-oxygen level-dependent activity can be measured *in vivo* as a surrogate for brain activation during task performance. Previous fMRI studies have revealed that the orbito-frontal cortex (OFC) is prominently activated in response to attractive faces compared to unattractive faces (4, 5). The OFC is an important brain area involved in reward, and it functions together with the ventral striatum and ventral tegmental areas in the brain reward system (4). In the present study, we assessed neural activity using fMRI during the evaluation of self-face im-

Received December 6, 2017

Revised January 14, 2018

Accepted January 27, 2018

*Corresponding author: Won-Jin Moon, MD
Department of Radiology, Konkuk University Medical Center, Konkuk University School of Medicine, 120 Neungdong-ro, Gwangjin-gu, Seoul 05029, Korea.
Tel. 82-2-2030-5544 Fax. 82-2-2030-5549
E-mail: mdmoonwj@kuh.ac.kr

This is an Open Access article distributed under the terms of the Creative Commons Attribution Non-Commercial License (<http://creativecommons.org/licenses/by-nc/4.0>) which permits unrestricted non-commercial use, distribution, and reproduction in any medium, provided the original work is properly cited.

ages from before and after bimaxillary surgery in order to assist the development of a new approach for predicting patient satisfaction with regard to surgical outcomes. Specifically, we devised a new fMRI-based test of patient satisfaction based on the assumption that brain areas related to reward processing would show greater activation in response to postoperative faces than preoperative faces.

CASE REPORT

Bimaxillary surgery for maxillofacial deformity was performed on 3 patients (1 man and 2 women, age range: 20–27 years) who subsequently underwent fMRI while viewing self-face images before and after surgery. None of the patients had a history of neurologic disorder or psychiatric illness, and all patients were right-handed. The study was approved by the Institutional Review Board and each subject provided written informed consent for participation.

Image Preparation

Presurgical and postsurgical face images were prepared for each patient. All images were photographed and obtained under the same lighting conditions from different views (frontal, 30° rightward from the frontal view, and 30° leftward from the frontal view). Face photographs were taken with a neutral facial expression with eyes directed toward the front.

MR Acquisition

fMRI images were obtained using a 3T scanner with a 32-channel head coil (Skyra, Siemens Healthcare, Erlangen, Germany). Three-dimensional (3D) anatomical volumes were collected using a high-resolution T1 Magnetization Prepared Rapid Acquisition Gradient Echo sequence. The fMRI images were obtained using a gradient-echo echo planar imaging (EPI) sequence with 160 dynamic volumes: repetition time = 3000 ms, echo time = 35 ms, flip angle = 90°, imaging matrix = 100 × 100, field of view = 200 × 200 mm, section thickness = 4 mm, no gap, and 34 axial slices.

In our experimental design, before-surgery blocks and after-surgery blocks were alternated 4 times in a random order in each session. Each block consisted of 10 images presented for 1 s each. Once the image had disappeared, a small fixation cross appeared

in the center of the screen. The time required for each activation block was 30 s, and a 30 s rest block was inserted between the activation blocks (before-surgery blocks and after-surgery blocks). During the rest block, a small fixation cross on a black background was presented. The session acquisition time was 8 min (Fig. 1). Subjects were asked to lie still and focus on the images that appeared on a screen visible through an overhead mirror within the magnetic resonance scanner. Subjective postsurgical satisfaction was also recorded.

Data Analysis

Functional data analysis was performed using SPM 8 software (www.fil.ion.ucl.ac.uk/spm/). The first 4 volumes of each data set were discarded to allow for equilibration effects. EPI images were corrected for slice time differences and realigned to the first scan by rigid body transformation to correct for head movement. EPI and structural scans were normalized to the EPI standard template in the Montreal Neurologic Institute (MNI) space (MNI: International Consortium for Brain Mapping) using linear and nonlinear transformations, and finally, were smoothed with an 8-mm full-width at half-maximum Gaussian kernel. The voxels representing active structures were overlaid on 3D T1-weighted anatomical images in MNI coordinates.

Given that only 3 cases were analyzed in the present study, we performed single subject analyses using a general linear model.

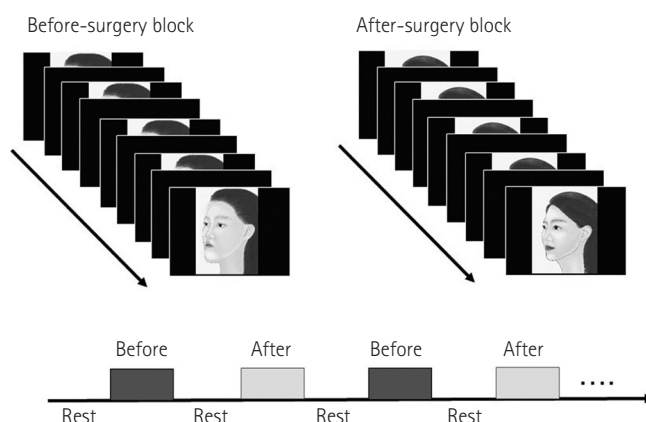


Fig. 1. Functional magnetic resonance imaging experimental design. Before surgery blocks and after-surgery blocks were alternated 4 times in a random order in each session. Each block consisted of 10 images presented for 1 s each. Once the image had disappeared, a small fixation cross appeared in the center of the screen. The time required for each block was 30 s, and a 30 s rest block was inserted between the activation blocks (before surgery blocks and after surgery blocks). During the rest block, a small fixation cross on a black background was presented.

As the foci of activation were predicted a priori, correction for the entire brain volume was not carried out, and uncorrected statistics were used to reject the null hypothesis. The threshold of significance was set at $p < 0.001$ and $p < 0.01$ at the voxel level (uncorrected for multiple comparisons) with an extent threshold of 10 contiguous voxels and 5 contiguous voxels, respectively.

fMRI Results

All three patients reported that they were satisfied with the

surgical result in terms of facial attractiveness. fMRI revealed that images of faces taken after surgery produced greater activation in the left postcentral gyrus [brodmann area (BA) 3 and BA40], cerebellar vermis, and right medial OFC (BA11) than images taken before surgery ($p < 0.001$ and a cluster size of 10 voxels) (Table 1, Fig. 2). With a threshold of $p < 0.01$ and a cluster size of 5 voxels, the left medial OFC was also more highly activated in response to images of faces after surgery versus before surgery.

Table 1. Montreal Neurological Institute Coordinates of Neural Activation in 3 Subjects

	After > Before		Before > After	
	Region	X, Y, Z	Region	X, Y, Z
Case 1	Left postcentral	-46, -34, 54	Right posterior cingulate	4, -40, 16
	Left Precuneus	-10, -42, 74	Right angular gyrus	46, -68, 46
	Right medial orbital frontal (BA11)	10, 14, -18*	Right superior medial frontal gyrus	4, 52, 42
			Left superior medial frontal gyrus	-2, 62, 10
			Left supplementary motor area	-2, 14, 66
			Left inferior frontal gyrus (triangular)	-40, 10, 24
Case 2	Vermis 4-5	0, -50, 6	Left angular gyrus	-40, 68, 40
	Left medial orbital* frontal (BA11)	-12, 14, 22*	Calcarine, right	24, -48, 4
			Middle frontal, left	-34, 46, 2
Case 3	Right medial orbital frontal (BA11)	10, 50, -26	Left medial frontal gyrus	-4, 54, -12
		20, 50, -16*	Left middle temporal gyrus	-48, -60, -2

Peak voxel sizes for all regions were obtained from a whole-brain random-effects contrast of before surgery and after surgery face stimuli. $p < 0.001$, uncorrected at the voxel level with extent of 10 contiguous voxels or more.

* $p < 0.01$, uncorrected at the voxel level with extent of 5 contiguous voxels or more.

BA = brodmann area

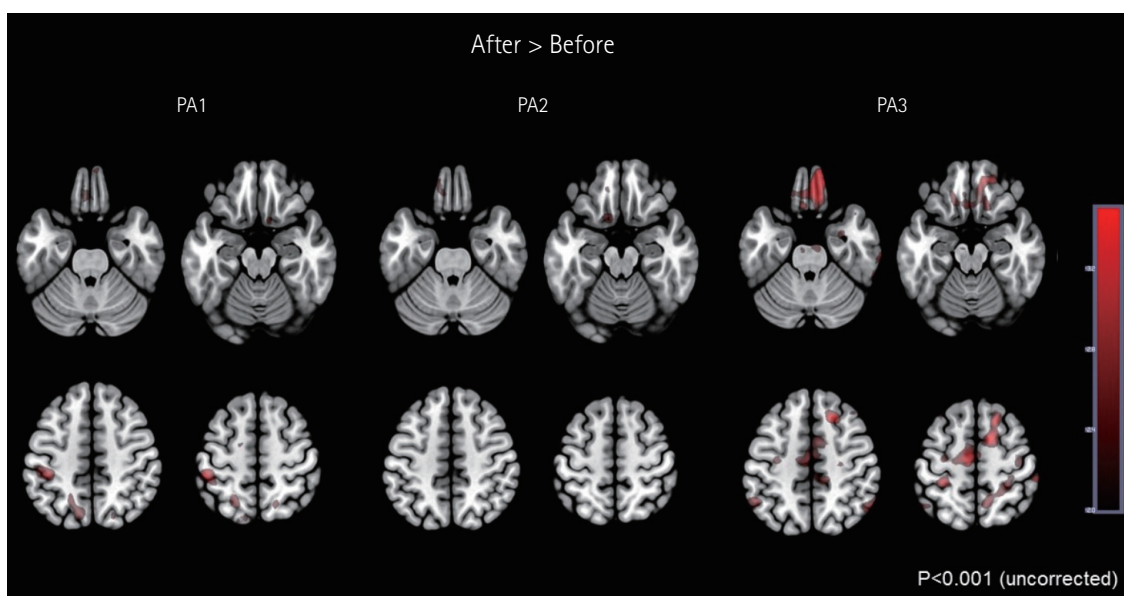


Fig. 2. Increased activation in response to after-surgery faces versus before-surgery faces. Images of faces taken after surgery revealed greater activation in the left postcentral gyrus, cerebellar vermis, and right medial orbitofrontal cortex than images taken before surgery ($p < 0.001$ and a cluster size of 10 voxels) and left medial orbitofrontal cortex ($p < 0.01$ and a cluster size of 5 voxels). Brain left is on the figure left. PA = patient

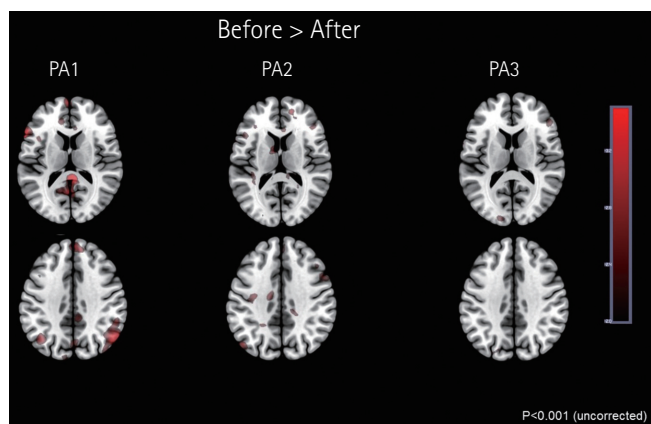


Fig. 3. Increased activation in response to before-surgery faces versus after-surgery faces. Images of faces taken before surgery revealed greater activation in the right posterior cingulate cortex, bilateral inferior parietal lobules, left superior frontal gyrus, bilateral medial frontal gyri, left inferior frontal gyrus, right parahippocampal gyrus, left middle frontal gyrus, and left middle temporal gyrus than those taken after surgery ($p < 0.001$ and a cluster size of 10 voxels). Brain left is on the figure left. PA = patient

In contrast, fMRI revealed that images of faces taken before surgery produced greater activation in the right posterior cingulate cortex, bilateral inferior parietal lobules, left superior frontal gyrus, bilateral medial frontal gyri, left inferior frontal gyrus, right parahippocampal gyrus, left middle frontal gyrus, and left middle temporal gyrus than those taken after surgery (Table 1, Fig. 3).

DISCUSSION

This preliminary report identified prominent neural activation in the medial OFC and left postcentral cortex in patients viewing photographs of their faces after bimaxillary surgery compared to before surgery and found that it is feasible to identify the after-surgery effect on patient satisfaction using fMRI by presenting the difference in neural activation.

The medial OFC is associated with decision making, reward processing, planning, encoding new information into long term memory, and reasoning. The medial OFC is also activated in response to viewing attractive faces, and activation is further enhanced by smiling facial expressions (5, 6). To this end, the OFC is involved in processing at least some emotional facial expressions (5). The OFC is further involved in representing the reward value of gustatory, olfactory, auditory, and somatosen-

sory stimuli (5, 7) and is sensitive to abstract reinforcers such as winning or losing money or positive and negative verbal feedback (5, 7). Previous studies have suggested that attractive faces can act as a type of reward (5, 6). Given our result, higher activation in the medial OFC in response to viewing after-surgery self-faces indicates that patients implicitly regarded after-surgery photographs as more attractive and rewarding.

Our findings regarding the left postcentral gyrus can be interpreted as representing the primary somatosensory cortex (BA3) and part of the supramarginal gyrus (BA40). Platek et al. (8) contrasted activation in response to viewing self-faces and unknown faces and revealed differential activation in the right postcentral, supramarginal, and superior temporal gyri. Shen et al. (9) reported that activation in the postcentral gyrus linearly correlated with facial attractiveness. Our findings corroborate and expand this previous result indicating that the postcentral gyrus, in addition to representing one's own face and body in the cerebral cortex, may participate in aesthetic evaluation of the faces and bodies (10).

Several areas were more strongly activated in response to before-surgery faces compared to after-surgery faces in our study including the calcarine cortices and inferior parietal lobules. Given a previous fMRI result that these areas were activated in response to subjectively unattractive or neutral faces rather than attractive faces (10), we can speculate that our subjects might have regarded their own before-surgery faces as neutral or unattractive.

To the best of our knowledge, this is the first study to identify differential neural activation in response to self-face evaluation before and after bimaxillary orthognathic surgery using fMRI. This fMRI test does not require any interventions such as blood sampling or intravenous contrast agent administration; it only requires 30 minutes of examination time and patient compliance. The innate subjective nature of aesthetic surgery often involves unnecessary medicolegal issues that have medico-social implications and lead to increasing dissatisfaction for both the surgeons and the patients involved. Further, malicious attempts to obtain secondary gain can lead to an unreliable self-report on postoperative satisfaction. Thus, a more objective test is needed. In this respect, the results of this technical report are the first step towards the development of a more objective test of satisfaction after bimaxillary surgery.

There are a few limitations to our preliminary study. Too small

a sample may prevent our findings from being generalized at this moment. A further prospective study would be necessary to confirm our findings in a larger cohort. Second, we did not include the subjects who were not satisfied with their surgical results. Inclusion of both satisfied and unsatisfied group over their surgical results will be essential for the future study.

Our results suggest that the left postcentral gyrus and the right or left medial OFC are involved in positive self-face evaluation after surgery. This preliminary result may facilitate the development of an objective tool for measuring patient satisfaction with regard to surgical outcomes after orthognathic surgery.

Acknowledgments

This work was supported by the National Research Foundation of Korea (NRF) grant funded by the Korea government (MSIP) (No. 2017R1A2B4010634).

REFERENCES

1. Hwang K, Choi YB. Postoperative monitoring following jaw surgery is essential. *Arch Plast Surg* 2013;40:66-67
2. Khechoyan DY. Orthognathic surgery: general considerations. *Semin Plast Surg* 2013;27:133-136
3. Murphy C, Kearns G, Sleeman D, Cronin M, Allen PF. The clinical relevance of orthognathic surgery on quality of life. *Int J Oral Maxillofac Surg* 2011;40:926-930
4. Ueno A, Ito A, Kawasaki I, Kawachi Y, Yoshida K, Murakami Y, et al. Neural activity associated with enhanced facial attractiveness by cosmetics use. *Neurosci Lett* 2014;566:142-146
5. O'Doherty J, Winston J, Critchley H, Perrett D, Burt DM, Dolan RJ. Beauty in a smile: the role of medial orbitofrontal cortex in facial attractiveness. *Neuropsychologia* 2003;41:147-155
6. Aharon I, Etcoff N, Ariely D, Chabris CF, O'Connor E, Breiter HC. Beautiful faces have variable reward value: fMRI and behavioral evidence. *Neuron* 2001;32:537-551
7. Stalnaker TA, Cooch NK, Schoenbaum G. What the orbitofrontal cortex does not do. *Nat Neurosci* 2015;18:620-627
8. Platek SM, Loughhead JW, Gur RC, Busch S, Ruparel K, Phend N, et al. Neural substrates for functionally discriminating self-face from personally familiar faces. *Hum Brain Mapp* 2006;27:91-98
9. Shen H, Chau DK, Su J, Zeng LL, Jiang W, He J, et al. Brain responses to facial attractiveness induced by facial proportions: evidence from an fMRI study. *Sci Rep* 2016;6:35905
10. Martín-Loeches M, Hernández-Tamames JA, Martín A, Urrutia M. Beauty and ugliness in the bodies and faces of others: an fMRI study of person esthetic judgement. *Neuroscience* 2014;277:486-497

양악수술 후 환자만족도 평가를 위한 기능적 자기공명영상: 예비연구

김재승¹ · 박미나² · 황문정³ · 문원진^{2*}

양악수술은 안면교정과 함께 환자의 자기 얼굴 평가와 자존감 향상에 영향을 미치나, 이를 평가할 수 있는 객관적 평가도가 없다. 이에 저자는 양악수술을 시행한 3명의 환자(남:여 = 1:2, 20~27세)에서 기능적 자기공명영상으로 수술 전/후 자기 얼굴 평가시 뇌 활성화 차이의 분석결과를 보고한다. 기능적 자기공명영상에서 수술 전 사진과 비교하여 수술 후 자기 얼굴 사진을 보았을 때 좌측 중심후피질과 좌측 내측안와전두피질에서 활성화를 보였다. 본 예비 결과는 양악수술 환자의 수술 만족도 평가를 위한 객관적 도구개발의 가능성을 제시한다.

¹건국대학교병원 치과, ²건국대학교 의학전문대학원 건국대병원 영상의학과, ³GE 헬스케어