



Physiologic Flow Related Signal Intensity in Dural Sinuses on Time of Flight Magnetic Resonance Angiography: Changes Caused by Head Elevation

자기공명영상 혈관촬영술에서 보이는 경막정맥동의 혈류 연관 신호:
두부거상에 의한 변화 관찰

Jieun Roh, MD¹, Seung Kug Baik, MD^{1,2*}, Jeong A Yeom, MD¹, Young Soo Kim, MD³,
Hee Seok Jeong, MD¹, Chang Hyo Yoon, MD⁴, Junhee Han, PhD⁵

Departments of ¹Radiology, ³Neurosurgery, Pusan National University Yangsan Hospital, Pusan National University School of Medicine, Yangsan, Korea

²Research Institute of Convergence for Biomedical Science and Technology, Pusan National University Yangsan Hospital, Pusan National University School of Medicine, Yangsan, Korea

⁴Department of Neurology, Kyungpook National University Hospital, Kyungpook National University School of Medicine, Daegu, Korea

⁵Department of Statistics, Hallym University, Chuncheon, Korea

Purpose: The presence of a flow-related signal in the normal dural sinus time of flight magnetic resonance angiography (TOF MRA) is common. This study aimed to identify changes in signal intensity in the dural sinus caused by changes in patient position.

Materials and Methods: The researchers performed an elevation TOF MRA of the cerebral region in 52 patients, who showed abnormal flow-related signals in the dural sinuses on supine position. Flow-related signal intensity in the dural sinuses was then analyzed.

Results: Flow-related signals were seen in 114 sites (52 patients), specifically in the internal jugular vein (IJV), sigmoid sinus (SS), inferior petrosal sinus (IPS), and cavernous sinus (CS) in 29 sites, 33 sites, 32 sites, and 20 sites, respectively. After head elevation, flow-related signal changes were then observed in the IJV, SS, IPS, and CS in 107 sites (107/114, 93.9%). There was loss of signal (62/114, 54.4%), or decrease (39/114, 34.2%), increase (6/114, 5.3%), or no change (7/114, 6.1%) in the signal intensity, and flow related signals were more frequent on the left than on the right.

Conclusion: Flow-related signals in the dural sinuses on TOF MRA were decreased or disappeared by head elevation in 88.6% of the sites. Head elevation may help distinguish between pathologic and physiologic states.

Index terms

Diagnostic Imaging
Magnetic Resonance Imaging
Magnetic Resonance Angiography
Cerebral Angiography
Cerebral Veins

Received May 23, 2017

Revised August 1, 2017

Accepted September 29, 2017

*Corresponding author: Seung Kug Baik, MD
Department of Radiology, Research Institute of Convergence for Biomedical Science and Technology, Pusan National University Yangsan Hospital, Pusan National University School of Medicine, 20 Geumo-ro, Mulgeum-eup, Yangsan 50612, Korea.
Tel. 82-55-360-1834 Fax. 82-55-360-1848
E-mail: skbaik9@gmail.com

This is an Open Access article distributed under the terms of the Creative Commons Attribution Non-Commercial License (<http://creativecommons.org/licenses/by-nc/4.0>) which permits unrestricted non-commercial use, distribution, and reproduction in any medium, provided the original work is properly cited.

INTRODUCTION

In the normal population, time of flight magnetic resonance angiography (TOF MRA) images of the dural sinuses show isointense signal relative to the brain tissue. TOF MRA is only sensitive to arterial flow and effective to saturate venous flow

which runs craniocaudal direction and shows low velocity. Therefore, high signal intensity within a dural sinus may be considered abnormal (1-3). However, it is not infrequent to observe flow related signals in large venous structures such as internal jugular vein (IJV) and dural sinuses in healthy individuals (4-7), which may mimic pathologic conditions such as dural

arteriovenous fistula (AVF) (2, 4, 5, 8). The causes of frequent high signal intensities in the dural sinuses are complex and dependent on many factors, i.e., anatomical variations (compression by the left brachiocephalic vein), intrathoracic pressure, respiration, and others - some yet undefined (4, 7, 9, 10). These factors might cause reverse flow in the IJV and sigmoid sinus (SS), resulting in flow directed contralaterally via the inferior petrosal sinus (IPS) and cavernous sinus (CS) and contributing to this abnormal high signal intensity in dural sinuses (4, 5).

To clarify physiologic and pathologic flow related signal intensities, several studies have been performed on physiologic maneuvers (such as Valsalva or Müller's maneuver) and breathing maneuvers (7, 11). However, the results of these studies have not been entirely satisfactory. Different body positions have different patterns of cerebral venous outflow, and considerable variations in the cerebral venous outflow have been reported (1, 9). Positional MRI was recently introduced as a new machine to get images of cerebral venous outflow (1, 9, 12). However, despite the good results, this type of MR scanner remains largely unpopular. To our knowledge, no study so far has addressed the issue of the changes of sinus flow on conventional MRI by position.

The purpose of our study was to identify flow induced changes in signal intensity in the dural sinuses caused by changes in patient position, namely, head elevation. Our hypothesis was that physiologic signal intensity in the dural sinuses would change after head elevation, which may help distinguish between physiologic and pathologic flow related signals.

MATERIALS AND METHODS

Patient Selection and Study Design

Between September 2013 and March 2014, 52 patients with abnormal signals of dural sinuses who underwent additional MRA were included. The indications of the MR exam for enrolled patients were non-specific neurological symptoms such as headache. Patients were excluded on the following criteria: poor image quality, venous thrombosis, Moyamoya disease (3 patients), dural AVF (3 patients), and MR images obtained with different machines. To confirm Moyamoya disease and dural AVF, digital subtraction angiography (DSA) was performed. The cases consisted of 21 men and 31 women (mean age, 61.3 years; range, 28–86 years). This retrospective study was approved

by the ethics committee of Pusan National University Yangsan Hospital (05-2015-037), and the requirement for written informed consent was waived.

Image Acquisition

All MRI examinations were performed with 1.5T or 3T MR system (Avanto and Verio models; Siemens, Erlangen, Germany). TOF MRA scans were obtained in the supine position without head elevation and supine position with head elevation. If an educated technician had found an abnormal signal intensity on TOF, he or she notified the radiologist. Radiologists assessed flow related signal in the IJV, SS, IPS, and CS. After confirmation by the radiologist, we decided whether to perform head elevation. A designated soft pillow was used to perform head elevation. The degree of head elevation was 15–18°, which is based on Valdueza et al. (13) and was determined by measuring the angles on the picture archiving and communication system (PACS).

Both image sets were acquired using the same MR scanner (1.5T or 3T) and 12 channel head matrix coil [Avanto (Verio): length × width × height: 300 × 300 × 280 mm (330 mm)]. We performed our brain three-dimensional (3D) TOF MRA protocol in all cases by using the following sequences: repetition time, 30 ms; echo time, 3.3 ms; and a tilted optimized non-saturating excitation pulse with a central flip angle of 20°. Section thickness was 1 mm. A field of view of 180 × 180 mm was used with a matrix of 384 × 224. The sequence included a spatial saturation pulse above the acquisition slab to saturate the venous flow. The acquisition time was 4 min 37 s.

Image Analysis

A subjective grade of 1 to 3 was given for the magnitude of any signal in either sinus. The grade system was modified from Sakamoto et al. (14): grade 1 was equal to that of normal dural sinus signal on an MRA source and/or maximum intensity projection (MIP) images; grade 2 was greater than the normal dural sinus signal and lesser than the internal carotid artery signal on an MRA source and/or MIP images; and grade 3 was equal to that of internal carotid artery signal on an MRA source and/or MIP (Fig. 1). When flow related signal intensity of grade 2 or 3 was detected in the IJV, SS, IPS, and/or CS on TOF MRA with supine position, additional head elevation TOF MRA scans were

obtained. Two independent radiologists with 6 and 25 years of experience in neuroradiology assessed the overall images, respectively. They evaluated the changes in the signal intensity in the IJV, SS, IPS, and CS before and after head elevation as follows: loss, decrease, increase, and no change. Differences in the assessments of both readers were resolved by consensus. Source images of the TOF MRA and MIP images were used for the evaluation. Flow directions of both the sinuses and vein were determined

by visual inspection of 3D TOF MRA images and measuring the signal intensities in the most proximal and distal areas of the sinus and vein using variable sized regions of interest or subjective differences on PACS images. We also assessed the laterality of signals in the dural sinuses.

Statistical Analysis

The exact binomial test was used to compare flow related sig-

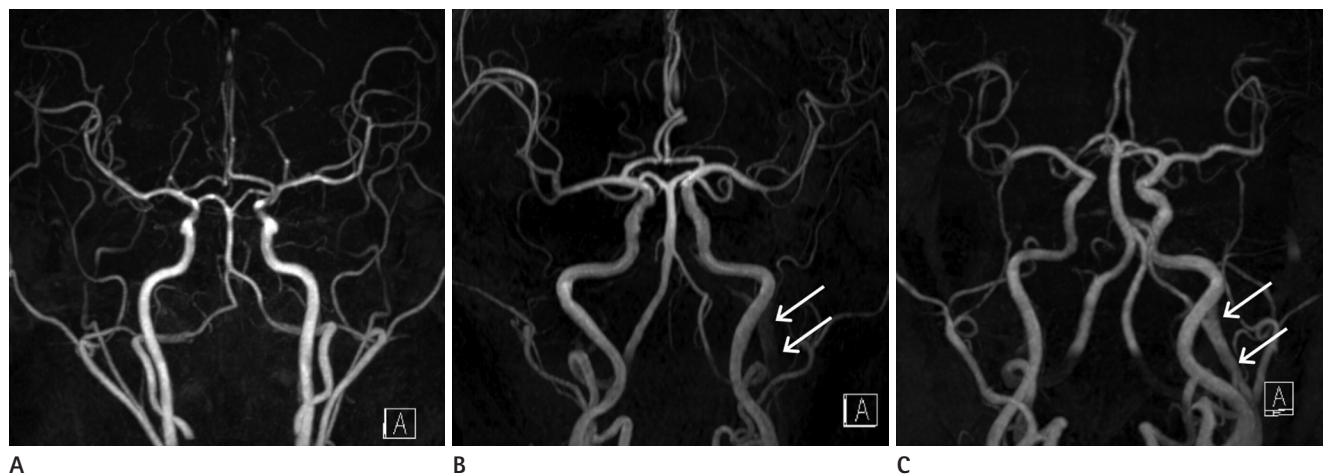


Fig. 1. TOF MRA images demonstrate subjective grade for the magnitude of any signal in left internal jugular vein.

A. Grade 1, equal to that of normal dural sinus signal on an MRA source and/or MIP images.

B. Grade 2, greater than the normal dural sinus signal and lesser than the internal carotid artery signal on an MRA source and/or MIP images (arrows).

C. Grade 3, equal to that of internal carotid artery signal on an MRA source and/or MIP (arrows).

MIP = maximum intensity projection, TOF MRA = time of flight magnetic resonance angiography

Table 1. Signal Intensity Change of Dural Sinuses by Head Elevation

Site	Number	Loss	Decrease	Increase	No Change	p-Value
IJV (29)						
Bilat.	9	4/9	5/9	0	0	0.004
Left	20	13/20	4/20	2/20	1/20	< 0.001
Right	0	0	0	0	0	NA
SS (33)						
Bilat.	11	7/11	3/11	0	1/11	0.012
Left	19	11/19	6/19	1/19	1/19	< 0.001
Right	3	2/3	0	0	1/3	1
IPS (32)						
Bilat.	9	3/9	5/9	0	1/9	0.040
Left	19	12/19	5/19	1/19	1/19	< 0.001
Right	4	1/4	2/4	0	1/4	0.625
CS (20)						
Bilat.	4	0	4/4	0	0	0.125
Left	12	7/12	4/12	1/12	0	< 0.001
Right	4	2/4	1/4	1/4	0	0.125
Total (114)	114	62/114 (54.4 %)	39/114 (34.2%)	6/114 (5.3%)	7/114 (6.1%)	< 0.001

Data represent the number of cases.

Bilat. = bilateral, CS = cavernous sinus, IJV = internal jugular vein, IPS = inferior petrosal sinus, NA = not applicable, SS = sigmoid sinus

nal changes between no head elevation TOF MRA and head elevation TOF MRA for the IJV, SS, IPS, and CS. Two way analysis of variance (ANOVA) was used to determine differences between sinuses (IJV, SS, IPS, and CS). All statistical analysis was done using a software package, IBM SPSS Statistics for Windows, Version 21.0 (IBM Corp., Armonk, NY, USA). A p -value < 0.05 was considered statistically significant.

RESULTS

Among the 52 patients, 24 patients underwent imaging in a 3T MR scanner (Verio 3T) and 28 patients underwent imaging in a 1.5T MR scanner (Avanto 1.5T). Signal intensity changes for the IJV, SS, IPS, and CS between the no head elevation and head elevation TOF MRA scans are summarized in Table 1.

In the 114 sites in the 52 TOF MRA images, flow related signals were seen in more than one dural sinus in 37 patients. After head elevation, loss (62/114 sites) or decrease (39/114 sites) in signals were observed in the IJV, SS, IPS, and CS (101/114, 88.6%) (Fig. 2). Signal changes in dural sinuses as increase (6/114, 5.3%), or no change (7/114, 6.1%) in intensity also noted. As compared to TOF MRA scans with no head elevation, those with head elevation showed significant signal changes in all dural sinuses and the IJV ($p < 0.001$). The flow related signal in IJV was seen

in 29 (55.8%) sites. After head elevation, the signal intensity in IJV was not seen in 17 of 29 (58.6%) sites. The decreased signal intensity in IJV after head elevation was noted in 9 of 29 (31%) sites. In SS, loss of flow related signal in 20 of 33 (60.6%) sites and decreased signal intensity in 9 of 33 (27.2%) sites after head elevation. In the cases of IPS, 16 of 32 (50%) cases of signal loss and 12 of 32 (37.5%) cases of signal decrease was demonstrated. The signal intensity in CS was not seen in 9 of 20 (45%) cases and decreased in 9 of 20 (45%) cases.

Table 2. Frequency and Laterality of Physiologic Signal According to Site

Site	Comparison	p -Value
IJV (29 sites)	Left (20) > Bilat. (9)	0.031
	Left (20) > Right (0)	0.001
	Bilat. (9) > Right (0)	0.001
SS (33 sites)	Left (19) > Bilat. (11)	0.100
	Left (19) > Right (3)	0.001
	Bilat. (11) > Right (3)	0.029
IPS (32 sites)	Left (19) > Bilat. (9)	0.044
	Left (19) > Right (4)	0.001
	Bilat. (9) > Right (4)	0.133
CS (20 sites)	Left (12) > Bilat. (4)	0.038
	Left (12) > Right (4)	0.038
	Bilat. (4) = Right (4)	1

Data represent the number of cases.

Bilat. = bilateral, CS = cavernous sinus, IJV = internal jugular vein, IPS = inferior petrosal sinus, SS = sigmoid sinus

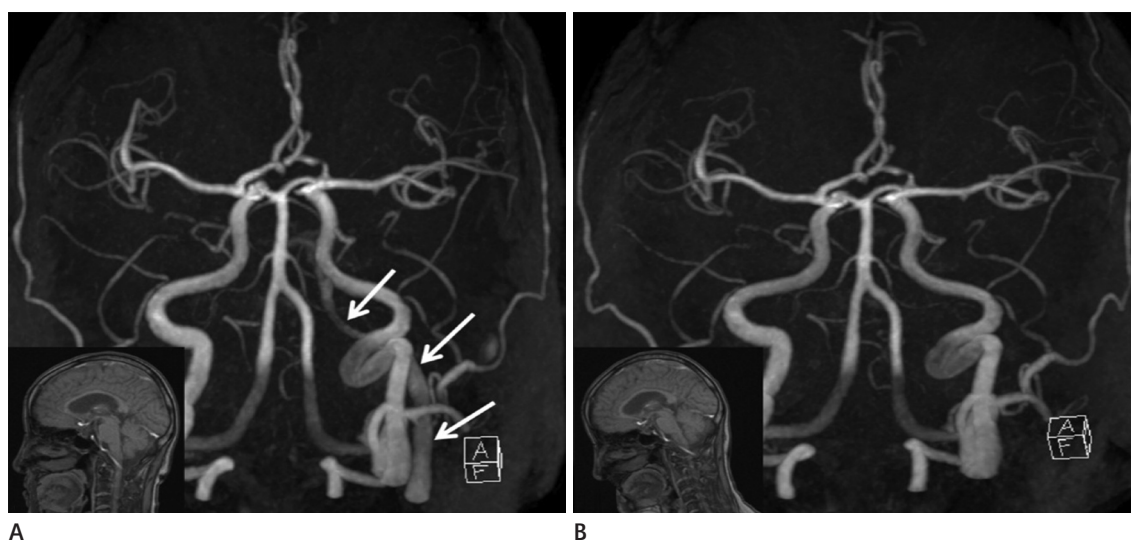

Fig. 2. Loss of flow-related signal on TOF MRA.

A. TOF MRA in supine position (small box in left lower image). The flow-related signals are seen on the left side of the internal jugular vein, sigmoid sinus, inferior petrosal sinus, and cavernous sinus (arrows) on TOF MRA.

B. TOF MRA in supine position with head elevation (small box in left lower image). After head elevation, the flow-related signals in the left dural sinuses disappear.

TOF MRA = time of flight magnetic resonance angiography

Generally, in the TOF MRA scans with no head elevation, the flow related signal in the dural sinuses gradually decrease in intensity toward the cephalic direction (38/52, 73.1%) or had no change in direction (14/52, 26.9%). Multiple hyperintense curvilinear structures or spots adjacent to or within a dural sinus were not observed in all cavernous, inferior petrosal, and sigmoid sinuses. Regarding frequency and laterality of physiologic signal according to site, flow related signals were more frequent on the left than on the right alone (Table 2). ANOVA showed no statistically significant difference in signal changes among the dural sinuses ($p = 0.114$).

DISCUSSION

The findings of our study indicate that head elevation TOF MRA provides the significant decrease or disappearance of physiologic signals of dural sinuses. When flow related high signal intensity in the dural sinuses is observed on TOF MRA images, a pathologic condition such as dural AVF may be considered (2, 3, 6). To confirm the diagnosis, further assessment with contrast-enhanced MRA or DSA is required. But, application of contrast-enhanced MRA or DSA to all cases with flow related signal in venous sinuses is not always clinically feasible, nor justified, for those studies are expensive and invasive. Also, DSA did not always show vascular lesions corresponding to flow related signals seen in dural sinuses, according to Watanabe et al. (4).

A plausible explanation for high signal in dural sinuses in patients without AVF is the retrograde flow due to postural compression of the left brachiocephalic vein (4, 5, 15, 16). Tanaka et al. (15) reported that, in the normal population, flow related high signal intensity in the IJV and SS is higher on the left side, and that compression by the left brachiocephalic vein was the main cause. Anatomically speaking, the left brachiocephalic vein runs a long, oblique course to unite with the right brachiocephalic vein posterior to the first sternocostal joint to form the superior vena cava. So, the left brachiocephalic vein can be easily compressed between the sternum and the aortic arch and/or right brachiocephalic artery (4, 7).

In the supine position, compression of the left brachiocephalic vein and subsequent reverse flow might cause flow related high signal intensity in the left IJV and sigmoid sinus.

In our study, flow related signals were significantly more fre-

quent on the left side and bilaterally than on the right side, which is consistent with the findings of Tanaka et al. (15). However, we also observed bilateral high signals and right sided high signals, and these findings are difficult to explain based only on the compression of the left brachiocephalic vein. It suggests that both IJV may not function properly in certain situations and that different cerebral venous blood outflow may operate by individuals. We also noted that the flow related signal intensity in dural sinuses gradually decreased toward the cephalic direction and showed no directional difference, which is consistent with the work of Watanabe et al. (4).

Several studies in the literature have attempted to verify physiologic change of cerebral venous blood outflow. The cerebral venous outflow and direction of dural sinuses can be affected by respiration (7, 11). Kudo et al. (7) reported that the signal intensities of sigmoid sinuses were affected by breath holding in about two thirds of the cases. Mehta et al. (11) said that both deep inspiratory breath-holding and deep expiratory breath-holding decreased dural sinus flow on phase contrast MR venography, and that this characterization may help clarify normal and pathologic cerebrovascular physiology. Although there is a good correlation between breath holding and physiologic signal intensity changes, breath-holding method is practically not applicable to TOF MRA imaging for illustrating physiologic change, because of its longer acquisition time compared to phase contrast MR venography.

Cerebral venous blood outflow takes different route depending on posture (1, 9, 10, 12, 13), therefore, the flow direction of dural sinuses and related signal intensities of them can also be affected by positional change. Most of the cerebral venous outflow ultimately collects into the transverse and sigmoid sinuses located at the base of the skull. In the supine position, cerebral venous outflow occurs primarily through the IJV, as seen on venous phase cerebral angiographies. However, several authors have shown that the internal and external vertebral venous systems represent the major outflow track of cerebral venous outflow in the erect position and that outflow through the IJV is absent or negligible in this position (17, 18).

Postural change of cerebral venous blood outflow has been difficult to demonstrate with conventional imaging modalities including ultrasonography, CT or MR, for those are performed in supine position in usual clinical setting. With recent advances

in positional MRI, MRI can be acquired in supine and erect positions, contributing to the study of the physiology of the cerebral venous blood outflow and its associated positional changes. Niggemann et al. (1, 9) showed that cerebral venous blood flow varies between the supine and erect postures using positional MRI, and those reports is in the same context with an animal study by Epstein et al. (10) which was operated on rhesus monkeys. Articles on the subject of positional venous MRA are scarce (1, 9, 10) because only a few dedicated MR imaging scanners are available. The magnetic field of positional MRI scanners typically yields lower image quality as compared with conventional MRI scanners; hence, the possibility of performing MRA is reduced.

Valdúeza et al. (13) examined the postural dependence of cerebral venous outflow using color coded duplex sonography with the body position at 0°, +15°, +30°, +45°, and +90°. They found that the largest decrease (78.6%) was measured between 0° and +15°. Only a slight postural change (15°, slight head elevation) was enough to make the largest change in the direction of the cerebral venous outflow, which may alter the flow related signal intensity in the dural sinus on TOF MRA. In this respect, we intended to identify the signal intensity change of dural sinus due to alteration in the venous outflow following slight head elevation, using widely available conventional MR systems.

To the best of our knowledge, flow related signal changes following slight head elevation have never been reported using conventional MR scanners to date. Observation of flow related signals using a conventional MR scanner has several advantages: 1) it is more objective than other image modalities such as ultrasonography, 2) it is easily applicable, utilizing already existing imaging systems, and 3) it has higher resolution than a positional MR scanner.

Our study has certain limitations. First, the sample size was small. Second, MR scanners with a small surface head coil (with a tight space) may not be available for MRA in the head elevation position. Third, 24 cases underwent imaging in a 3T MR scanner and 28 cases underwent imaging in a 1.5T MR scanner. However, the results in each group (Avanto 1.5T group and Verio 3T group) were similar to the overall results. Lastly, some cases showed no change (6.1%) or an increase (5.3%) in signals after head elevation. Further investigations for those patients were not taken into account in our work, because the high signals in dural sinuses were not considered as clinically relevant findings.

But, a future study is needed to illuminate the cause of these findings.

In conclusion, incidentally found high signal intensities of the IJV, SS, IPS, and CS on TOF MRA were decreased or disappeared by head elevation in 88.6% sites. Thus, TOF MRA with head elevation can be used as a safe and cost-effective screening tool for differentiating physiologic high signals from pathologic conditions such as dural AVE, obviating unnecessary contrast-enhanced MRA or DSA.

Acknowledgments

This work was supported by a 2-year Research Grant of Pusan National University.

REFERENCES

1. Niggemann P, Seifert M, Förg A, Schild HH, Urbach H, Krings T. Positional venous MR angiography: an operator-independent tool to evaluate cerebral venous outflow hemodynamics. *AJNR Am J Neuroradiol* 2012;33:246-251
2. Hirai T, Korogi Y, Hamatake S, Ikushima I, Sugahara T, Sigematsu Y, et al. Three-dimensional FISP imaging in the evaluation of carotid cavernous fistula: comparison with contrast-enhanced CT and spin-echo MR. *AJNR Am J Neuroradiol* 1998;19:253-259
3. Chen JC, Tsuruda JS, Halbach WW. Suspected dural arteriovenous fistula: results with screening MR angiography in seven patients. *Radiology* 1992;183:265-271
4. Watanabe K, Kakeda S, Watanabe R, Ohnari N, Korogi Y. Normal flow signal of the pterygoid plexus on 3T MRA in patients without DAVF of the cavernous sinus. *AJNR Am J Neuroradiol* 2013;34:1232-1236
5. Paksoy Y, Genç BO, Genç E. Retrograde flow in the left inferior petrosal sinus and blood steal of the cavernous sinus associated with central vein stenosis: MR angiographic findings. *AJNR Am J Neuroradiol* 2003;24:1364-1368
6. Ouanounou S, Tomsick TA, Heitsman C, Holland CK. Cavernous sinus and inferior petrosal sinus flow signal on three-dimensional time-of-flight MR angiography. *AJNR Am J Neuroradiol* 1999;20:1476-1481
7. Kudo K, Terae S, Ishii A, Omatsu T, Asano T, Tha KK, et al. Physiologic change in flow velocity and direction of dural venous

- sinuses with respiration: MR venography and flow analysis. *AJNR Am J Neuroradiol* 2004;25:551-557
8. Cornelius R. *CCF: imaging evaluation*. In Tomsick TA, ed. *Carotid cavernous fistula*. Cincinnati, OH: Digital Educational Publishing, 1997:23-31
9. Niggemann P, Kuchta J, Grosskurth D, Beyer HK, Krings T, Reinges M. Position dependent changes of the cerebral venous drainage--implications for the imaging of the cervical spine. *Cent Eur Neurosurg* 2011;72:32-37
10. Epstein HM, Linde HW, Crampton AR, Ciric IS, Eckenhoff JE. The vertebral venous plexus as a major cerebral venous outflow tract. *Anesthesiology* 1970;32:332-337
11. Mehta NR, Jones L, Kraut MA, Melhem ER. Physiologic variations in dural venous sinus flow on phase-contrast MR imaging. *AJR Am J Roentgenol* 2000;175:221-225
12. Alperin N, Hushek SG, Lee SH, Sivaramakrishnan A, Lichtor T. MRI study of cerebral blood flow and CSF flow dynamics in an upright posture: the effect of posture on the intracranial compliance and pressure. *Acta Neurochir Suppl* 2005;95:177-181
13. Valdueza JM, von Münster T, Hoffman O, Schreiber S, Einhäupl KM. Postural dependency of the cerebral venous outflow. *Lancet* 2000;355:200-201
14. Sakamoto M, Taoka T, Iwasaki S, Nakagawa H, Fukusumi A, Takayama K, et al. Paradoxical parasellar high signals resembling shunt diseases on routine 3D time-of-flight MR angiography of the brain: mechanism for the signals and differential diagnosis from shunt diseases. *Magn Reson Imaging* 2004;22:1289-1293
15. Tanaka T, Uemura K, Takahashi M, Takehara S, Fukaya T, Tokuyama T, et al. Compression of the left brachiocephalic vein: cause of high signal intensity of the left sigmoid sinus and internal jugular vein on MR images. *Radiology* 1993;188:355-361
16. Uchino A, Nomiya K, Takase Y, Nakazono T, Tominaga Y, Imaizumi T, et al. Retrograde flow in the dural sinuses detected by three-dimensional time-of-flight MR angiography. *Neuroradiology* 2007;49:211-215
17. San Millán Ruiz D, Gailloud P, Rüfenacht DA, Delavelle J, Henry F, Fasel JH. The craniocervical venous system in relation to cerebral venous drainage. *AJNR Am J Neuroradiol* 2002;23:1500-1508
18. Gisolf J, van Lieshout JJ, van Heusden K, Pott F, Stok WJ, Karemaker JM. Human cerebral venous outflow pathway depends on posture and central venous pressure. *J Physiol* 2004;560(Pt 1):317-327

자기공명영상 혈관촬영술에서 보이는 경막정맥동의 혈류 연관 신호: 두부거상에 의한 변화 관찰

노지은¹ · 백승국^{1,2*} · 염정아¹ · 김영수³ · 정희석¹ · 윤창효⁴ · 한준희⁵

목적: 흐름시간 자기공명영상 혈관촬영술(time of flight magnetic resonance angiography; 이하 TOF MRA)에서 정상 경막정맥동에 혈류와 연관된 신호가 종종 관찰된다. 이 연구는 환자의 자세 변화에 의해 경막정맥동의 신호 강도 변화를 확인하고자 한다.

대상과 방법: 바로 누운 자세의 두부 TOF MRA에서 경막정맥동에 혈류와 연관된 신호를 보인 52명의 환자에서, 두부거상을 한 상태에서 두부 TOF MRA를 재시행하여 경막정맥동에 나타나는 혈류와 연관된 신호의 변화를 분석하였다.

결과: 바로 누운 자세의 두부 TOF MRA에서 혈류와 연관된 신호는 114부위의 경막정맥동(52명의 환자)에서 관찰되었다. 경정맥에서 29부위, 구불정맥동에서 33부위, 아래바위정맥굴에서 32부위, 해면정맥동에서 20부위가 각각 관찰되었다. 두부거상 후의 두부 TOF MRA에서 신호의 변화는 107부위(107/114, 93.9%)에서 관찰되었고, 신호의 소실은 54.4%(62/114), 신호 감소는 34.2%(39/114), 신호 증가는 5.3%(6/114), 신호변화가 없는 경우는 6.1%(7/114)에서 관찰되었다. 두부거상 시 나타나는 신호의 변화는 오른쪽보다 왼쪽에서 유의하게 많이 나타났다.

결론: TOF MRA에서 관찰되는 경막정맥동의 혈류 연관 신호는 88.6%(101/114)에서 두부 거상에 의해 감소하거나 소실되었다. 이와 같은 현상은 경막정맥동에 나타나는 신호 중 정상적으로 나타나는 것과 병적으로 나타나는 것을 구별하는 방법으로 사용될 수 있다고 사료된다.

부산대학교 의과대학 양산부산대학교병원 ¹영상의학교실, ³신경외과학교실,

²부산대학교 의과대학 양산부산대학교병원 의생명융합연구소, ⁴경북대학교 의과대학 경북대학교병원 신경과학교실,

⁵한림대학교 금융정보통계학과