



Retention of Gadolinium in Cerebrospinal Fluid and Decreased Renal Function: A Case Report

뇌척수액 내에 가돌리늄 잔존과 신장기능 저하: 증례 보고

Kyeong Sik Park, Young Jin Heo, MD*, Hae Woong Jeong, MD, Jin Wook Baek, MD, Hye Jung Choo, MD, Cheon Sik Jung

Department of Radiology, Busan Paik Hospital, Inje University, Busan, Korea

A gadolinium-based contrast is the preferred agent when differentiating acute neurological diseases. Since the renal route is the main pathway for excretion of gadolinium chelates, prolonged extracellular distribution of gadolinium has previously been reported in dialysis-dependent patients. Hence, gadolinium-based contrast agents are used cautiously in patients with known renal disease. Retention of gadolinium manifests as increased fluid-attenuated inversion recovery (FLAIR) signal intensity in the subarachnoid space, leading to diagnostic errors. Here, we describe a patient who presented to our emergency room with an acute cerebral infarction. Enhanced brain magnetic resonance imaging performed 2 days later revealed high signal intensity in the cerebrospinal fluid spaces on follow-up FLAIR images.

Index terms

Gadolinium
Subarachnoid Space
Cerebrospinal Fluid
Renal Insufficiency

Received May 31, 2017

Revised June 21, 2017

Accepted July 15, 2017

*Corresponding author: Young Jin Heo, MD
Department of Radiology, Busan Paik Hospital, Inje University, 75 Bokji-ro, Busanjin-gu, Busan 47392, Korea.
Tel. 82-51-890-6549 Fax. 82-51-896-1085
E-mail: youngjin726@hanmail.net

This is an Open Access article distributed under the terms of the Creative Commons Attribution Non-Commercial License (<http://creativecommons.org/licenses/by-nc/4.0>) which permits unrestricted non-commercial use, distribution, and reproduction in any medium, provided the original work is properly cited.

INTRODUCTION

Gadolinium-based contrast agents are extensively used in magnetic resonance imaging (MRI) of the brain. Occasionally, these agents are associated with minimal neurotoxicity. However, several reports of increased signal intensity in the subarachnoid space have been reported in patients with end-stage renal failure due to the deposition of gadolinium in the cerebrospinal fluid (CSF), following the use of a gadolinium chelate as the contrast medium. Here, we report a patient admitted to our emergency room with an acute cerebral infarction, whose enhancement brain MRI revealed high signal intensity in the CSF spaces on follow-up fluid-attenuated inversion recovery (FLAIR) images, which could have led to a misdiagnosis.

CASE REPORT

An 81-year-old woman was admitted to our emergency room with a 4-hour history of aphasia and right hemiparesis. Her medical history was significant for diabetes and hypertension, for which she was undergoing treatment. She underwent brain MRI with gadolinium-based contrast medium. During the study, 30 mL of gadopentetate dimeglumine (Uniray, Dongkook Pharmaceutical Co., Ltd, Seoul, Korea) was administered, to obtain perfusion MRI and contrast-enhanced neck MR angiography. Diffusion and perfusion MRI revealed multifocal acute infarctions in the left frontal lobe, basal ganglia, and insular cortex, with diffusion-perfusion mismatch (Fig. 1A-C). Magnetic resonance angiography revealed stenosis in the left M1 and M2 segments. At the time of admission, the patient had a creatinine

level of 2.66 mg/dL and an estimated glomerular filtration rate of 16.3 mL/min/1.73 m². At our hospital, if there is a suspicion of acute cerebral infarction, MRI is performed before obtaining the creatinine test result; hence, we were unaware of the high creatinine level of the patient at the time of administering the contrast medium. Intra-arterial thrombectomy was attempted for a stenosis in the left middle cerebral artery, but recanalization of the vessel was not possible due to severe steno-occlusive le-

sions in both common femoral arteries. Therefore, the patient was admitted to the stroke unit for observation. Follow-up MRI performed 2 days later showed markedly increased signal intensity in the CSF space on T1 weighted and FLAIR images (Fig. 1D, E). Increased signal intensity was also present in the aqueous and vitreous humor of both eyes. Diffuse subarachnoid hemorrhage or meningitis were considered as the etiology, but neither was consistent with the clinical presentation. Subse-

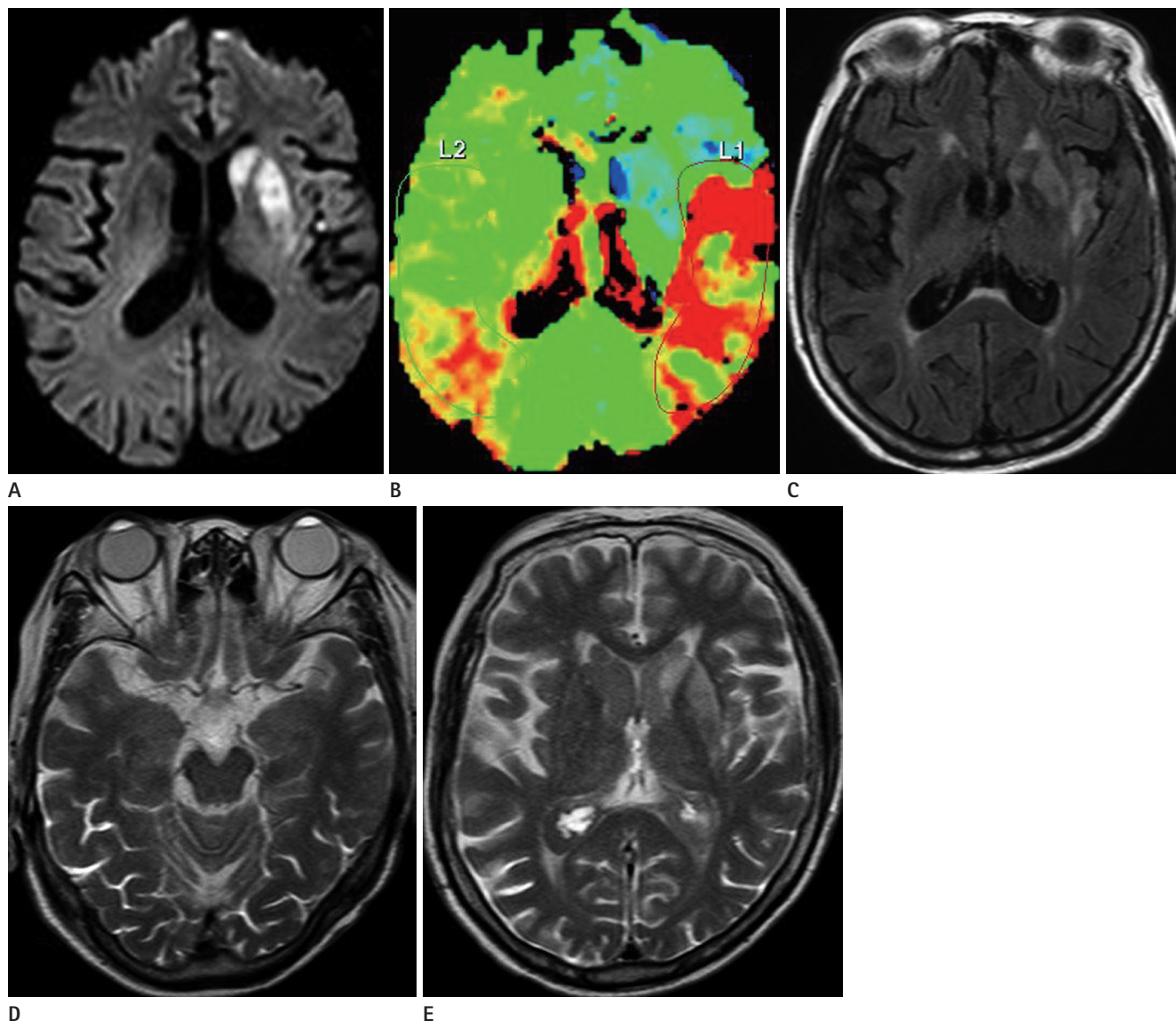


Fig. 1. An 81-year-old woman with acute cerebral infarction.

A. A diffusion-weighted image shows lesions with diffusion restriction in the left basal ganglia.

B. Perfusion-weighted magnetic resonance imaging shows increased time to peak in left middle cerebral artery territory, suggesting acute infarction with perfusion-diffusion mismatch.

C. Fluid-attenuated inversion recovery image shows multifocal hyperintense lesions in the left basal ganglia and insular cortex, but normal signal intensity in the cerebrospinal fluid spaces.

D, E. Two-day follow-up axial fluid-attenuated inversion recovery images (**D, E**) show high signal intensity in the bilateral eye globes, subarachnoid spaces, and ventricular system.

quently, we considered the possibility that presence of gadolinium in the CSF was caused by decreased renal function, due to which the contrast agent could not be cleared from the extracellular compartment and was excreted into the CSF spaces. At follow-up examination, the patient's creatinine level had increased to 3.52 mg/dL, and her estimated glomerular filtration rate had decreased to 11.6 mL/min/1.73 m². Dialysis to reduce her serum creatinine level was planned, but the patient succumbed to multiorgan failure before this could be commenced.

DISCUSSION

Gadolinium chelates are generally considered safe and are widely used as contrast agents for MRI. Increased use of contrast-enhanced MRI has generated more interest in the side effects caused by contrast agents. Patients with renal dysfunction are more likely to experience toxicity than those with normal renal function, because of their decreased ability to eliminate gadolinium. Further, several reports on the accumulation of gadolinium in patients with renal insufficiency, have presented the presence of high signal intensity in the CSF spaces on FLAIR images (1-3).

Gadolinium is an extracellular contrast medium, and its elimination is mainly via the glomerular route, which is likely to be affected by renal impairment (4). In patients with normal renal function, the mean half-life of gadolinium was reported to be 1.5 hours, but increased to 34.3 ± 22.9 hours in patients with severe renal insufficiency who received gadolinium 0.1 mmol/kg (4). Another paper reports a patient with renal impairment, in whom the contrast medium was retained for more than 2 weeks after injection (3). A prolonged elevated concentration increases the availability of gadolinium in plasma (2), and its persistence in the circulation leads to release of free gadolinium. This free gadolinium has been reported to cause neurotoxicity (5). The mechanism via which gadolinium enters the CSF spaces remains unclear. The choroid plexus in the brain and ciliary body of the eye contain fenestrated capillary endothelium that could be the entry site for contrast medium (2). This may explain why FLAIR hyperintensity was observed in both ocular globes in our patient. Further, circumventricular organs, including the pineal body, neurohypophysis, and area postrema, normally lack tight junctions in their capillary epithelium, and allow gadolinium-based contrast medium to cross the blood-brain

barrier via an osmotic gradient (2). Resolution of the increased signal intensity in the CSF after dialysis suggests that impaired renal functions can result in the accumulation of gadolinium.

Since FLAIR high signal intensity in the CSF could also indicate other afflictions, such as subarachnoid hemorrhage, meningitis, hyperoxygenation therapy, CSF flow artifact, and motion artifact (6), it could be a source of diagnostic confusion. Retention of gadolinium should be considered as a cause of high FLAIR signal intensity in patients with renal failure. A gradual decrease in renal function is helpful in differentiating from other diseases, such as hemorrhage, infection, and hyperoxygenation therapy. T2* gradient-recalled echo imaging (particularly susceptibility weighted image) could be helpful to exclude hemorrhage. T1-weighted image is also helpful to differentiate gadolinium from other neurologic diseases, because of the T1 shortening effect of gadolinium. If accumulation of gadolinium is confirmed, it should be removed by peritoneal dialysis or hemodialysis (2).

The major limitation of our study is the lack of inclusion of a mass spectrometry or CSF study to demonstrate changes in gadolinium levels in the serum and CSF. The correlation between MRI findings and these indices need to be further investigated. Recognition of these unusual features of gadolinium retention may prevent diagnostic errors and unnecessary additional diagnostic examinations to exclude other causes of increased CSF signal intensity (2). Immediate dialysis is recommended for patients who are found to have renal insufficiency after MRI of the brain using contrast medium.

REFERENCES

1. Ong EM, Yeh IB. High signal in the cerebrospinal fluid following prior gadolinium administration in a patient with renal impairment. *Singapore Med J* 2007;48:e296-e298
2. Rai AT, Hogg JP. Persistence of gadolinium in CSF: a diagnostic pitfall in patients with end-stage renal disease. *AJNR Am J Neuroradiol* 2001;22:1357-1361
3. Lev MH, Schaefer PW. Subarachnoid gadolinium enhancement mimicking subarachnoid hemorrhage on FLAIR MR images. Fluid-attenuated inversion recovery. *AJR Am J Roentgenol* 1999;173:1414-1415
4. Tombach B, Bremer C, Reimer P, Schaefer RM, Ebert W, Geens V, et al. Pharmacokinetics of 1M gadobutrol in patients

- with chronic renal failure. *Invest Radiol* 2000;35:35-40
5. Maramattom BV, Manno EM, Wijidicks EF, Lindell EP. Gadolinium encephalopathy in a patient with renal failure. *Neurology* 2005;64:1276-1278
 6. Stuckey SL, Goh TD, Heffernan T, Rowan D. Hyperintensity in the subarachnoid space on FLAIR MRI. *AJR Am J Roentgenol* 2007;189:913-921

뇌척수액 내에 가돌리늄 잔존과 신장기능 저하: 증례 보고

박경식 · 허영진* · 정해웅 · 백진욱 · 추혜정 · 정천식

뇌 MRI에서는 급성 신경계 질환들의 감별하는 경우에 Gadolinium 기반 조영제의 사용이 선호된다. 신장 경로가 가돌리늄 킬레이트의 배설을 위한 주요 경로이며, 투석을 하는 환자에서 가돌리늄의 오랜 세포 외 분포는 이전에 보고되었다. 따라서 Gadolinium 기반 조영제는 알려진 신장 질환이 있는 환자에게는 조심스럽게 사용된다. 가돌리늄의 축적은 지주막 공간에서 유체 감쇠 반전 회복 신호 강도가 증가하여 진단적 오류를 일으킬 수 있다. 본 증례 보고에서는 급성 뇌경색으로 응급실에 내원하여 조영증강 뇌 MRI를 시행한지 2일 후에 유체 감쇠 반전 회복 영상에서 뇌척수액 공간의 신호증가를 보였던 환자를 보고하고자 한다.

인제대학교 부산백병원 영상의학과