



Synovitis, Acne, Pustulosis, Hyperostosis, and Osteitis Syndrome: A Case of Spine, Pelvis, and Anterior Chest Wall Involvement, with Overlooked Plantar Pustulosis

SAPHO 증후군: 척추, 골반, 전흉벽의 골병변과 피부 병변이 동반된 증례

Hyun Soo Kim, MD¹, Soh Yong Jeong, MD¹, Sujin Lee, MD¹, In-Woon Baek, MD², Jeongmi Park, MD^{1*}

Departments of ¹Radiology, ²Internal Medicine, Yeouido St. Mary's Hospital, College of Medicine, The Catholic University of Korea, Seoul, Korea

Synovitis, acne, pustulosis, hyperostosis, and osteitis (SAPHO) syndrome is an inflammatory clinical condition with aseptic bone lesions and characteristic skin manifestations. A 63-year-old woman presented with vague musculoskeletal symptoms including chronic buttock pain. The clinical work-up revealed multiple spine and osteoarticular involvement. Multilevel bone marrow edema and cortical erosions involving the spine, asymmetric sacroiliitis, and osteosclerosis of the sternoclavicular joint were consistent with a diagnosis of SAPHO syndrome. Considering SAPHO syndrome in the differential diagnosis, subsequent skin inspection revealed plantar pustulosis. Despite the unique feature of accompanying skin and skeletal lesions, skin lesions could be overlooked if not suspected.

Index terms

Acquired Hyperostosis Syndrome
Spiral Cone-Beam Computed Tomography
Magnetic Resonance Imaging

INTRODUCTION

Synovitis, acne, pustulosis, hyperostosis, and osteitis (SAPHO) syndrome is an inflammatory clinical condition featuring aseptic bone lesions and characteristic skin manifestations (1). The association between skeletal lesions and skin lesions was first reported in 1961 (2). Subsequently, various terms were used to describe the disease entity until introduction of the SAPHO acronym (1). The age at presentation ranges from childhood to adulthood and the clinical and imaging features include a wide spectrum (3). Prevalence is estimated at no greater than 1 in 10000, which is probably an underestimate (4). The low incidence rate as well as the wide range of etiology and manifestations of this syndrome can complicate the diagnosis.

Received July 25, 2016

Revised September 13, 2016

Accepted December 19, 2016

*Corresponding author: Jeongmi Park, MD

Department of Radiology, Yeouido St. Mary's Hospital,
College of Medicine, The Catholic University of Korea,
10 63-ro, Yeongdeungpo-gu, Seoul 07345, Korea.

Tel. 82-2-3779-2037 Fax. 82-2-783-5288

E-mail: jmpark@catholic.ac.kr

This is an Open Access article distributed under the terms of the Creative Commons Attribution Non-Commercial License (<http://creativecommons.org/licenses/by-nc/4.0>) which permits unrestricted non-commercial use, distribution, and reproduction in any medium, provided the original work is properly cited.

Herein, we reported a case of SAPHO syndrome showing typical radiologic features. This case report was approved by our Institutional Review Board and the requirement for the patient's informed consent was waived.

CASE REPORT

A 63-year-old woman visited our institute with chronic right buttock pain. She had a long history of vague pain around the lower back for about 30 years and had already visited a few other hospitals. She was taking oral analgesics and tender point injections, but the symptom was intractable.

Blood testing revealed elevated erythrocyte sedimentation rate (73 mm/hour) and C-reactive protein (16.86 mg/L), with other

results in the normal range. She underwent a general work-up including conventional radiographs of spine and pelvis. The radiographs revealed multifocal sclerotic lesions in the vertebral bodies and right ilium near the sacroiliac joint (Fig. 1A, B).

For further evaluation, magnetic resonance imaging (MRI) of the thoracic and lumbar spine was conducted. In the lumbar spine, L1, L2 and L3 vertebral bodies showed high-signal intensities in a fat-saturated T2 weighted image and low-signal intensities in a T1 weighted image, which suggested bone marrow edema (Fig. 1C). The lumbar vertebral body lesions were confined to the anterior corner of the vertebral bodies. The corner lesions showed MRI findings that were similar to those of Romanus lesion found with spondyloarthropathies including ankylosing spondylitis. But, unlike spondyloarthropathies, these corner lesions progressed to adjacent vertebral end plates and involved contigu-

ous vertebrae. Prevertebral soft tissue thickening was present, which also lessened the possibility of spondyloarthropathies.

In the thoracic spines, cortical erosions and subchondral sclerosis were seen in T5, T6 and T7 vertebrae combined with prevertebral soft tissue thickening with enhancements (Fig. 1D), which resembled infection. But, unlike infection, disc involvement, abscess formation, epidural involvement, or large paravertebral soft-tissue masses were absent.

The broad spectrum of imaging features involving various sites strongly suggested SAPHO syndrome. In addition, multiple hot uptake was evident on bone scintigraphy, corresponding with CT and MRI findings. Moreover, marked uptake was apparent in the manubrium, bilateral sternoclavicular joints, and adjacent clavulae known as the bullhead sign (Fig. 1E). Although the bullhead sign strongly indicated SAPHO, bone biop-

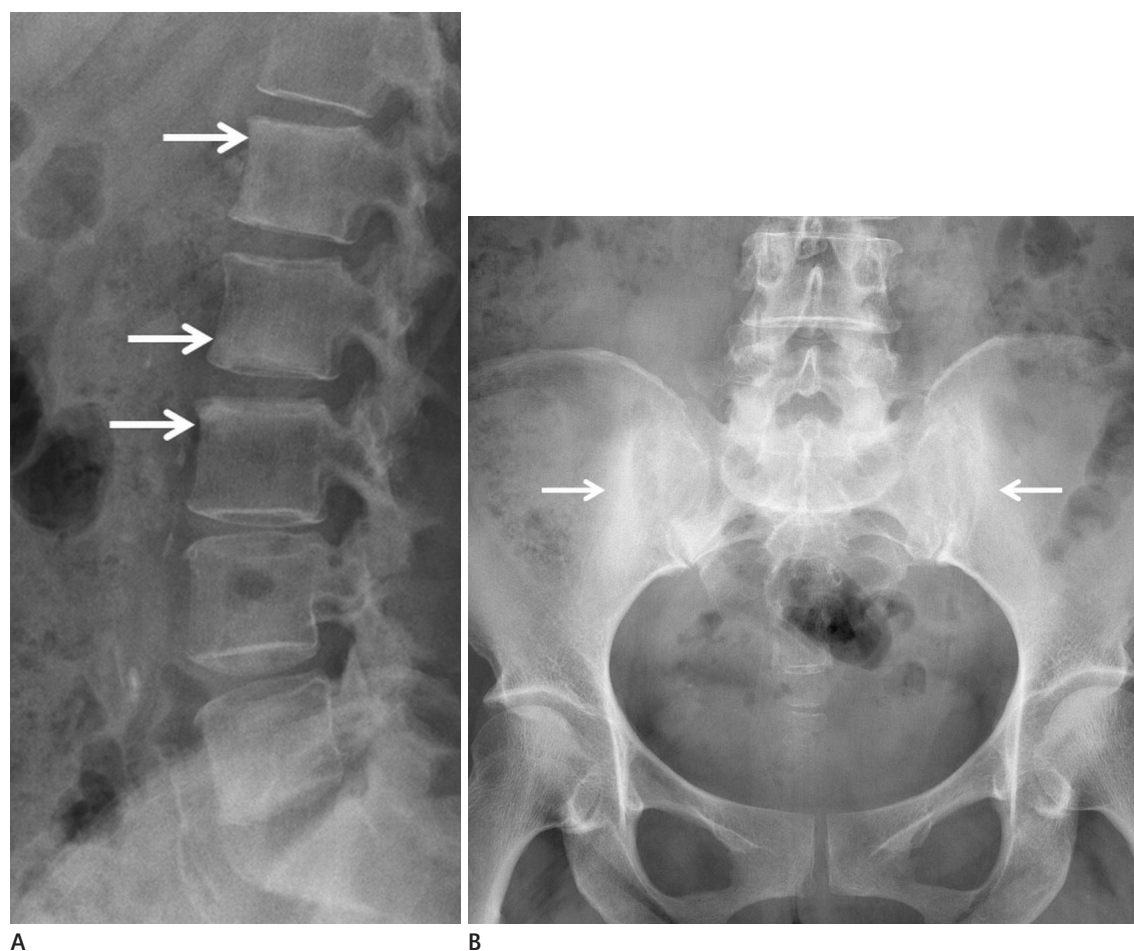


Fig. 1. SAPHO syndrome in 63-year-old female patient.

(A) Lumbar spine lateral and **(B)** pelvis anterior-posterior radiographs show ill-defined sclerosis at anterior aspect of L1, L2, L3 vertebral bodies and iliac side of bilateral sacroiliac joint (white arrows).

SAPHO = synovitis, acne, pustulosis, hyperostosis, and osteitis

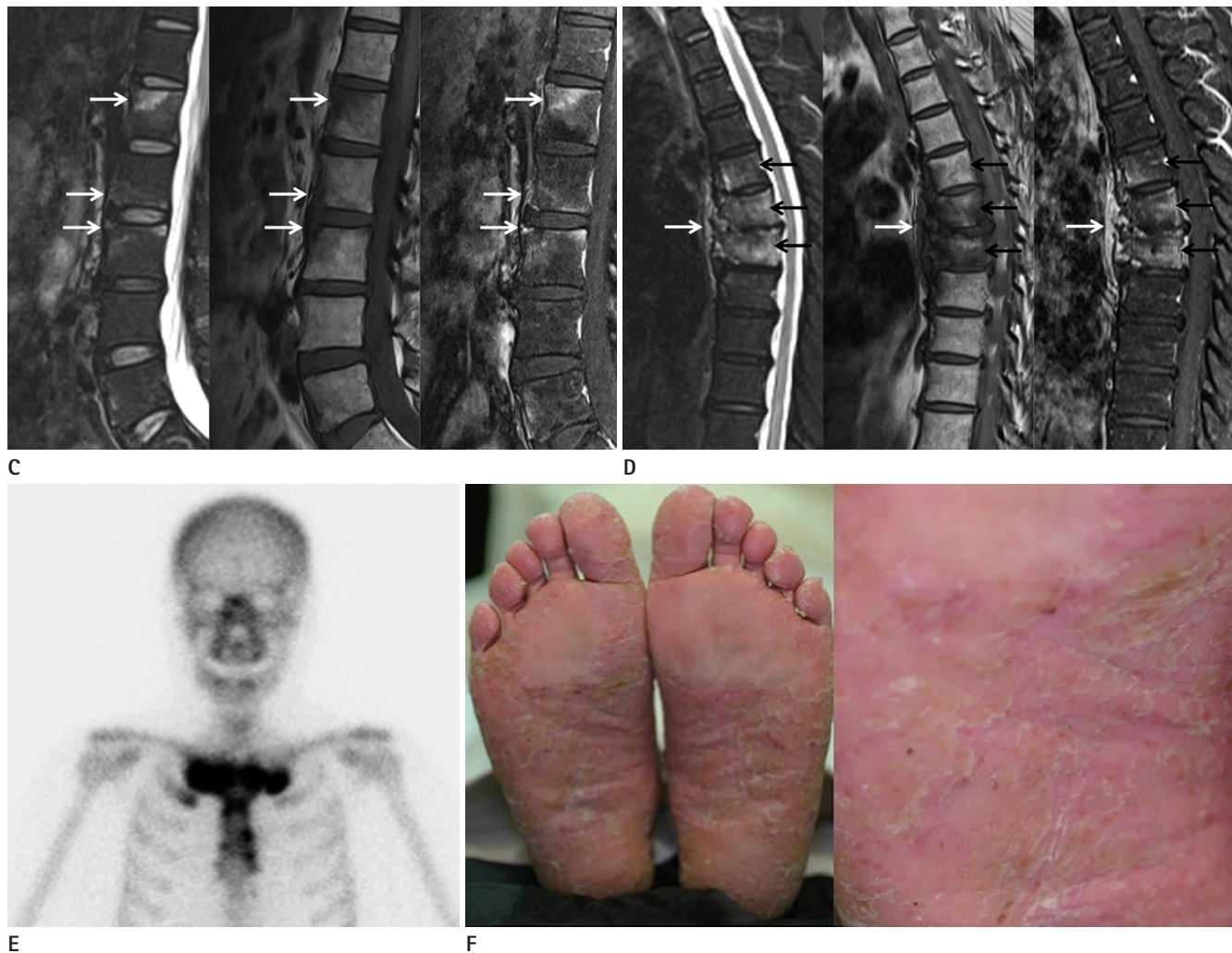


Fig. 1. SAPHO syndrome in 63-year-old female patient.

C. Sagittal MR image of the lumbar spine. Fat saturated T2 weighted image (left) shows high-signal intensities within L1, L2 and L3 vertebral bodies (white arrows). T1 weighted image (middle), and contrast enhanced fat saturated T1 weighted image (right) show low-signal intensities and mild enhancement in the above-mentioned vertebral sites (white arrows). Note that the involvement is confined to the anterior corner of the vertebral body, which is one of main radiological manifestations of SAPHO. The disc signals and intervertebral disc spaces are relatively spared, thus lowering the possibility of spondylitis.

D. Sagittal MR image of the thoracic spine. Fat saturated T2-weighted image (left), T1-weighted image (middle), and contrast enhanced T1-weighted image (right) reveal diffuse bone marrow edema and cortical erosions of consecutive levels of T5, T6, and T7 vertebrae (black arrows). Non-specific spondylodiscitis is a common radiologic finding of SAPHO. Prevertebral soft tissue thickening with enhancements (white arrows) and disc space narrowing mimic infectious spondylodiscitis. However, absence of abscess formation or epidural involvement indicate a low possibility of infection.

E. Anterior image of bone scintigraphy shows marked uptake in the manubrium, bilateral sternoclavicular joints known as the bullhead sign. Subtle uptake is also noted in the adjacent first rib.

F. Clinical photograph of both feet shows planar pustulosis.

SAPHO = synovitis, acne, pustulosis, hyperostosis, and osteitis

sy from the lumbar and thoracic vertebrae was done to confirm the diagnosis. Culture of the specimen was negative for microorganisms and pathology revealed only fibrous degeneration.

Skin inspection conducted immediately after suspecting SAPHO syndrome from radiologic findings revealed pustulosis of both feet, which was present for 9 years (Fig. 1F). The patient was

regularly visiting the dermatologist and using topical steroids; however, the pustulosis was never correlated with the chronic buttock pain prior to evaluation of the radiologic findings. The patient was started on steroid therapy and her symptoms are now under control.

DISCUSSION

Clinical features of SAPHO are still unclear due to the rarity of reported cases. Prevalence of SAPHO has been estimated at no greater than 1 in 10000, which is possibly an underestimate due to low awareness of the disease (4). It can occur in patients with a wide age range from childhood to adulthood (5), and is characterized by repeated episodes of remission and recurrence (6). Symptoms can vary, but patients mostly complain of musculoskeletal symptoms including pain, tenderness, and swelling. Multiple sites of involvement in different osteoarticular sites are common. The anterior chest wall and spine are the most commonly affected sites in adults (3). Mild fever can be present but other systemic manifestations are rare. Laboratory results are usually in the normal range, except for possible elevation in the Erythrocyte sedimentation rate and C-reactive protein level (6).

Skin manifestations might not be present, which can make diagnosis even more challenging. If present, the skin manifestations appear as severe acne and/or pustulosis of palms and soles (3). The skin lesions may occur before, simultaneously, or after the onset of skeletal symptoms. Clinicians should be aware that the skin and osteoarticular manifestations of SAPHO syndrome do not necessarily co-exist (7).

Osteoarticular manifestations include synovitis, hyperostosis, osteitis, arthropathy, and enthesopathy (3). Hyperostosis and osteitis is characterized by increased sclerosis of the bone involving the cortex and medulla, respectively (3). Hyperostosis appears radiologically as cortical thickening and narrowing of the medullary cavity, whereas osteitis appears as increased sclerosis of the medullary cavity (8). Arthritis is associated with joint space narrowing, periarticular osteopenia, and bone erosions (8). It usually affects axial joints, such as sternoclavicular joints, sacroiliac joint, costochondral joints, and symphyses (9).

The anterior chest wall is the most common site of involvement in adults (9). In the early stage, it can be evident as soft tissue swelling around the costoclavicular ligaments. However, in the late stage, hyperostosis, osteosclerosis, and hypertrophy of the medial ends of clavicles is evident (8). These lesions characteristically show hot uptake on bone scintigraphy and may resemble the contour of bull's head, but this finding is not entirely definitive (10).

The spine is the second most commonly involved site in pa-

tients of all ages (6). The six main radiological manifestations include vertebral body corner lesions, spondylodiscitis, osteodestructive lesions, osteosclerotic vertebral lesions, paravertebral ossification, and sacroiliitis (3). In the present case, vertebral body corner lesions, spondylodiscitis, osteodestructive lesions, osteosclerotic vertebral lesions, and sacroiliitis were present.

SAPHO can be difficult to diagnose because it can involve any skeletal site and has variable appearances on imaging (4). Diagnostic criteria for SAPHO have been proposed by several authors, but none have been validated. In 1988, Benhamou et al. (1) proposed that, after excluding an infective cause, palmo-plantar keratoderma, diffuse idiopathic skeletal hyperostosis, and manifestations of retinoid therapy, the presence of only one of the four inclusion criteria is sufficient for the diagnosis of SAPHO. Inclusion criteria include osteoarticular manifestations of acne conglobata, acne fulminans, or hirsutism suppurativa, (2) osteoarticular manifestations of palmoplantar pustulosis, (3) hyperostosis involving either the anterior chest wall, spine, or limbs with or without dermatosis, and (4) recurrent multifocal chronic osteomyelitis with or without dermatosis (1). Kahn updated these criteria at the 67th annual scientific meeting of the American College of Rheumatology in 2003. Suggested inclusion criteria are (1) bone and/or joint involvement associated with palmo-plantar pustulosis and pustular psoriasis, (2) bone and/or joint involvement associated with severe acne, (3) isolated sterile hyperostosis/osteitis in adults, (4) chronic recurrent multifocal osteomyelitis in children and, (5) bone and/or joint involvement associated with chronic bowel diseases. Exclusion criteria are (1) infectious osteitis, (2) tumoral conditions of bone and, (3) non-inflammatory condensing lesions of bone. Meeting one criteria is sufficient for the diagnosis of SAPHO. In our case, both criteria were met because plantar pustulosis and osteoarticular manifestations were present at the same time. However the diagnosis can be difficult in patients with a solitary symptomatic skeletal lesion without skin lesions, which is a common presentation of SAPHO. The time interval between the onset of skin and osteoarticular manifestations can be of up to 40 years (9). In such cases, the radiologist needs to take an active role in considering the diagnosis, since awareness of the imaging features facilitates early diagnosis and initiating appropriate treatment.

REFERENCES

1. Benhamou CL, Chamot AM, Kahn MF. Synovitis-acne-pustulosis hyperostosis-osteomyelitis syndrome (SAPHO). A new syndrome among the spondyloarthropathies? *Clin Exp Rheumatol* 1988;6:109-112
2. Windom RE, Sanford JP, Ziff M. Acne conglobata and arthritis. *Arthritis Rheum* 1961;4:632-635
3. Depasquale R, Kumar N, Lalam RK, Tins BJ, Tyrrell PN, Singh J, et al. SAPHO: what radiologists should know. *Clin Radiol* 2012;67:195-206
4. Magrey M, Khan MA. New insights into synovitis, acne, pustulosis, hyperostosis, and osteitis (SAPHO) syndrome. *Curr Rheumatol Rep* 2009;11:329-333
5. Van Doornum S, Barraclough D, McColl G, Wicks I. SAPHO: rare or just not recognized? *Semin Arthritis Rheum* 2000;30:70-77
6. Colina M, Govoni M, Orzincolo C, Trotta F. Clinical and radiologic evolution of synovitis, acne, pustulosis, hyperostosis, and osteitis syndrome: a single center study of a cohort of 71 subjects. *Arthritis Rheum* 2009;61:813-821
7. Boutin RD, Resnick D. The SAPHO syndrome: an evolving concept for unifying several idiopathic disorders of bone and skin. *AJR Am J Roentgenol* 1998;170:585-591
8. Earwaker JW, Cotten A. SAPHO: syndrome or concept? Imaging findings. *Skeletal Radiol* 2003;32:311-327
9. Hayem G, Bouchaud-Chabot A, Benali K, Roux S, Palazzo E, Silbermann-Hoffman O, et al. SAPHO syndrome: a long-term follow-up study of 120 cases. *Semin Arthritis Rheum* 1999;29:159-171
10. Fu Z, Liu M, Li Z, Fan Y, Zhang J, Zhang X, et al. Is the bull-head sign on bone scintigraphy really common in the patient with SAPHO syndrome? A single-center study of a 16-year experience. *Nucl Med Commun* 2016;37:387-392

SAPHO 증후군: 척추, 골반, 전흉벽의 골병변과 피부 병변이 동반된 증례

김현수¹ · 정소용¹ · 이수진¹ · 백인운² · 박정미^{1*}

Synovitis, acne, pustulosis, hyperostosis, osteitis (이하 SAPHO) 증후군은 무균성 골 병변과 특징적인 피부 병변을 보이는 염증성 질환이다. 63세 여자가 둔부를 포함하는 비특이적인 근골격계의 통증을 주소로 내원하였다. 내원하여 시행한 영상 검사에서 여러 척추와 골관절의 병변이 확인되었다. 여러 범위를 침범하는 척추의 골수 부종과 골피질의 미란, 비대칭적인 천장관절염, 흉쇄관절 골경화의 영상 소견은 SAPHO 증후군의 진단에 합당하였다. 영상 의학적 소견으로 SAPHO 증후군을 의심한 후에야 피부에 대한 검사가 이루어졌고 족저의 농포를 발견하였다. 피부 병변과 골병변이 동반된다는 특이점에도 불구하고 의심하지 않으면 피부의 병변은 간과되기 쉽다.

가톨릭대학교 의과대학 여의도성모병원 ¹영상의학과, ²내과