

Infusion Sclerotherapy of Microcystic Lymphatic Malformation: Clinico-Radiological Mid-Term Results

소방성림프관기형의 저속주입경화치료: 임상적 영상의학적 중기관찰 결과

Jongmin Lee, MD^{1*}, Seok-Jong Lee, MD², Ho Yun Chung, MD³, Seung Huh, MD⁴,
Hyung-Kee Kim, MD⁴

Departments of ¹Radiology, ²Dermatology, ³Plastic Surgery, ⁴Division of Vascular Surgery, Department of Surgery, Kyungpook National University Hospital, Daegu, Korea

Purpose: A new sclerotherapy technique by slow mechanical infusion of sclerosant was validated for treatment of microcystic lymphatic malformation (mLM).

Materials and Methods: Seventeen consecutive patients with mLM in extremities, cervicofacial area, and trunk were included (21.8 ± 21.5 years old, male:female = 5:12). All patients diagnosed as mLM were included. A total 4–32 mL 20–38% OK-432 solution was mechanically infused at the rate of 10 mL/hour into the mLM lesions. The treatment effect was estimated clinic-radiologically at the 4-month follow-up. Repeated sclerotherapy followed in the 6th month, if required. The therapeutic effect was evaluated using quantitative ultrasonographic examination including soft tissue thickness, cyst size and number.

Results: In 17 patients, total 31 infusion sclerotherapy sessions were performed and monitored for 425 ± 266 days. Fifteen patients (88%) showed improvement in all symptoms, signs, and ultrasonographic findings. In all cases, at least one finding presented improvement. The maximal number of cysts per ultrasonographic window and maximal diameter of the largest cyst decreased by 57 ± 57% and 51 ± 67%, respectively ($p = 0.102, 0.004$). The soft tissue thickness decreased by 18 ± 15% ($p < 0.01$). No significant complications such as distal lymphedema or skin necrosis occurred.

Conclusion: Infusion sclerotherapy is a safe and effective treatment technique for microcystic LM, with improved outcome.

Index terms

Lymphatic Abnormalities
Sclerotherapy
Infusions, Intralesional
Ultrasonography

Received November 17, 2015

Revised November 19, 2015

Accepted November 25, 2015

*Corresponding author: Jongmin Lee, MD
Department of Radiology, Kyungpook National University Hospital, 130 Dongdeok-ro, Jung-gu, Daegu 41944, Korea.
Tel. 82-53-420-5472 Fax. 82-53-422-2677
E-mail: jonglee@knu.ac.kr

This is an Open Access article distributed under the terms of the Creative Commons Attribution Non-Commercial License (<http://creativecommons.org/licenses/by-nc/3.0>) which permits unrestricted non-commercial use, distribution, and reproduction in any medium, provided the original work is properly cited.

INTRODUCTION

Congenital vascular anomalies including lymphatic malformation (LM) are described by different names from diverse viewpoints. LM has been described as cystic hygroma or lymphangioma based on physical and pathological features. In 1982, Mulliken and Glowacki (1) suggested a reasonable classification for congenital vascular anomalies including LM. Subsequently in 1996, the International Society for the Study of Vascular Anomalies acknowledged their nomenclature as a standard classification of

congenital vascular anomalies (2). Recently, LM is further classified as microcystic, macrocystic, and mixed forms, according to the size of the abnormal lymphatic cavity. Microcystic LM is defined as a single or multiple lymphatic cysts or channels smaller than 2 cm³ in size (3).

Clinical diagnosis of microcystic LM usually depends on its features including non-compressible tissue consistency during palpation, typical dermal lesions such as vesicles or maculopapular lesions, soft tissue mass, lymph leakage, hemorrhage, and pain (4). Ultrasonography (USG) or magnetic resonance imaging

(MRI) of LM aims to achieve more confirmative diagnoses and evaluate the extent and subtypes of the LM (5). In contrast to macrocystic LM showing single or multiple separate or interconnected thin-walled cysts, microcystic LM presents smaller irregular cysts with microscopic abnormal lymphatic channels. In the MRI, the microscopic abnormal lymphatic channels may appear as a solid lesion of high fluid content without an evident contrast-enhancement. In USG, the abnormal microscopic lymphatic channels usually appear as a hyperechoic infiltrative solid soft tissue lesion.

Historically, LM has been treated by surgery (5). Recently, direct puncture sclerotherapy has been used as an initial treatment of choice and achieved more favorable results than surgical treatment (3). In a prospective survey using OK-432 (Picibanil®, Chugai Pharmaceutical Co., Tokyo, Japan) as a sclerosant, the outcome of sclerotherapy was rated high in macrocystic LM and low in mixed LM. Whereas, in this prospective survey, no microcystic LM responded properly to the sclerotherapy (6). A study with repeated sclerotherapy using bleomycin A5 hydrochloride presented 78.57% effectiveness in a microcystic LM cohort. However, the response was clinically graded without quantitative analysis (7). A study with direct puncture sclerotherapy using 20 mg/mL doxycycline reported complete ablation of 179 microcysts without presenting effectiveness per patient (8). As for sclerotherapy of microcystic LM, diverse levels of its effectiveness have been reported by lesion characteristics, treatment methods, sclerosants, and result evaluation criteria (5-7, 9-14).

Due to the multiple small isolated cysts and since microscopic dilatation of lymphatic channels may be free from infiltration of the manually injected sclerosant during sclerotherapy, the therapeutic response of microcystic LM might not be as good and the recurrence rate might be higher than in macrocystic LM. We introduced a new sclerotherapy protocol using a slow mechanical infusion technique to increase the effectiveness of sclerotherapy for microcystic LM. The new protocol was applied to microcystic LM cases containing both infiltrative channel-type and microcystic lesions. In this study, a mid-term outcome of the new sclerotherapy technique, “infusion sclerotherapy”, was evaluated retrospectively.

MATERIALS AND METHODS

The study protocol was approved by our Institutional Review Board (IRB). Patients’ informed consents were waived by IRB due to the retrospective observational nature of the study.

Subjects

All consecutive 17 patients for the year 2012 were enrolled in the subject group without exclusion. Due to an exchange of sclerosant supply, latter data were not included in the study group. The age of subjects ranged from 1 to 68 years of age with an average of 18.6 years. The male to female ratio was 5:12. The anatomical locations of the microcystic LM were head and neck ($n = 7$), lower extremity ($n = 7$), trunk ($n = 1$), and upper extremity ($n = 2$). The subjects’ chief complaints comprised of dermal lesions such as vesicular maculopapular lesions ($n = 6$), swelling ($n = 4$), pain ($n = 5$), and leakage of lymph fluid or hemorrhage ($n = 2$). The demographic and clinical data of all subjects were summarized in Table 1.

Diagnosis

Microcystic LM was diagnosed based on clinical and imaging features by an interventional radiologist, vascular surgeons, plastic surgeons, orthopedic surgeons, and dermatologists in our interdisciplinary vascular anomaly clinic by consensus of. The diagnostic criteria were based on the typical features of microcystic LM including vesicular maculopapular lesion on the skin surface, soft tissue mass with rubbery hard texture, oozing of lymphatic fluid or hemorrhagic fluid, and/or pain and tenderness.

Imaging diagnoses were performed using both MRI and Doppler ultrasonography (DUS) according to our diagnostic protocol for vascular malformation. The extent of infiltrative channel-type and/or cystic lesion was mainly evaluated in the MRI. In the DUS, a confirmative diagnosis was performed based on the imaging features such as an infiltrative lesion with small well-defined cystic component(s) smaller than 16 mm in their mean diameter without blood flow inside the cystic lesion. The diameter threshold value of 16 mm was induced to match 2 cm³ in its volume. During compression-release technique, absence of augmentation-cessation of stagnant blood flow was a clue to exclude venous malformation.

According to our diagnostic protocol for vascular malforma-

tion, if the imaging and clinical features were not confirmative, surgical biopsy was listed as the final step for a confirmative diagnosis. However, in this subject group, no pre-treatment surgical biopsy was performed.

Treatment Procedures

The sclerotherapy procedures started from a pre-procedure on-site ultrasonographic evaluation of the microcystic LM. After deciding the target point for the percutaneous puncture, surgical preparation with sterilization and draping was performed. Ultrasonographic transducers were covered by dedicated sterile cover for the guidance of sclerotherapy procedure. Young patients who were potentially unable to cooperate were sedated before starting the procedure using 0.1 mg/kg midazolam (Midazolam®, Roche, Basel, Switzerland) and 1–2 mg/kg ketamine (Ketamine®, Huons, Seongnam, Korea). The sedation was maintained by repeated ketamine injection until the end of the sclerotherapy procedure. Under ultrasonographic guidance, the microcystic component was punctured using a 22–24 gauge needle. The success of the puncture could be identified by the aspiration of lymph fluid or saline influx into the cystic lesion observed under real-time ultrasonographic guidance. Small amount (1–2 mL) of iodine contrast media (Visipaque 320®, GE Healthcare AS Korea, Seoul, Korea) was injected manually into the lesion under fluoroscopic

monitoring. The LM was re-confirmed by the identification of abnormally dilated lymphatic channels, communicating microcystic lesions, and/or contrast media drainage into adjacent lymphatic vessels. In cases (patient number 9 and 10 in Table 1) who revealed no cystic component in ultrasonographic images, infusion needles were inserted into the central portion of the lesions noted in both MRI and USG. In these non-cystic cases, if the spreading pattern of the contrast media presented micro channels at 1 to 3 minutes after test injection, the infusion sclerotherapy was initiated.

For infusion sclerotherapy, the punctured needle or venipuncture catheter was connected to the syringe containing diluted OK-432 solution and loaded in a mechanical infusion pump (Terufusion®, Terumo Corporation, Tokyo, Japan). The sclerosant, OK-432, was diluted using radiopaque contrast media (Lipiodol Ultra-Fluide®, Laboratoire Guerbet, Aulnay-sous-Bois, France; Visipaque 320®, GE Healthcare AS Korea) to reach 25% of its concentration. In cases using lipiodol, since lipiodol was lipophilic in contrast to hydrophilic OK-432, the solution was prepared as an emulsion form by manual mechanical mixing of 2 agents contained in interconnected syringes. The manual mixing continued for at least 1 minute. The lipiodol was chosen for LM comprising of smaller cysts or thin channels since the lipophilicity was expected to facilitate the propulsion of sclerosant solution

Table 1. Microcystic Lymphatic Malformation Cases Treated with Infusion Sclerotherapy and Their Clinical Follow-Up Results

Patient ID	Sex	Age	Locations	Complaints	SSC	FUI	Sx Change	Sn Change
1	F	21	Leg	Pain	3	504	Mild Imp	Marked Imp
2	F	16	Proximal arm	Dermal lesions	1	213	Mild Imp	Mild Imp
3	F	18	Neck	Pain	3	926	Marked Imp	Mild Imp
4	M	1	Leg	Swelling	2	483	No change	No change
5	F	8	Thigh	Dermal lesions	1	295	Mild Imp	Marked Imp
6	F	7	Knee	Dermal lesions	1	138	Mild Imp	Mild Imp
7	F	19	Cheek	Dermal lesions	2	457	Mild Imp	Marked Imp
8	M	68	Thigh	Lymph leakage	1	44	Mild Imp	Mild Imp
9	F	52	Chest	Pain	2	470	Marked Imp	Mild Imp
10	F	6	Cheek	Swelling	2	372	Marked Imp	Marked Imp
11	M	19	Cheek	Swelling	2	938	Mild Imp	Mild Imp
12	F	11	Neck	Dermal lesions	1	734	Marked Imp	Marked Imp
13	F	2	Knee	Swelling	2	604	Mild Imp	Mild Imp
14	M	15	Cheek	Pain	2	589	Mild Imp	Mild Imp
15	M	17	Cheek	Lymph leakage	4	335	Marked Imp	Mild Imp
16	F	17	Leg	Dermal lesions	1	575	Mild Imp	Mild Imp
17	F	34	Shoulder	Pain	1	538	Mild Imp	Mild Imp

FUI = follow-up interval by days, Imp = improvement, Sn = clinically observed sign, SSC = sclerotherapy session count, Sx = subjective symptom

through thin channels. When the lipiodol emulsion presented a layering border by hydrophilic-lipophilic separation, to keep the concentration of OK-432, the border zone was placed at the eccentric outlet of syringe. The loading volume of the OK-432 solution was decided subjectively based on the size of LM lesion. Initially, 8–16 mL of the OK-432 solution was loaded in to the 20-mL syringe. The sclerosant was infused at a rate of 10 mL/hour constantly in all subjects.

During the infusion, fluoroscopic surveillance was performed every 1 or 2 minutes. Intermittently, radiographic images were acquired to more clearly demonstrate the spread of the sclerosant within LM lesion, as compared to fluoroscopy. Also, ultrasonographic surveillance was performed intermittently for checking appropriate infusion of sclerosant into the cystic lesion. During the infusion of sclerosant solution, if the solution started to be drained into adjacent major normal lymphatic vessels, the infusion was stopped immediately. The normal lymphatic vessels were identified by their typical location and connection as well as tubular vascular morphology without cystic or irregularly dilated segments.

If the sclerosant coverage in the LM lesion was not sufficient due to disconnected cysts, another USG-guided puncture was performed and additional infusion sclerotherapy was continued until full coverage of the LM lesion by the infused sclerosant solution. In cases of multiple parallel needling, simultaneous infusion using multiple infusion pumps was conducted. The number of punctures needed per session ranged from 1 to 4 (average 2.0 ± 1.2). The injected volume and infusion time of the OK-432 solution ranged from 4.0 mL to 32.0 mL (average 10.0 ± 6.5 mL) and from 10 min to 120 min (average 46 ± 22 minutes), respectively. The coverage was confirmed by comparing the contrast-enhanced lesion in fluoro-radiography and lesion extent in USG or MRI.

Post-Treatment Care and Follow-Up

After the completion of the sclerosant infusion, compressive dressing was applied if anatomically possible. In cases of absent normal draining lymphatic channels around the lesion, gentle massage was applied for several hours. Routinely, 5-mg Dexamethasone sodium phosphate (Dexamethasone®, Jeil Pharmaceutical, Daegu, Korea) was intravenously infused within 1 hour after sclerotherapy to prevent excessive inflammation and its

complications. On the third day, the lesion area was checked to evaluate sclerotherapy-related complications such as dermal discoloration, bleb formation, lymphedema, or necrosis. If there were no complications, the patients were discharged. In 1–3 week, the patients returned to the radiology outpatient clinic to be checked for sclerotherapy-related complications a second time. If no further problems occurred, the patients were told to return in 4 months for a follow-up ultrasonographic examination. The follow-up ultrasonographic exams were performed with the same equipment, scanning technique, and radiologist as the initial exams.

The result of the infusion sclerotherapy was initially decided by follow-up USG in 4 months using the same ultrasonographic machines and scanning protocols. In the initial ultrasonographic images, recalled from picture archiving and communication system (Star PACS, Infinitt, Seoul, Korea), the largest cyst was selected as a target cyst. The longest diameter of the target cyst was measured with counting total number of cysts within the image. The soft tissue thickness was measured from dermal surface to an interface between the lesion and underlying structure such as muscular fascia or bony cortex (Fig. 1). During the follow-up USG using the same settings as the initial exam, interval changes of target cyst size, number of cysts, and soft tissue thickness were measured quantitatively. Also, the results were judged on a scale of 6 points; 0, aggravated; 1, no interval change; 2, mild improvement; 3, marked improvement; 4, near complete improvement; 5, complete improvement. When > 1 component improved, “marked improvement” was marked, whereas the “mild improvement” was marked when only 1 component improved.

Outcome Evaluation

The final result of the infusion sclerotherapy was decided at the vascular anomaly clinic based on an interdisciplinary consensus during the patient's second visit after 4 months. The results were evaluated as improved, persistent, or aggravated by subjective symptoms, objective signs, and image findings mainly by USG. A persistent subjective symptom was declared when the patient did not notice an evident change 4 months after sclerotherapy. A persistent sign was objectively defined when the patient's family members and doctors could not find any evidence of change in the lesion. Further treatment strategies were decided based on an interdisciplinary consensus, as well as the agreement of patients.

If either improved or persistent cases were LM with accessible cysts by USG-guided puncture, additional infusion sclerotherapy was usually recommended. No further sclerotherapy was recommended in aggravated cases based on an interdisciplinary consensus, since it was regarded as an ineffective therapy. In cases of multiple sclerotherapies, the initial and the last clinical and ultrasonographic findings were compared to validate the infusion sclerotherapy.

Statistical Analysis

All statistics were computed using SPSS version 21.0.0.0 (SPSS Inc., Chicago, IL, USA). Quantitative data were compared by paired *t*-test. A *p*-value < 0.05 was considered statistically significant.

RESULTS

In 17 patients, total 31 infusion sclerotherapy sessions (1 to 4 times with an average of 1.8 times per patient) were performed and monitored clinically and ultrasonographically. Total follow-up period from the initial sclerotherapy ranged from 44 to 938 days with an average of 425 ± 266 days. Patient number 8 returned to the clinic in 44 days after initial sclerotherapy with mildly improved clinical features. Fifteen patients (88%) showed improvement in all symptoms, signs, and image findings (Fig. 2). One patient (patient number 4 in Tables 1, 2) revealed no interval changes of his subjective symptom and sign despite remarkable improvement of ultrasonographic findings. Another patient (pa-

tient number 6 in Tables 1, 2) revealed aggravated lesion in USG despite of mild improvement of symptoms and signs. However, in all cases treated by infusion sclerotherapy, at least 1 component among symptom, sign, and image finding presented improvement (Tables 1, 2, Fig. 3).

During initial ultrasonographic examinations, maximal number of cysts per ultrasonographic window ranged from 0 to 7 with an average of 1 ± 1.8 . Maximum diameter of the largest cyst in most crowded ultrasonographic window ranged from 0 mm to 16.0 mm with an average of 9 ± 5.7 mm. The zero count and diameter meant non-cystic LM diagnosed by fluid-rich solid soft tissue finding and pathognomic dermal vesicular lesions. The soft tissue thickness including lesion and overlying dermal structures ranged from 3.5 mm to 24.7 mm with an average of 14.5 ± 6.4 mm. During the last follow-up USG, the maximal number of cysts per ultrasonographic window and maximal diameter of the largest cyst decreased by $57 \pm 57\%$ and $51 \pm 67\%$, respectively ($p = 0.102, 0.004$). The soft tissue thickness decreased by $18 \pm 15\%$ ($p < 0.01$) (Fig. 1). The 3 ultrasonographic check points showed asynchronously, different interval changes per subject (Table 2).

Sclerotherapy-related complication issue occurred in 1 of 17 cases (5.9%). A localized mass-like microcystic LM case (patient number 4 in Tables 1, 2) showed aggravated clinical features due to persistent inflammation and intra-lesional lymphedema. After 1 month of medical treatment with antibiotics and anti-inflammatory drugs, the lymphedema and inflammation subsided. At the last follow-up USG in 483 days, cystic components disappeared within scarred mass-like lesion and the soft tissue thick-

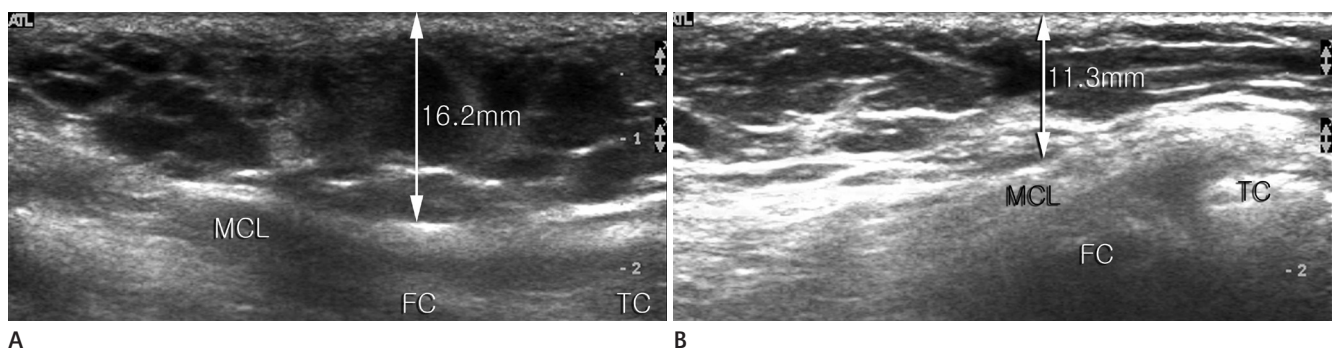


Fig. 1. A 2-year-old girl (patient number 13 in Tables 1, 2) who presented with soft tissue swelling at left knee area was diagnosed as microcystic lymphatic malformation.

A. Initial ultrasonography demonstrates infiltrative lesion containing multiple small cysts in subcutaneous layer of medial aspect of left knee joint. Soft tissue thickness is 16.2 mm.

B. Post-sclerotherapy 20-month follow-up ultrasonography shows markedly improved lesion with near disappearance of cysts. Soft tissue thickness was reduced to 11.3 mm.

FC = femoral condyle, MCL = medial collateral ligament, TC = tibial condyle

ness decreased up to 68%. However, due to induration and discoloration of the lesion and overlying skin, both patient's and doctors' views could not be satisfied. Based on an interdisciplinary consensus, the patient was finally treated by surgical excision.

The histological examination using classic hematoxylin and eosin stain, special staining for elastic fiber, and immunohistochemistry for D2-40, Glut-1, CD31, SMA, and Prox-1 presented a LM.

No other early complication was noted in this study. Also, no

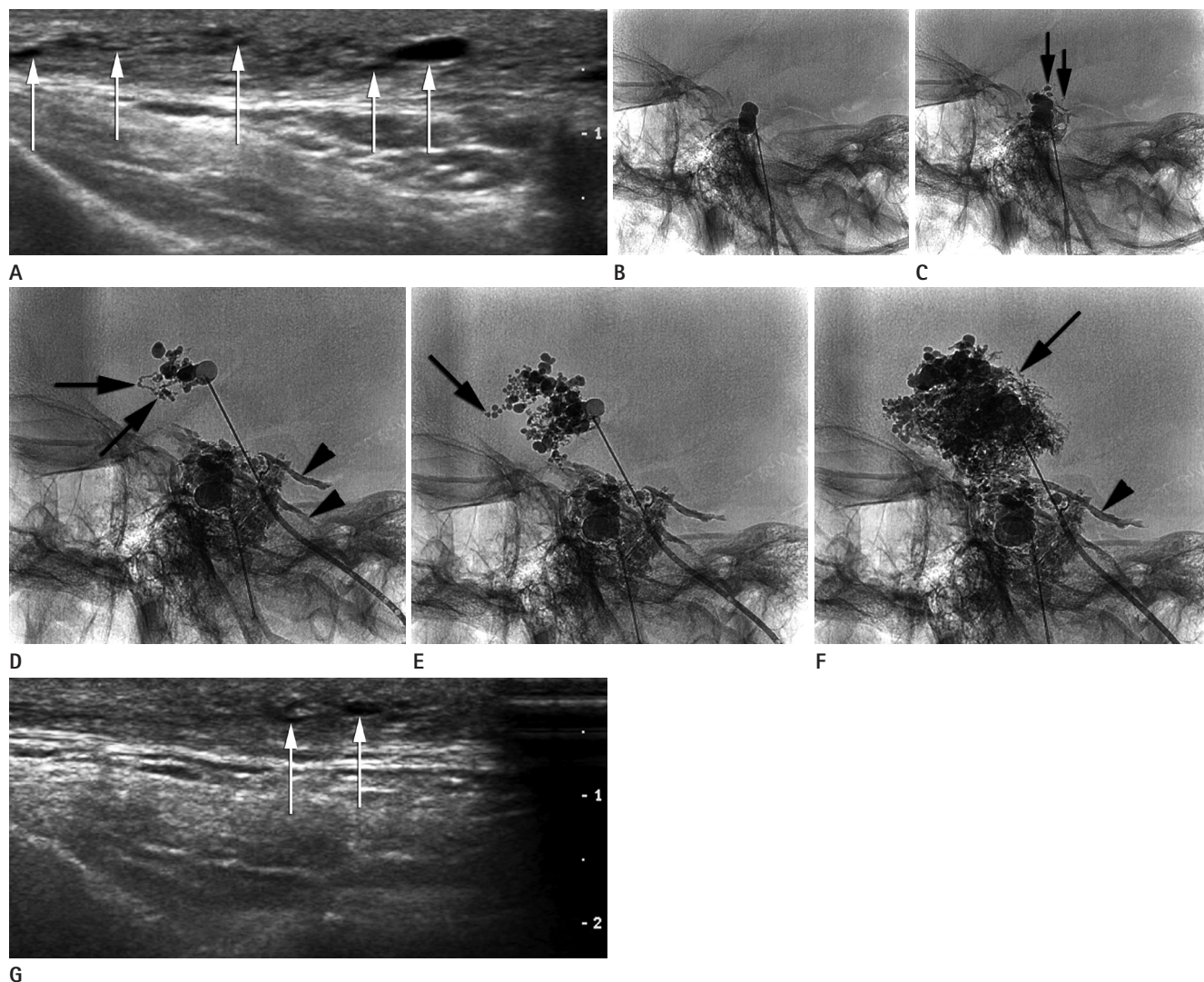


Fig. 2. A 17-year-old man (patient number 15 in Tables 1, 2) presented a soft tissue mass with vague pain and tenderness in the left temporal area. Also, the patient complained of typical tiny dermal vesicles with intermittent fluid discharge. A poorly-defined non-compressible soft tissue mass was palpated. Clinical impression was agreed as lymphatic malformation.

A. The initial ultrasonography reveals an infiltrative soft tissue lesion with multiple non-uniform small cystic and channel-like components (arrows) in subcutaneous fat layer of the left temporal area.

B. At the early stage of infusion sclerotherapy, microcystic components are filled by sclerosant containing OK-432 and lipophilic contrast media. The infusion was done by an electromechanical infusion pump at the speed of 10 mL/hr.

C. In 2 minutes after infusion start, the sclerosant infiltrates into adjacent microcysts and channels (arrows).

D. The second lesion area was punctured and sclerosant was infused in parallel. In 21 minutes after initial infusion start, the lower lesion is fully filled by sclerosant with spill to adjacent normal-looking lymphatic channels (arrowheads). The newer upper lesion shows numerous microcysts interconnected by small channels (arrows).

E. In 29 minutes, more microcysts in further distance are filled by sclerosant (arrow).

F. In 50 minutes of infusion, no newly filled microcyst is noted and adjacent normal-looking small lymphatic channels are opacified (arrow). In lower lesion, opacification of normal lymphatic vessel is not progressed due to infusion stop (arrowhead).

G. Ultrasonography was performed in 1 year after the infusion sclerotherapy. In same scope and plane as the initial image (**A**), cystic and channel lesions (arrows) show decreased sizes. Also, clinical symptom and sign are improved markedly.

Table 2. Systematic Evaluation of Ultrasonographic Findings During Initial and the Last Follow-Up Examinations

Patient ID	Sex	Age	Initial US Findings			Follow-Up US findings			US Change (%)			Decision
			C _#	D _{mx}	ST _{th}	C _#	D _{mx}	ST _{th}	C _#	D _{mx}	ST _{th}	
1	F	21	2	6.7	11.0	0	0.0	9.6	-100	-100	-13	Mild Imp
2	F	16	2	8.5	18.8	0	0.0	11.8	-100	-100	-37	Mild Imp
3	F	18	1	6.8	5.5	0	0.0	5.4	-100	-100	-2	Mild Imp
4	M	1	4	14.4	20.7	0	0.0	14.1	-100	-100	-32	Marked Imp
5	F	8	1	6.9	9.6	0	0.0	8.8	-100	-100	-8	Mild Imp
6	F	7	1	2.8	7.4	1	5.2	7.4	0	86	0	Aggravated
7	F	19	1	15.9	13.4	0	0.0	7.2	-100	-100	-46	AC Imp
8	M	68	1	16.0	20.8	0	15.2	18.4	0	-2	-12	Mild Imp
9	F	52	0	0.0	13.8	0	0.0	8.7	N/A	N/A	-37	Marked Imp
10	F	6	0	0.0	24.7	0	0.0	22.4	N/A	N/A	-9	Mild Imp
11	M	19	1	16.0	23.8	0	0.0	20.9	-100	-100	-12	Marked Imp
12	F	11	1	1.5	3.5	1	1.0	3.0	0	-33	-14	Marked Imp
13	F	2	7	12.8	16.2	1	13.7	11.3	-86	7	-30	Marked Imp
14	M	15	4	8.7	7.0	7	5.1	6.6	75	-41	-6	Mild Imp
15	M	17	3	5.0	16.8	3	9.3	13.8	0	86	-18	Mild Imp
16	F	17	6	8.0	17.3	0	0.0	18.1	-100	-100	5	Marked Imp
17	F	34	2	16.0	15.3	1	6.3	10.9	-50	-61	-29	Marked Imp

AC = almost complete, C_# = maximal number of cysts in a single US window, D_{mx} = maximal diameter of the largest cyst (mm), Imp = improvement, N/A = not available, ST_{th} = soft tissue thickness from lesion to dermal surface (mm), US = ultrasonography

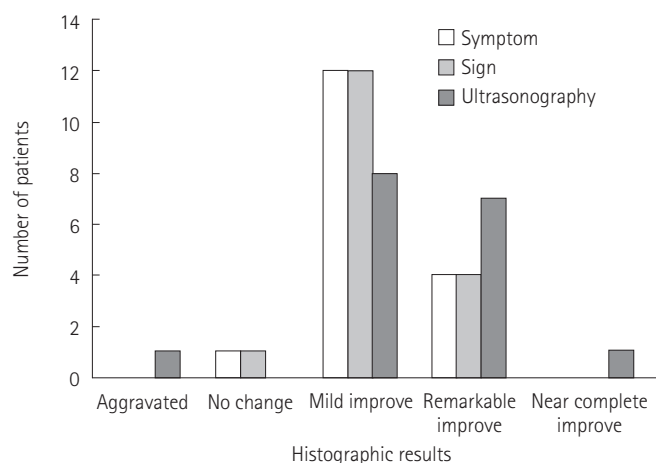


Fig. 3. Infusion sclerotherapy presented an improvement of symptoms, signs, and image findings in 16, 16, and 16 cases among 17 patients, respectively.

delayed sclerotherapy-related complication was presented. A case of long-standing and extensive microcystic LM in the right thigh (patient number 8 in Tables 1, 2) presented mild improvement when 44-day monitoring by USG. However, in 7 months, clinical features were aggravated to the same degree as the initial lesion. Three years prior, this patient had undergone surgical dermosubcutaneous excision and subsequent skin graft. In the second year follow-up, recurrent lesion had been observed in posterior thigh adjacent to the graft margin, which induced the infusion sclero-

therapy. The further aggravation in the third year occurred along the whole circumference of and within the grafted skin with conjoined lymphedema in right lower leg. The lymphedema of the right lower leg and lymphatic fluid leakage could be managed by conservative compressive dressing. In this case, the infusion sclerotherapy could achieve a transitory remission before a recurrence after 7 months. No long term image follow-up was performed for this patient.

DISCUSSION

In this study, valid results of the infusion sclerotherapy for microcystic and channel-type LM were achieved. Microcystic LM is reported to be less effective to percutaneous sclerotherapy using diverse sclerosants. A noticeable report using several sclerosants presented complete responses in 17% of 15 cases with microcystic LM. However, in the same study, the success rate was markedly lower than macrocystic LM (47%) (15). A main reason for lower success rate of sclerotherapy in microcystic LM is conceived to be non-uniform spread of sclerosant through complex lesion geometry with less connectivity. The rationale of the present study was that slow constant infusion could improve uniformity of drug delivery through the lesion by avoiding earlier rup-

ture or occlusion of lymphatic channels.

The definition of microcystic LM was suggested as LM comprising of single or multiple cysts smaller than 2 cm³ in volume. Lesions with a cyst larger than this criterion were classified as a macrocystic LM. Combined macrocystic and microcystic LM was nominated as mixed type LM (3). In parallel, another classification guideline using the diameter of the largest cyst within LM has been suggested. The maximal diameter of cysts less than 2 cm was suggested as microcystic LM (7, 16). In this study, microcystic LM was classified by cut-off value of 16 mm in diameter with the criterion of 2 cm³ in volume, since measuring the diameter was more practical during ultrasonographic evaluation than measuring the volume of the cysts.

In this study, the 3 ultrasonographic check points showed asynchronous interval changes. In most cases, the size of the largest cyst and soft tissue thickness decreased with statistical significance. In 9 cases (53%), despite no statistical significance, there was a trend that maximal number of cyst per ultrasonographic window presented unchanged or increased. Among these 9 cases, 7 cases presented a decreased size of the largest cyst. In addition, all the 9 cases presented improvement in clinical symptom and sign. In cases showing increased diameter of the largest cyst ($n = 3$), no increase in cyst number and improvement of clinical features were observed. In a single case of increased soft tissue thickness, all the other clinical and imaging features improved. Due to the complexity of image findings in the present study, systematic quantitative evaluation with majority rule was used (Table 2).

Among ultrasonographic check points, soft tissue thickness was the most consistent with clinical features. Since soft tissue swelling is a major clinical complaint, soft tissue thickness change seemed to be concordant with clinical decision. The check point cyst number did not change sensitively although size of the cysts gradually decreased (Table 2). When cysts decreased, daughter cysts developed in the adjacent area possibly due to occluded drainage routes. In this context, the importance of ultrasonographic findings is listed as soft tissue thickness, size of the largest cyst, and number of cysts, in order.

On the demographic data for our subject groups, more females than males were included in contrast to the report of no sexual predilection (17). In this study, the most prevalent lesion sites were head, neck, and lower extremity, which was concordant with a previous report (18). In the literature, the prevalent age of

LM was reported as infancy and young childhood (80–90% before the age of 2 years) (18). Whereas, our entire subject cohort showed a mean age of 18.6 years and only 2 subjects were younger than the age of 2 years. Since our subject group was solely comprised of microcystic LM cases actually treated by sclerotherapy, the age distribution should be deviated from epidemiological data comprising of all subtypes of LM. Additional reasons for age discrepancy of our microcystic LM cases include less clinical implications in young subjects due to relatively shorter pathological history and a tendency to postpone active interventional or surgical treatment.

Several drugs or chemicals have been used as agents for sclerotherapy of LM, including bleomycin, doxycycline, ethanol, and OK-432 (3, 19–21). Despite the complications by penetration into adjacent tissue, ethanol has been used as the strongest sclerosant for more definite results (10, 22, 23). Bleomycin was introduced for LM sclerotherapy in very early trials (24). However, it may cause fatal complication such as pulmonary interstitial fibrosis or hypersensitivity (25, 26). Among the cases in this study, no fatal complications developed after infusion sclerotherapy using OK-432. Yang et al. (11) recently reported the application of bleomycin A5 in subjects including balanced numbers of LM subtypes in head and neck with 100% response rate. In this study, since the effect of sclerotherapy was evaluated by means of size change of the target cysts within LM, the response might be overestimated, as compared to its clinical relevance. Recently, a successful repeated sclerotherapy for microcystic LM using bleomycin was reported without relevant complication (27). Shergill et al. (28) reported an excellent response of microcystic LM to doxycycline sclerotherapy although the cohort was small. No fatal complications by doxycycline sclerotherapy have been published, to our best knowledge. However, the overall complication rate of doxycycline was reported to be significantly associated with microcystic subtype and greater dose of doxycycline (29).

In this study, the infusion sclerotherapy technique was evaluated originally using OK-432, which was a routine sclerosant in our institute. OK-432 is the attenuated low-virulent strain of group A *Streptococcus pyogenes* of human origin. By its immunopharmacologic inflammatory reaction, endothelial lining structures of LM are destroyed and adhered representing the sclerosing effect (30). Whereas OK-432 is not approved for use in American and European countries, Asian countries where our

institute locates approved its use as a sclerosant. The effect of OK-432 sclerotherapy of microcystic LM was summarized in a meta-analysis comprising 48 cases (13). In the overall results, 60% of cases showed good responses. In this study, 88% of the microcystic LM cases treated by the infusion sclerotherapy using OK-432 showed improvement as agreed on by all patients and doctors, and confirmed by images.

OK-432 sclerotherapy for LM could be regarded as a safe technique. However, in case of infusion sclerotherapy, higher volume of sclerosant should be infused into both microcystic and micro-channel components of microcystic LM. Due to the slower infusion rate and weaker infusion power compared to manual injection, the sclerosant could travel further through microchannels with decreased possibility of extravasation into surrounding soft tissue. By thoroughly filling the abnormal LM spaces, subsequently, the sclerosant could have a higher chance to be drained into adjacent normal lymphatic channels. Based on these facts, higher prevalence of complications in adjacent lymphatic tissue such as lymphedema are possible. Therefore, the application of infusion sclerotherapy technique on critical lymphatic bridge-head such as inguinal or axillary area should be done with caution and may require further evaluation for its safety.

A major limitation of this study was that the decision of symptoms and signs was performed subjectively by patients and surroundings, including the doctors. However, since the improvement was based on consensus of a multi-disciplinary group, objectivity might be preserved. The second limitation was the ultrasonographic improvement of microcystic LM was decided by radiologists who were not blinded to sclerotherapy information. However, introduction of a systematic quantitative evaluation of image findings attempted to minimize this limitation. The third limitation was that the OK-432 is not available for world-wide use. Although availability of the OK-432 is limited to some countries where our institute locates, its effectiveness as a sclerosant is accepted in the literature (13). Furthermore, in this study, the drug delivery technique was a main focus rather than any specific property of OK-432. The fourth limitation was that the sclerosant was an emulsion of lipophilic lipiodol and hydrophilic OK-432 that was infused for a long time. During delayed infusion, both components should be separated with layering. To maintain the concentration of OK-432 during delayed infusion, in this study, the layer between OK-432 and lipiodol was adjusted to the sy-

ringe outlet orifice. In addition, due to well-acknowledged embolic effect of lipiodol, evaluation of pure benefit of infusion sclerotherapy may be limited as compared to reported data with hydrophilic contrast media (16, 28, 29). The fifth limitation was that all the follow-up imaging was performed using USG alone. Not every patient received MR exam for their routine follow-up imaging due to financial burden in our country. The objectiveness of ultrasonographic decision may have limitation for accurate quantitative measurement of interval change. In this study, ultrasonographic evaluation was based on qualitative and semi-quantitative ways with a systematic stratification to minimize subjective bias by observer. The last limitation was that the infusion sclerotherapy technique was applied only to the OK-432 cohort due to the size of cohort in our institute. The feasibility evaluation for the infusion sclerotherapy should be continued in cohorts with the other sclerosants.

In conclusions, a new sclerotherapy technique for microcystic LM i.e., infusion sclerotherapy was suggested and verified. Infusion sclerotherapy was a safe and effective treatment technique for microcystic LM, with favorable outcome. For more extensive and safe application of the infusion sclerotherapy, more delicate guideline should be developed through more extensive application. In addition, a prospective randomized trials comparing the infusion sclerotherapy and conservative technique is expected.

Acknowledgments

This research was supported by Basic Science Research Program through the National Research Foundation of Korea (NRF) funded by the Ministry of Science, ICT&Future Planning (NRF-2015R1A2A2A03005433).

REFERENCES

1. Mulliken JB, Glowacki J. Hemangiomas and vascular malformations in infants and children: a classification based on endothelial characteristics. *Plast Reconstr Surg* 1982; 69:412-422
2. Enjolras O. Classification and management of the various superficial vascular anomalies: hemangiomas and vascular malformations. *J Dermatol* 1997;24:701-710
3. Giguère CM, Bauman NM, Sato Y, Burke DK, Greinwald JH, Pransky S, et al. Treatment of lymphangiomas with OK-432

- (Picibanil) sclerotherapy: a prospective multi-institutional trial. *Arch Otolaryngol Head Neck Surg* 2002;128:1137-1144
4. Bond J, Basheer MH, Gordon D. Lymphangioma circumscriptum: pitfalls and problems in definitive management. *Dermatol Surg* 2008;34:271-275
 5. Renton JP, Smith RJ. Current treatment paradigms in the management of lymphatic malformations. *Laryngoscope* 2011;121:56-59
 6. Smith MC, Zimmerman MB, Burke DK, Bauman NM, Sato Y, Smith RJ; OK-432 Collaborative Study Group. Efficacy and safety of OK-432 immunotherapy of lymphatic malformations. *Laryngoscope* 2009;119:107-115
 7. Bai Y, Jia J, Huang XX, Alsharif MJ, Zhao JH, Zhao YF. Sclerotherapy of microcystic lymphatic malformations in oral and facial regions. *J Oral Maxillofac Surg* 2009;67:251-256
 8. Shiels WE 2nd, Kang DR, Murakami JW, Hogan MJ, Wiet GJ. Percutaneous treatment of lymphatic malformations. *Otolaryngol Head Neck Surg* 2009;141:219-224
 9. Zhou Q, Zheng JW, Mai HM, Luo QF, Fan XD, Su LX, et al. Treatment guidelines of lymphatic malformations of the head and neck. *Oral Oncol* 2011;47:1105-1109
 10. Cahill AM, Nijs E, Ballah D, Rabinowitz D, Thompson L, Rintoul N, et al. Percutaneous sclerotherapy in neonatal and infant head and neck lymphatic malformations: a single center experience. *J Pediatr Surg* 2011;46:2083-2095
 11. Yang Y, Sun M, Ma Q, Cheng X, Ao J, Tian L, et al. Bleomycin A5 sclerotherapy for cervicofacial lymphatic malformations. *J Vasc Surg* 2011;53:150-155
 12. Niti K, Manish P. Microcystic lymphatic malformation (lymphangioma circumscriptum) treated using a minimally invasive technique of radiofrequency ablation and sclerotherapy. *Dermatol Surg* 2010;36:1711-1717
 13. Poldervaart MT, Breugem CC, Speleman L, Pasmans S. Treatment of lymphatic malformations with OK-432 (picibanil): review of the literature. *J Craniofac Surg* 2009;20:1159-1162
 14. Alomari AI, Karian VE, Lord DJ, Padua HM, Burrows PE. Percutaneous sclerotherapy for lymphatic malformations: a retrospective analysis of patient-evaluated improvement. *J Vasc Interv Radiol* 2006;17:1639-1648
 15. Hogeling M, Adams S, Law J, Wargon O. Lymphatic malformations: clinical course and management in 64 cases. *Australas J Dermatol* 2011;52:186-190
 16. Rautio R, Keski-Nisula L, Laranne J, Laasonen E. Treatment of lymphangiomas with OK-432 (picibanil). *Cardiovasc Intervent Radiol* 2003;26:31-36
 17. Smith RJ. Lymphatic malformations. *Lymphat Res Biol* 2004;2:25-31
 18. Alqahtani A, Nguyen LT, Flageole H, Shaw K, Laberge JM. 25 years' experience with lymphangiomas in children. *J Pediatr Surg* 1999;34:1164-1168
 19. Mathur NN, Rana I, Bothra R, Dhawan R, Kathuria G, Pradhan T. Bleomycin sclerotherapy in congenital lymphatic and vascular malformations of head and neck. *Int J Pediatr Otorhinolaryngol* 2005;69:75-80
 20. Nehra D, Jacobson L, Barnes P, Mallory B, Albanese CT, Sylvester KG. Doxycycline sclerotherapy as primary treatment of head and neck lymphatic malformations in children. *J Pediatr Surg* 2008;43:451-460
 21. Herbreteau D, Riche MC, Enjolras O, Khayata M, Lemarchand-Venencie F, Borsik M, et al. Percutaneous embolization with Ethibloc of lymphatic cystic malformations with a review of the experience in 70 patients. *Int Angiol* 1993;12:34-39
 22. Park HS, Do YS, Park KB, Kim DI, Kim YW, Kim MJ, et al. Ethanol embolotherapy of hand arteriovenous malformations. *J Vasc Surg* 2011;53:725-731
 23. Orlando JL, Caldas JG, Campos HG, Nishinari K, Wolosker N. Outpatient percutaneous treatment of deep venous malformations using pure ethanol at low doses under local anesthesia. *Clinics (Sao Paulo)* 2010;65:837-840
 24. Yura J, Hashimoto T, Tsuruga N, Shibata K. Bleomycin treatment for cystic hygroma in children. *Nihon Geka Hoka* 1977;46:607-614
 25. Levy RL, Chiarillo S. Hyperpyrexia, allergic-type response and death occurring with low-dose bleomycin administration. *Oncology* 1980;37:316-317
 26. Sung MW, Chang SO, Choi JH, Kim JY. Bleomycin sclerotherapy in patients with congenital lymphatic malformation in the head and neck. *Am J Otolaryngol* 1995;16:236-241
 27. Chaudry G, Guevara CJ, Rialon KL, Kerr C, Mulliken JB, Greene AK, et al. Safety and efficacy of bleomycin sclerotherapy for microcystic lymphatic malformation. *Cardiovasc Intervent Radiol* 2014;37:1476-1481

28. Shergill A, John P, Amaral JG. Doxycycline sclerotherapy in children with lymphatic malformations: outcomes, complications and clinical efficacy. *Pediatr Radiol* 2012;42:1080-1088
29. Burrows PE, Mitri RK, Alomari A, Padua HM, Lord DJ, Sylvia MB, et al. Percutaneous sclerotherapy of lymphatic malformations with doxycycline. *Lymphat Res Biol* 2008;6:209-216
30. Fujino A, Moriya Y, Morikawa Y, Hoshino K, Watanabe T, Shimojima N, et al. A role of cytokines in OK-432 injection therapy for cystic lymphangioma: an approach to the mechanism. *J Pediatr Surg* 2003;38:1806-1809

소방성림프관기형의 저속주입경화치료: 임상적 영상의학적 중기관찰 결과

이종민^{1*} · 이석종² · 정호윤³ · 허 승⁴ · 김형기⁴

목적: 소방성림프관기형의 치료에서 저속 기계식 주입법을 이용한 새로운 경화치료법의 유용성을 검증하였다.

대상과 방법: 17명의 소방성림프관기형 환자를 연속적으로 연구에 포함하였으며 병변부위는 사지 두경부 및 체간이었다 (21.8 ± 21.5 세, 남녀비 = 5:12). 총 4~32 mL의 20~38% OK-432를 10 mL/hr의 속도로 병변 내 주입하였다. 4개월 추적검사에서 임상-영상의학 합의에 의하여 치료효과가 결정되었다. 필요한 경우 추가적 경화치료를 6개월째 시행하였다. 연부조직두께, 낭종크기 및 수 등의 정량적 초음파 소견을 이용하여 치료효과를 분석하였다.

결과: 17명의 환자에서 총 31회의 저속주입경화치료가 시행되었으며 임상 및 초음파검사상 425 ± 266 일까지 추적관찰하였다. 15명(88%)의 환자에서 증상 및 영상 소견이 공통적으로 호전되었다. 모든 증례에서 적어도 한 가지 소견의 호전을 보였다. 초음파상에서의 최대 낭종수 및 최대 낭종의 최대 직경은 각각 $57 \pm 57\%$ 및 $51 \pm 67\%$ 의 감소를 보였다($p = 0.102$, 0.004). 연부조직의 두께는 $18 \pm 15\%$ 감소를 보였다($p < 0.01$). 원위부 림프부종이나 피부괴사와 같은 심각한 합병증은 발생하지 않았다.

결론: 저속주입경화치료법은 소방성림프관기형의 치료에 있어서 안전하고 효과적이었으며 향상된 결과를 보였다.

경북대학교병원 ¹영상의학과, ²피부과, ³성형외과, ⁴혈관외과