

Incidental Finding on Cardiac CT of Anomalous Anterior Papillary Muscle without Left Ventricular Outflow Obstruction: A Case Report

심장 CT에서 우연히 발견된 좌심실 유출로 폐쇄를 동반하지 않은
승모판막 전방 유두근 이상 1예

Eun-Ju Kang, MD¹, Jongmin Lee, MD², Ki-Nam Lee, MD^{1*}

¹Department of Radiology, Dong-A University College of Medicine, Dong-A University Hospital, Busan, Korea

²Department of Radiology, Kyungpook National University College of Medicine, Kyungpook National University Hospital, Daegu, Korea

Abnormal insertion of the papillary muscles is rare and has been described only in patients with hypertrophic cardiomyopathy based on findings of echocardiography or autopsy. Herein, we reported a rare case of abnormal insertion of the papillary muscle in a 64-year-old man without cardiomyopathy, incidentally detected by cardiac computed tomography (CT). Multiplanar long-axis and three-dimensional volume-rendered reconstructed images revealed an abnormally inserted papillary muscle, which did not provoke left ventricular outflow tract obstruction. This is the first report of the anomaly in a healthy individual who was initially assessed by cardiac CT.

Index terms

Papillary Muscle
Heart
Computed Tomography

Received August 17, 2015

Revised September 25, 2015

Accepted October 9, 2015

*Corresponding author: Ki-Nam Lee, MD
Department of Radiology, Dong-A University College of Medicine, Dong-A University Hospital,
26 Daesingongwon-ro, Seo-gu, Busan 49201, Korea.
Tel. 82-51-240-5367 Fax. 82-51-253-4931
E-mail: gnlee@dau.ac.kr

This is an Open Access article distributed under the terms of the Creative Commons Attribution Non-Commercial License (<http://creativecommons.org/licenses/by-nc/3.0>) which permits unrestricted non-commercial use, distribution, and reproduction in any medium, provided the original work is properly cited.

INTRODUCTION

Abnormal insertion of the papillary muscle is a rare disorder that has been described in patients with hypertrophic cardiomyopathy (HCM). It causes left ventricular outflow tract (LVOT) obstruction and mitral regurgitation (1). However, abnormal insertion of the papillary muscle without LVOT obstruction is extremely rare with only 1 such case previously reported by Zimbarra et al. (2). Moreover, abnormal insertion of the papillary muscle was detected by echocardiography or autopsy in all studies (1-3), whereas, detection by computed tomography (CT) is not yet reported. Herein, we reported a case of abnormal insertion of the papillary muscle without LVOT obstruction or cardiomyopathy that was incidentally found during cardiac CT. The study was approved by the Institutional Review Board.

CASE REPORT

A 64-year-old man (height 175 cm, weight 70 kg, body surface area 1.84 m²) was admitted to our hospital for general health screening. His physical exam and results of laboratory tests were unremarkable. An electrocardiogram showed ST elevation in the V2-5 precordial leads, so cardiac CT was conducted for further evaluation of coronary artery disease. Cardiac CT scans were obtained with a 320-row detector CT scanner (Aquilion One; Toshiba Medical Systems, Otawara, Japan); scan parameters were as follows: gantry rotation time, 350 ms; tube voltage, 120 kVp; tube current, 250 mA. Nonionic contrast material (350 mgI/mL, 70 mL) was administered at 4 mL/s, followed by a 30 mL saline flush. Because his average heart rate was 70 beats per minute, CT acquisition was performed by retrospective gat-

ing with maximum exposure during the 70–80% of the RR interval [minimum exposure (100 mA tube current) in other ranges of the RR interval]. The total dose-length product was 366.4 mGy·cm and the effective dose was 5.1 mSv using a conversion factor of 0.014 mSv/mGy·cm (4). All data sets were processed with iterative reconstruction [adaptive iterative dose reduction three-dimensional (3D)] with 0.5 mm slice thickness and a 0.5 mm interval. The images were sent to the Aquarius Worksta-

tion (TeraRecon, San Mateo, CA, USA) for 3D reconstruction.

Cardiac CT showed coronary arteries arising from the coronary sinus as normal, and no evidence of plaque or luminal stenosis. On the short-axis and long-axis multiplanar reformatted images acquired during the systolic phase, the anterior papillary muscle was elongated and inserted directly into the basal portion of the anterior mitral leaflet without interposed chordae tendineae (Fig. 1A–C). However, the midcavity of the LVOT

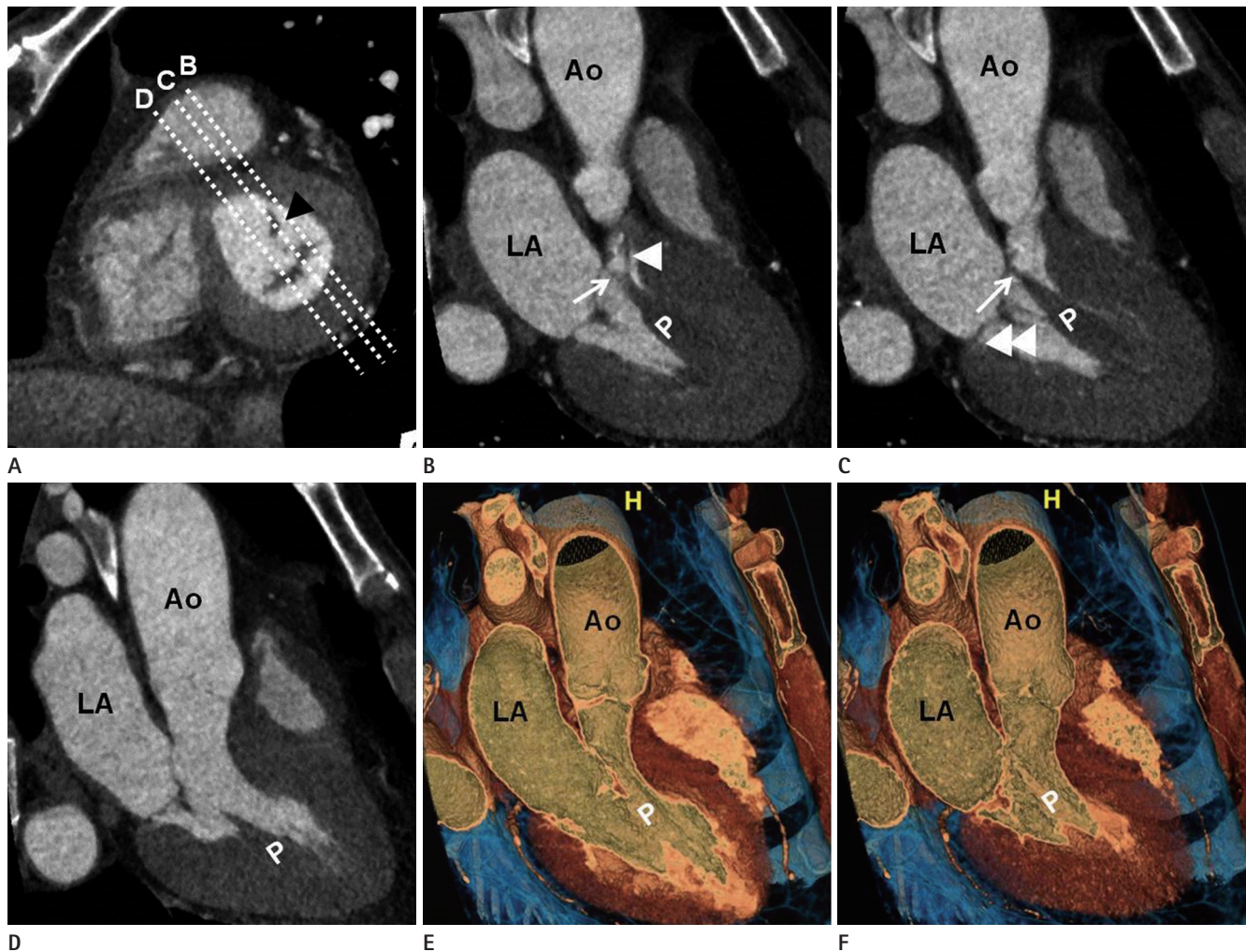


Fig. 1. A 64-year-old man with anomalous insertion of the anterior papillary muscle that is incidentally detected on cardiac CT.

A. Short-axis view acquired during the systolic phase shows elongated anterior papillary muscle (arrowhead) in close proximity to the left ventricular outflow tract (LVOT).

B, C. Long-axis images acquired during the systolic phase reconstructed perpendicular to the short axis plane with passes through the anterior papillary muscle (broken lines B and C in **A**). The elongated anterior papillary muscle inserts directly into the basal portion of the anterior mitral leaflet without interposed chordae tendineae (white arrows), producing LVOT narrowing. There are several chordae tendineae normally attached to the anterior mitral leaflet and lateral free wall of the left ventricle (white arrowheads).

D. Long-axis image acquired during the systolic phase reconstructed perpendicular to the short axis plane in the midcavity without traversing the anterior papillary muscle (broken line D in **A**) shows a wide-open LVOT without narrowing.

E, F. Three-dimensional volume-rendered long-axis views of the midcavity at diastole (**E**) and systole (**F**). The anterior papillary muscle is displaced anteriorly within the left ventricular cavity at diastole (**E**). However, there is no evidence of LVOT obstruction at systole (**F**).

Ao = aorta, CT = computed tomography, LA = left atrium, P = anterior papillary muscle

was widely opened without luminal narrowing on systolic phase (Fig. 1D). On the 3D volume-rendered long-axis views of the midcavity acquired during the diastolic phase, the anterior papillary muscle was displaced anteriorly within the left ventricular cavity. However, no evidence of LVOT obstruction at systole was found (Fig. 1E, F).

Short-axis, vertical, and horizontal long-axis cine images that were reconstructed at each 10% (10 phases) step throughout the RR interval showed normal movement of the mitral leaflet i.e., it was completely closed during the systolic phase with no definite evidence of wall motion abnormality. Short-axis images of the end-diastolic and end-systolic phases were used for global functional analysis of the left ventricle (LV). All functional parameters were normal i.e., ejection fraction, 73%; LV end-diastolic volume (EDV), 92 mL; LV end-systolic volume (ESV), 25 mL; LV EDV index, 50 mL/m²; LV ESV index, 13.6 mL/m²; cardiac output, 4.4 L/min; LV mass, 160 g; and LV mass index, 87.0 g/m². The patient refused echocardiography for further assessment of cardiac function. All functional parameters of cardiac CT were within normal ranges and the patient had no cardiac symptoms. Therefore, follow-up echocardiography was recommended by the physician, and the patient was discharged from the hospital.

DISCUSSION

Direct insertion of the papillary muscle into the anterior mitral leaflet is a congenital malformation with a selective anomaly of chordal development at about 12 weeks' gestation (5, 6). At this stage of normal cardiac development, the papillary muscles are contiguous with the mitral leaflets; the cephalad portions of the papillary muscles are transformed into thick muscular chordae tendineae, which ultimately become fibrous chordae positioned between the mitral leaflets and the papillary muscles (1). The selective failure of papillary muscle transformation into fibrous chordae might cause direct insertion of the papillary muscle.

Del Guzzo and Sherid (7) described the first case of abnormal insertion of the papillary muscles with LVOT obstruction, in 1983. Subsequently, Klues et al. (1) reported anomalous papillary muscles in 10 of 78 HCM patients with marked obstruction of LVOT that appeared to be caused by systolic apposition between the hypertrophied papillary muscles and septum in

the midportion of the left ventricular cavity (1). Although this anomaly is associated with HCM, it may also occur in otherwise normal hearts or in patients with other types of heart disease with or without LVOT obstruction. Recently, Zimbarra et al. (2) presented a case of anomalous insertion of the papillary muscle without LVOT obstruction in a patient with sickle cell disease; although they considered this anomaly as a normal variant, its association with sickle cell disease could not be excluded. There are no reported cases of this anomaly in healthy individuals without LVOT obstruction.

Traditionally, morphological and functional evaluation of cardiac chambers or valves is performed with echocardiography. However, echocardiography is operator-dependent and has interobserver variability; poor acoustic windows and patient's body habitus can limit image quality. In comparison, cardiac magnetic resonance imaging (MRI) provides better anatomic detail of the cardiac valves and also allows quantification of valve flow. However, cardiac MRI requires a long acquisition time and has several contraindications for certain patients. Cardiac CT is increasingly used for noninvasive coronary artery imaging due to technical developments in CT scanners. Although echocardiography remains the principal imaging technique for the assessment of the cardiac valves, cardiac CT is increasingly becoming a valuable complementary modality for visualization of the mitral and aortic valves (8). Moreover, functional analysis with cardiac CT is more accurate than that with 2-dimensional echocardiography or electrocardiography-gated single photon emission CT, which uses cardiac MRI as a reference standard (9). Therefore, an assessment of the cardiac valves and chamber anatomy during cardiac CT interpretation, whenever possible, provides valuable and detailed morphologic and functional information. Previous reports of anomalous papillary muscles are based on the echocardiographic images or autopsy. On the assumption that most of these anomalies were producing LVOT obstruction, they were detected with echocardiography in symptomatic patients.

In conclusion, we reported a rare case of incidentally detected abnormal insertion of the papillary muscle without LVOT obstruction on cardiac CT. This is the first report of the anomaly in a healthy individual who was initially assessed by cardiac CT.

REFERENCES

1. Klues HG, Roberts WC, Maron BJ. Anomalous insertion of papillary muscle directly into anterior mitral leaflet in hypertrophic cardiomyopathy. Significance in producing left ventricular outflow obstruction. *Circulation* 1991;84:1188-1197
2. Zimbarra Cabrita I, Grapsa J, Dawson D, Pinto FJ, Gibbs JS, Nihoyannopoulos P. Anomalous insertion of the papillary muscle in a patient with sickle cell disease: a normal variant with no left ventricular outflow obstruction. *Rev Port Cardiol* 2012;31:683-684
3. Strajina V, Živković V, Nikolić S. Anomalous anterior papillary muscle as an autopsy finding in two cases. *J Forensic Sci* 2013;58:544-547
4. Christner JA, Kofler JM, McCollough CH. Estimating effective dose for CT using dose-length product compared with using organ doses: consequences of adopting International Commission on Radiological Protection publication 103 or dual-energy scanning. *AJR Am J Roentgenol* 2010;194:881-889
5. Wenink AC, Gittenberger-de Groot AC, Brom AG. Developmental considerations of mitral valve anomalies. *Int J Cardiol* 1986;11:85-101
6. Teal SI, Moore GW, Hutchins GM. Development of aortic and mitral valve continuity in the human embryonic heart. *Am J Anat* 1986;176:447-460
7. Del Guzzo L, Sherid MV. Anomalous papillary muscle insertion contributing to obstruction in discrete subaortic stenosis. *J Am Coll Cardiol* 1983;2:379-382
8. Chen JJ, Manning MA, Frazier AA, Jeudy J, White CS. CT angiography of the cardiac valves: normal, diseased, and post-operative appearances. *Radiographics* 2009;29:1393-1412
9. Yamamuro M, Tadamura E, Kubo S, Toyoda H, Nishina T, Ohba M, et al. Cardiac functional analysis with multi-detector row CT and segmental reconstruction algorithm: comparison with echocardiography, SPECT, and MR imaging. *Radiology* 2005;234:381-390

심장 CT에서 우연히 발견된 좌심실 유출로 폐쇄를 동반하지 않은 승모판막 전방 유두근 이상 1예

강은주¹ · 이종민² · 이기남^{1*}

승모판막 전방 유두근의 이상 부착은 비후성 심근병증 환자에서 심초음파와 부검 소견을 토대로 드물게 보고되었다. 이 논문에서는 기저 심근질환이 없는 64세 남성의 심장 CT에서 우연히 발견된 드문 증례를 보고하고자 한다. 다중평면 장축 영상과 삼차원 용적 재구성 영상에서 좌심실 유출 협착을 일으키지 않는 비정상적으로 부착된 승모판막 전방 유두근이 관찰되었다. 이 증례는 무증상의 건강한 사람에서 심장 CT에서 발견된 상기 기형의 첫 번째 보고이다.

¹동아대학교 의과대학 동아대학교병원 영상의학과, ²경북대학교 의과대학 경북대학교병원 영상의학과