

## Intraosseous Hemangioma of the Nasal Septum: A Case Report

## 비중격에서 발생한 골내혈관종 1예

Minho Park, MD<sup>1</sup>, Eui Jong Kim, MD<sup>1\*</sup>, Ji Hye Jang, MD<sup>1</sup>, Kyung Mi Lee, MD<sup>1</sup>,  
Woo Suk Choi, MD<sup>1</sup>, Sung Wan Kim, MD<sup>2</sup>, Yoon Hwa Kim, MD<sup>3</sup>

Departments of <sup>1</sup>Radiology, <sup>2</sup>Otorhinolaryngology-Head & Neck Surgery, <sup>3</sup>Pathology, Kyung Hee University Hospital, Seoul, Korea

Hemangioma can arise in the soft tissues and bone of the nasal cavity. However, to the best of our knowledge, there are no prior case reports presenting intraosseous hemangioma of the nasal septum. Intraosseous hemangioma, in addition to a chondroid tumor, should be included in the differential diagnosis of a calcified mass of the nasal cavity. In the present report, we present a case of an intraosseous cavernous hemangioma in the nasal bony septum of a 53-year-old woman.

## Index terms

Cavernous Hemangioma  
Intraosseous Hemangioma  
Nasal Septum

Received March 11, 2015

Revised April 14, 2015

Accepted June 10, 2015

\*Corresponding author: Eui Jong Kim, MD

Department of Radiology, Kyung Hee University Hospital,  
23 Kyungheedaero-ro, Dongdaemun-gu, Seoul 130-702,  
Korea.

Tel. 82-2-958-8611 Fax. 82-2-968-0787

E-mail: [eujkim@hanmail.net](mailto:eujkim@hanmail.net)

This is an Open Access article distributed under the terms of the Creative Commons Attribution Non-Commercial License (<http://creativecommons.org/licenses/by-nc/3.0>) which permits unrestricted non-commercial use, distribution, and reproduction in any medium, provided the original work is properly cited.

## INTRODUCTION

Hemangiomas account for less than 20% of all benign nasal cavity tumors (1). The majority of hemangiomas arise from the soft tissue of the nasal cavity, however, they can also arise from the bony structures. To the best of our knowledge, there are no prior case reports of intraosseous hemangiomas of the nasal septum. Here, we report one case of intraosseous cavernous hemangioma occurring in the nasal septum.

## CASE REPORT

A 53-year-old woman without any significant medical history was admitted to our hospital for the surgical management of a mass in her nasal septum, which was found incidentally during brain magnetic resonance (MR) imaging at another hospital.

Nasal endoscopy revealed a large, reddish mass originating from the nasal septum (Fig. 1A). Computed tomography (CT)

images revealed a well-defined, expansile, round mass within the anterior nasal septum. The mass showed multiple punctate calcifications, and remodeling of the adjacent bony structures was also seen (Fig. 1B, C). Contrast-enhanced CT images showed heterogeneous enhancement of the mass (Fig. 1D). Retrospective review of the original brain MR imaging revealed a well-defined mass within the anterior nasal septum. It showed high signal intensity with multiple internal low signal intensity foci representing calcifications on T2-weighted MR images (Fig. 1E). A contrast-enhanced MR imaging study was not performed. The mass was thought to be a chondroid tumor such as a chondroma, osteochondroma, or chondrosarcoma. It was completely excised via endoscopic surgery. Pathological examination revealed proliferation of small to intermediate-sized and dilated blood vessels interspersed among mature bone trabeculae (Fig. 1F). The final diagnosis was intraosseous cavernous hemangioma of the nasal septum.

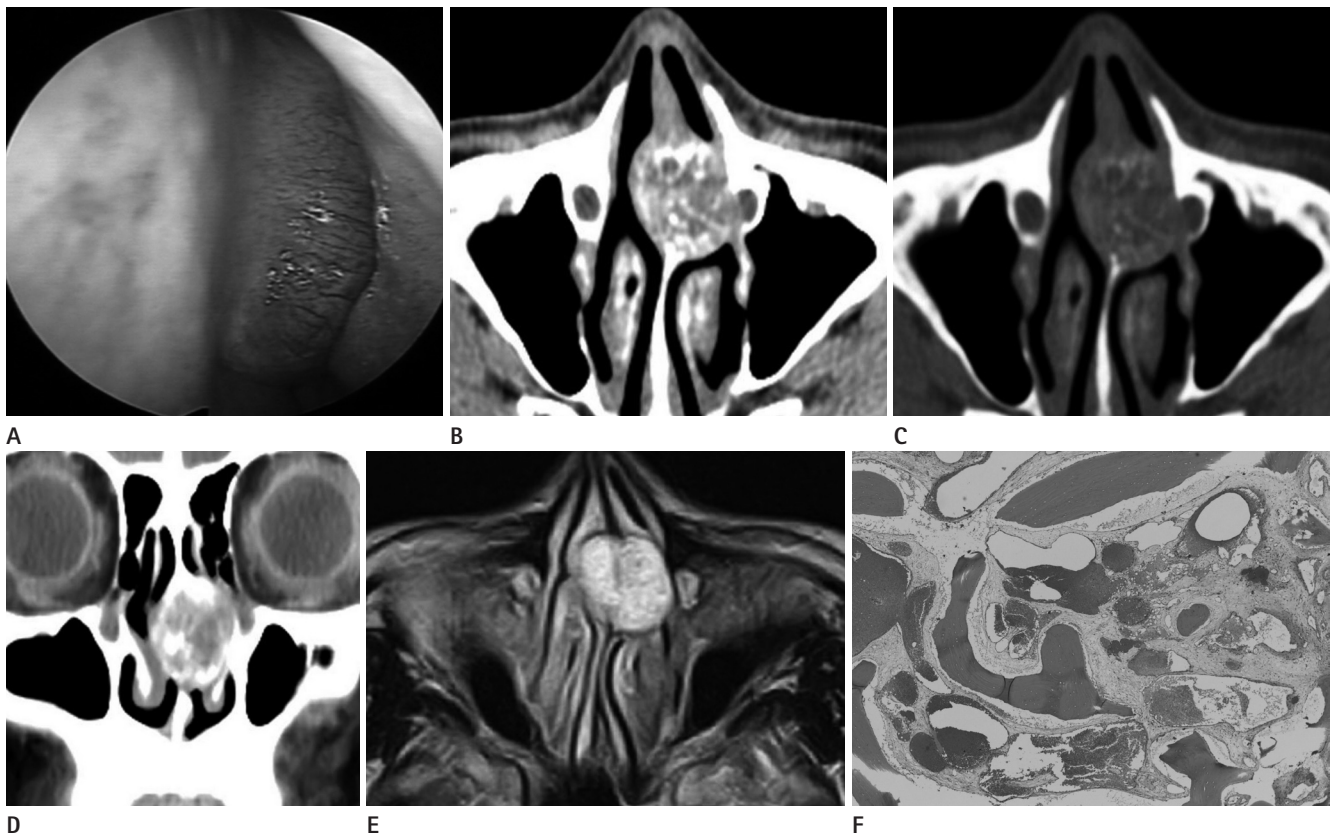
## DISCUSSION

Hemangiomas can occur as solitary bone lesions. Intraosseous hemangiomas in the head and neck are most commonly found in the skull, mandible, nasal bones, and cervical vertebrae. Although intraosseous hemangiomas of the sinonasal cavity are rare, several cases of nasal intraosseous hemangiomas arising from the inferior turbinate, middle turbinate, and paranasal areas have been reported (1-4). The current case, to our knowledge, is the first report of intraosseous hemangioma involving the nasal septum.

Both CT and MR imaging are useful modalities for evaluating lesion characteristics in the sinonasal cavity. Prior literature has suggested that nasal intraosseous hemangiomas present as osteolytic masses with coarse internal trabeculation on CT, which is

referred to as a soap bubble or honeycomb appearance (1-4). MR imaging of these tumors demonstrates low signal intensity on T1-weighted images and high signal intensity on T2-weighted images with strong or globular enhancement (2). These findings are also similar to those of intraosseous hemangiomas elsewhere in the body (5, 6).

As a wide variety of conditions can arise in the sinonasal cavity, and since their imaging findings are not usually pathognomonic, various tumorous lesions should be included in the differential diagnoses of a nasal cavity mass. Benign or malignant chondroid tumors arising within the nasal cavity tend to be lytic bone masses with densely scattered or ring and arc calcifications on CT (7), therefore, internal coarse trabeculation of hemangioma can mimic calcification of a chondroid tumor in the nasal cavity on imaging. Lobular capillary hemangioma, formerly



**Fig. 1.** Intraosseous hemangioma of the nasal septum.

- A. An endoscopic image of the left nasal cavity revealing a reddish, bulging mass arising from the nasal septum.
- B. An axial CT image with soft-tissue window setting demonstrating an expansile osteolytic mass within the nasal septum.
- C. An axial CT image with bone window setting demonstrating a mass with internal punctate calcifications.
- D. A coronal contrast-enhanced CT image showing an enhancing mass of the nasal septum with remodeling of the adjacent bony structures.
- E. Axial T2-weighted MR image demonstrating a nasal septal mass with high signal intensity and internal low signal intensity foci.
- F. Pathological examination showing numerous blood-filled spaces lined with endothelial cells in the mature bone trabeculae (hematoxylin and eosin staining; x 40).

known as pyogenic granuloma, is a benign soft tissue tumor characterized by rapid growth and a friable surface. It can occur in the anterior nasal septum in the area of the Kiesselbach plexus. Previous studies have reported that nasal trauma and pregnancy can be possible predisposing factors of lobular capillary hemangioma in the nasal septum (7). It usually appears as an intensely enhancing mass with an iso- to hypoattenuating cap and frequent adjacent bony changes (8). Benign or malignant minor salivary gland tumors can also arise at the nasal septum (7, 9). For instance, a pleomorphic adenoma tends to be a multilobular tumor with curvilinear enhancement and small non-enhancing foci in the nasal septum. In addition, various other tumorous conditions should be included in the differential diagnoses of a nasal cavity mass, such as carcinoma, neuroendocrine tumor, schwannoma, angiofibroma, and Pindborg tumor (10).

En bloc resection of the tumor is the treatment of choice, and radiation therapy is another treatment option for intraosseous hemangioma (2).

Intraosseous hemangioma of the nasal cavity is a rare benign tumor. However, as it usually reveals relatively characteristic imaging findings such as an osteolytic mass with enhancement and internal coarse trabeculation, it should be considered in the differential diagnoses of a nasal septal tumor.

## REFERENCES

1. Akiner MN, Akturk MT, Demirtas M, Atmis EO. Intraosseous cavernous hemangioma of inferior turbinate: a rare case report. *Case Rep Otolaryngol* 2011;2011:431365
2. Kim YM, Han WK, Choi JW, Rha KS. Two cases of osseous hemangioma of the middle turbinate. *Korean J Otorhinolaryngol-Head Neck Surg* 2008;51:842-845
3. Fahmy FF, Back G, Smith CE, Hosni A. Osseous haemangioma of inferior turbinate. *J Laryngol Otol* 2001;115:417-418
4. Keyik B, Yanik B, Özdemir ZM, Conkbayir I, Özkanlı BS, He- kimoglu B. Intraosseous hemangioma of the middle turbi- nate: a case report. *Yeni Tıp Dergisi* 2009;26:122-123
5. Moore SL, Chun JK, Mitre SA, Som PM. Intraosseous hem- angioma of the zygoma: CT and MR findings. *AJNR Am J Neuroradiol* 2001;22:1383-1385
6. Rigopoulou A, Saifuddin A. Intraosseous hemangioma of the appendicular skeleton: imaging features of 15 cases, and a review of the literature. *Skeletal Radiol* 2012;41: 1525-1536
7. Yildirim D, Saglam O, Gurpinar B, Ilica T. Nasal cavity mass- es: clinico-radiologic collaborations, differential diagnosis by special clues. *Open J Med Imaging* 2012;2:10-18
8. Lee DG, Lee SK, Chang HW, Kim JY, Lee HJ, Lee SM, et al. CT features of lobular capillary hemangioma of the nasal cavity. *AJNR Am J Neuroradiol* 2010;31:749-754
9. Motoori K, Takano H, Nakano K, Yamamoto S, Ueda T, Ike- da M. Pleomorphic adenoma of the nasal septum: MR features. *AJNR Am J Neuroradiol* 2000;21:1948-1950
10. Valencia MP, Castillo M. Congenital and acquired lesions of the nasal septum: a practical guide for differential di- agnosis. *Radiographics* 2008;28:205-224; quiz 326

## 비중격에서 발생한 골내혈관종 1예

박민호<sup>1</sup> · 김의종<sup>1\*</sup> · 장지혜<sup>1</sup> · 이경미<sup>1</sup> · 최우석<sup>1</sup> · 김성원<sup>2</sup> · 김운화<sup>3</sup>

혈관종은 비강의 연조직과 골조직에서 발생할 수 있다. 하지만 비중격에서 발생한 골내혈관종에 대한 보고는 없었다. 비 중격에 발생한 혈관종은 비강에서 발생할 수 있는 여러 종류의 종양들과 감별이 필요하다. 저자들은 53세 여자 환자로 비 중격에서 발생한 골내혈관종을 경험하였기에 보고하는 바이다.

경희대학교병원 <sup>1</sup>영상의학과, <sup>2</sup>이비인후과, <sup>3</sup>병리과