

Angiographic Features of Unilateral Nonbifurcating Cervical Carotid Artery: A Case Report

편측성 무분지경동맥의 혈관 조영술 소견의 증례 보고

Na Lae Eun, MD¹, Seung-Koo Lee, MD^{2*}

¹Department of Radiology, Gangnam Severance Hospital, Yonsei University College of Medicine, Seoul, Korea

²Department of Radiology, Severance Hospital, Yonsei University College of Medicine, Seoul, Korea

Nonbifurcating cervical carotid artery is a rare anomaly of the common carotid artery (CCA), in which the branches of the external carotid artery (ECA) arise directly from the CCA or proximal internal carotid artery without bifurcation, and therefore there is no proximal main trunk of the ECA. We report a unilateral nonbifurcating cervical carotid artery of a 67-year-old woman, incidentally found during cerebral aneurysmal treatment.

Index terms

Nonbifurcating Cervical Carotid Artery

Anomaly

Common Carotid Artery

Unilateral

Received February 12, 2015

Revised March 26, 2015

Accepted April 21, 2015

*Corresponding author: Seung-Koo Lee, MD
Department of Radiology, Yonsei University College of Medicine, 50-1 Yonsei-ro, Seodaemun-gu, Seoul 120-752, Korea.
Tel. 82-2-2228-2373 Fax. 82-2-393-3035
E-mail: slee@yuhs.ac

This is an Open Access article distributed under the terms of the Creative Commons Attribution Non-Commercial License (<http://creativecommons.org/licenses/by-nc/3.0>) which permits unrestricted non-commercial use, distribution, and reproduction in any medium, provided the original work is properly cited.

INTRODUCTION

Nonbifurcating cervical carotid artery is defined as a common carotid artery (CCA), in which branches of the external carotid artery (ECA) arise directly from the CCA or proximal internal carotid artery (ICA) without bifurcation, and therefore there is no proximal main trunk of the ECA (1, 2). Herein, we report a case of a nonbifurcating cervical carotid artery incidentally found during cerebral aneurysmal treatment, which was evident on contrast-enhanced MR angiography (MRA) and conventional angiography.

CASE REPORT

A 67-year-old woman was admitted to the hospital with a complaint of dizziness. The patient's brain MRI and MRA showed a 6 mm-sized aneurysm in the posterior communicating artery origin of the left distal ICA. After detection of the unrup-

tured aneurysm, she received a coil embolization. During procedure, an unusual nonbifurcating right carotid artery was noted in the contralateral CCA roadmap image. The cervical carotid artery continued into the normal ICA from the CCA without bifurcation. The superior thyroidal artery and facial-lingual trunk arose from the right CCA (Fig. 1). Then, the distal part of the ECA (internal maxillary, superficial temporal, occipital artery) appeared to originate from the proximal ICA portion (Fig. 2A). The left CCA showed grossly normal bifurcation and branches of the ECA (Fig. 2B). This report was approved by our Institutional Review Board and the requirement for informed consent was waived.

DISCUSSION

The nonbifurcating cervical carotid artery is a rare disease entity. In Uchino et al's (1) retrospective review of MRA, the incidence was 0.21% (6 out of 2866; 5 men and 1 woman). Our

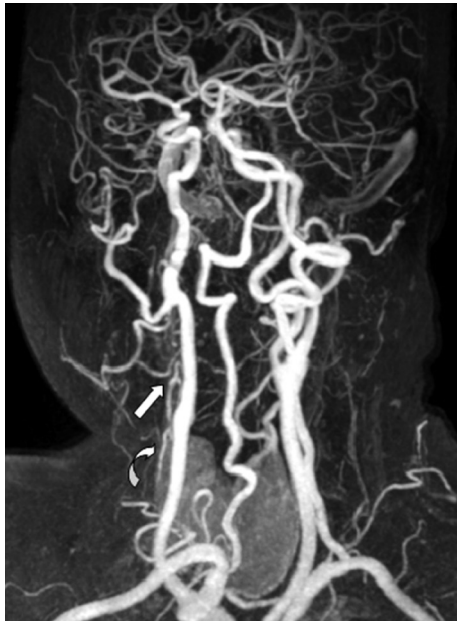

Fig. 1. Anteroposterior maximum intensity projection image of contrast-enhanced MR angiography shows the right CCA is not bifurcating. The right superior thyroid artery (curved arrow) and lingual-facial trunk (arrow) are originating from CCA level of the nonbifurcating cervical carotid artery. Other ECA branches are arising from the probable proximal ICA level of the nonbifurcating cervical carotid artery. CCA = common carotid artery, ECA = external carotid artery, ICA = internal carotid artery

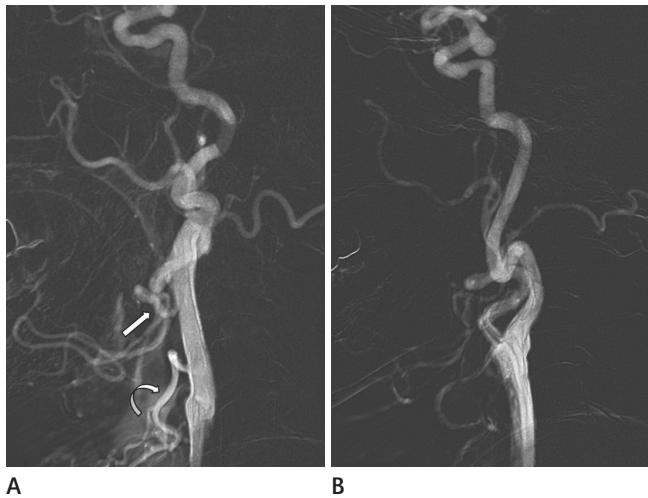


Fig. 2. Lateral view of digital subtraction angiography (DSA) of bilateral carotid arteries.

A. DSA of the right carotid artery shows an unusual cervical carotid artery without bifurcation. The right superior thyroid artery (curved arrow) and lingual-facial trunk (arrow) are arising from the CCA level of the nonbifurcating cervical carotid artery. The internal maxillary, superficial temporal, and occipital arteries are originating from the probable ICA of the nonbifurcating cervical carotid artery.

B. DSA of left cervical carotid artery (left) shows the normal bifurcation of the CCA and the ECA with its branches.

CCA = common carotid artery, ECA = external carotid artery, ICA = internal carotid artery

case of a nonbifurcating cervical carotid artery was found in the right carotid artery of a 67-year-old woman. In a review of the literature representing 27 cases, 20 cases were in men and 7 cases were in women. Fourteen out of the 27 cases (1, 3-5) involved the right cervical carotid artery and 13 cases were on the left side, which indicates there is no side preference.

Morimoto et al. (6) first described the term “nonbifurcating cervical carotid artery” in 1990. Two hypotheses of the nonbifurcating cervical carotid artery were suggested to explain the formation of the anomaly. Embryologically, the cervical carotid artery develops from complicated processes of regression and communication in vascular networks between the ventral, dorsal aorta, and the aortic arch (2, 7). The first and second aortic arch usually regresses and the ECA is formed from a linkage between the ventral pharyngeal artery from the ventral aorta and the stapedia artery from the second aortic arch (2).

The first theory of the nonbifurcating carotid artery is the agenesis of the main trunk of the ECA. The persistence of the proximal hyoid artery from the second aortic arch with the failure to transfer its distal branches would explain this theory (8). This hypothesis is based on the following observations: the nonbifurcating cervical carotid artery runs through as the normal ICA into the cranium, the diameter of the cervical portion is as large as the normal ICA, the trunk has its carotid body (9), and some show severe atherosclerotic changes in the cervical portion as well as in the ICA (8).

The second theory is the agenesis of the proximal ICA. According to “segmental identity” proposed by Lasjaunias et al. (10), the ICA consists of seven segments. The nonbifurcating artery is associated with segmental agenesis of the ICA, especially of the cervical segment (5). The hypothesis is explained by the fact that almost all branches of the nonbifurcating carotid artery are supplied from the ECA. The nonbifurcating cervical carotid artery may show the tortuosity of the carotid artery and remnant arterial stump (2).

In our case of the nonbifurcating cervical carotid artery, the latter theory seems more plausible. The affected artery of our case did not show a physiological dilation of the origin of the ICA without any visible stump, and the occipital artery arose distally (1). These points support the latter hypothesis. The clinical implication of the nonbifurcating cervical carotid artery is not well known and sometimes this anomaly is overlooked. Howev-

er, appropriate diagnosis is necessary to avoid complications, such as embolic infarctions during interventional radiologic procedures or head and neck surgeries (1, 5).

REFERENCES

1. Uchino A, Saito N, Watadani T, Mizukoshi W, Nakajima R. Nonbifurcating cervical carotid artery diagnosed by MR angiography. *AJNR Am J Neuroradiol* 2011;32:1119-1122
2. Ooigawa H, Nawashiro H, Fukui S, Tsuzuki N, Katoh H, Kawaguchi T, et al. Non-bifurcating cervical carotid artery. *J Clin Neurosci* 2006;13:944-947
3. Nakai K, Kaji T, Uchino A, Kawauchi T, Tamura C, Otani N, et al. Congenital external carotid-internal carotid artery anastomosis associated with contralateral non-bifurcating cervical carotid artery. *Neuroradiology* 2012;54:521-523
4. Tokugawa J, Yoshida K, Yamamoto M, Kamiyama H, Oishi H, Arai H. Large aneurysm in a nonbifurcating cervical carotid artery: an aneurysm associated with a rare anomaly treated with radial artery graft bypass: case report. *Neurosurgery* 2011;68(1 Suppl Operative):250-253; discussion 253
5. Sasaki T, Nagashima H, Oya F, Satoh D, Kobayashi S. Carotid artery stenting for atherosclerotic stenosis associated with non-bifurcating cervical carotid artery. *Neurol Med Chir (Tokyo)* 2013;53:228-232
6. Morimoto T, Nitta K, Kazekawa K, Hashizume K. The anomaly of a non-bifurcating cervical carotid artery. Case report. *J Neurosurg* 1990;72:130-132
7. Kiyosue H, Mori H, Tanoue S, Sagara Y, Hori Y, Miyamoto S, et al. Non-bifurcating carotid artery coexisting with transverse sinus dural arteriovenous fistula. *Neuroradiology* 2009;51:697-698
8. Lambiase RE, Haas RA, Carney WI Jr, Rogg J. Anomalous branching of the left common carotid artery with associated atherosclerotic changes: a case report. *AJNR Am J Neuroradiol* 1991;12:187-189
9. Kaneko K, Akita M, Murata E, Imai M, Sowa K. Unilateral anomalous left common carotid artery; a case report. *Ann Anat* 1996;178:477-480
10. Lasjaunias P, Theron J, Moret J. The occipital artery. Anatomy--normal arteriographic aspects--embryological significance. *Neuroradiology* 1978;15:31-37

편측성 무분지경동맥의 혈관 조영술 소견의 증례 보고

은나래¹ · 이승구^{2*}

무분지경동맥은 외경동맥이 총경동맥이나 근위 내경동맥에서 분지 없이 발생하는 드문 혈관 기형의 하나이다. 67세 여자 환자의 뇌동맥류 치료 도중 우연히 발견된 편측성의 무분지경동맥의 증례 보고를 하고자 한다.

¹연세대학교 의과대학 강남세브란스병원 영상의학교실, ²연세대학교 의과대학 세브란스병원 영상의학교실