

Retained Foreign Body in Pyothorax: Removal Using Snare Catheter and Endoscopic Biopsy Forcep Under the Fluoroscopic Guidance

농흉내 의인성 이물: 투시하에서 올가미카테터와 내시경용 생검검자를 이용한 제거

Yoonhee Han, MD, Jae Hyun Kwon, MD

Department of Radiology, Dongguk University Ilsan Hospital, Goyang, Korea

An iatrogenic foreign body (the surface coating polyurethane film of the guide wire) that was incurred during thoracentesis of chronic empyema, was removed by an interventional technique using a snare catheter and endoscopic biopsy forcep.

Index terms

Empyema
Drainage
Pleural Cavity
Foreign Bodies
Radiology
Interventional

Received August 1, 2014; Accepted November 4, 2014

Corresponding author: Yoonhee Han, MD
Department of Radiology, Dongguk University Ilsan Hospital, 27 Dongguk-ro, Ilsandong-gu, Goyang 410-773, Korea.
Tel. 82-31-961-7821 Fax. 82-31-961-8281
E-mail: hanyoonhee@naver.com

This is an Open Access article distributed under the terms of the Creative Commons Attribution Non-Commercial License (<http://creativecommons.org/licenses/by-nc/3.0>) which permits unrestricted non-commercial use, distribution, and reproduction in any medium, provided the original work is properly cited.

INTRODUCTION

Various kinds of foreign bodies in the pleural space have been reported, and most of them were surgically removed (1). The surface coating polyurethane film of the Terumo wire peeled off during thoracentesis, and its fragments remained in the pyothorax in the form of strings in the reported case. We removed the iatrogenic foreign body in the pyothorax by an interventional technique using a snare catheter and endoscopic biopsy forcep.

CASE REPORT

A 62-year-old male was admitted to our hospital with pneumonia and pyothorax. He was referred to our clinic for a diagnostic and therapeutic thoracentesis of the left pyothorax. We attempted percutaneous drainage catheter insertion into the left pyothorax. Under ultrasonography guidance, an 18-gauge aspiration needle (Chiba needle, Cook Medical, Bloomington, IN, USA) was advanced into the pyothorax. Next, under fluoro-

scopic guidance a 0.035 guide wire (A Plus guide wire, A&A M.D., Gyeonggi, Korea) was passed through the aspiration needle into the pyothorax. However, in the process of wire manipulation, the wire became stuck in the edge of the needle. When the wire was forcedly pulled out, the surface coating polyurethane film of the wire was peeled off, and its fragments remained in the pyothorax in the form of strings. A chest PA and CT scan were performed to determine the exact anatomy and location of the fragments. The chest PA (Fig. 1A) showed linear radiopaque foreign body shadows in the left pyothorax. Surgical removal was not considered for the patient due to diabetes mellitus and hypertension.

Two days later interventional removal was attempted. First, a 10 French 10 cm vascular sheath (Pinnacle introducer sheath, Terumo Medical, Somerset, NJ, USA) was inserted into the left pyothorax, and its tip was positioned near the foreign bodies. Next, a 15 mm diameter snare catheter (Amplatz Goose Neck snare, ev3 Endovascular, Plymouth, MN, USA) was passed through the sheath, and the polyurethane fragments were snatched by the

snare catheter and subsequently pulled out through the sheath. The process was repeated several times (Fig. 1B, C). However, we were unable to approach the last remaining fragment with the snare catheter. The sheath was repositioned to find the shortest route to the remaining piece, and removal with the snare catheter was attempted once more. However, there was not enough space for the snare catheter to make a loop around the fragment, resulting in failure to retrieve the final fragment. At that time, we decided to try using the colonoscopic biopsy forcep (Maxum Reusable Forcep, Cook Medical, Bloomington, IN, USA). We inserted the forcep through the sheath and positioned its tip just above the fragment. We then used the forcep to capture the fragment and successfully pull it out through the sheath (Fig. 1D, E).

After removal of the foreign bodies, a 10-Fr pigtail catheter was inserted in the left pyothorax. There were no immediate procedure related complications, and no change in hemodynamic or respiratory status during the entire procedure.

DISCUSSION

An empyema is pus in the pleural space. Most empyemas are fibrinopurulent, and characterized by loculated and turbid fluid collections. Advanced empyemas involve organization of the infected pleural effusion. For drainage of an advanced small empyema, we used the Seldinger technique, with an 18-gauge aspiration needle and a 0.035 guide wire (A Plus guide wire, A&A

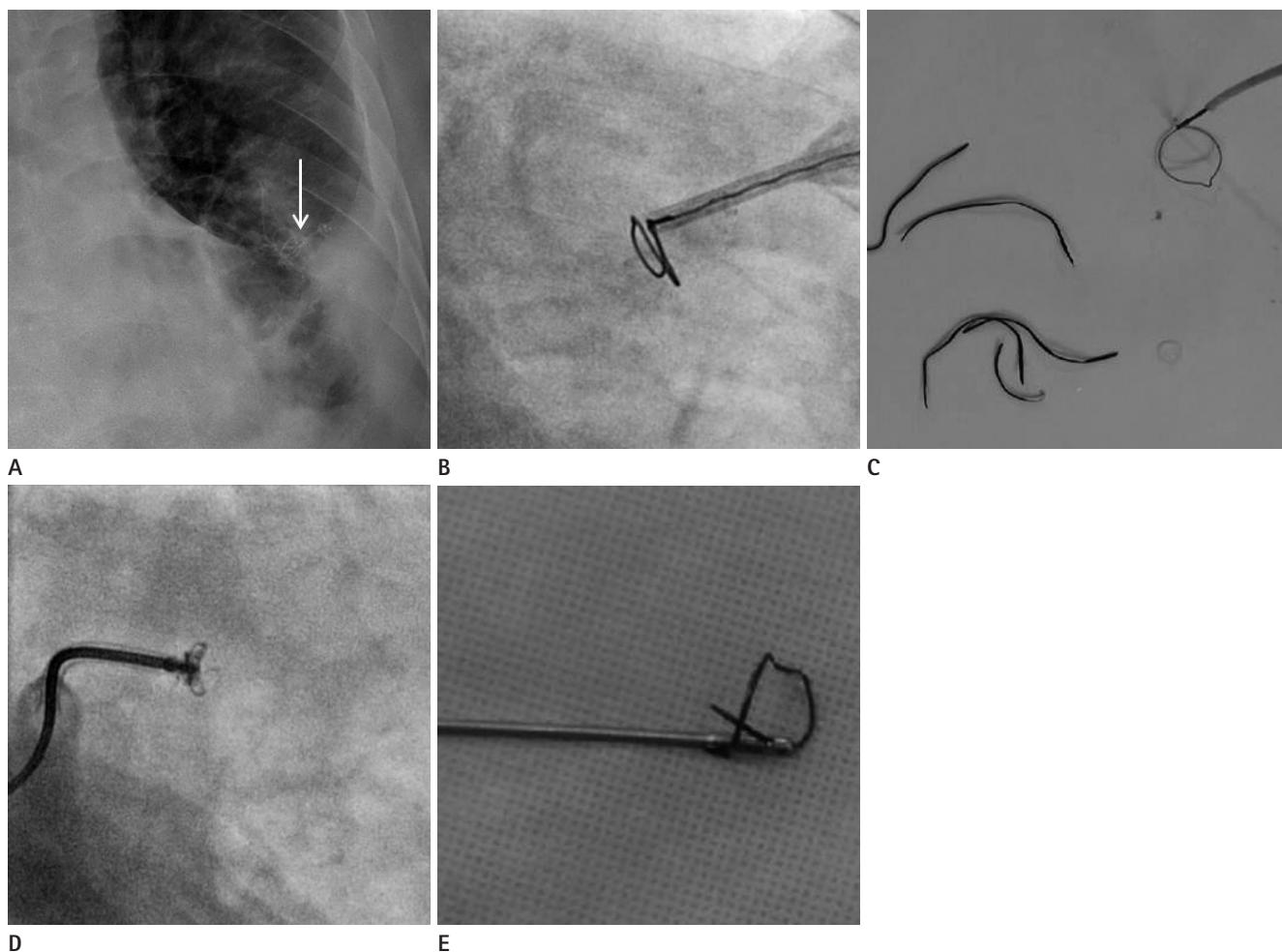


Fig. 1. Iatrogenic foreign bodies in chronic pyothorax were removed by interventional technique.
A. Chest PA showing string-like foreign bodies (arrow) in left lower lung zone.
B. Fluoroscopic image showing the Amplatz Goose Neck snare catheter inserted through the sheath.
C. Foreign bodies retrieved by the snare catheter.
D. Fluoroscopic image showing the forcep capturing the foreign body.
E. Endoscopic biopsy forcep holding the foreign body.

M.D., Gyeonggi, Korea). Using the aspiration needle and a guide wire for the purpose of draining an uncomplicated effusion does not cause any problems; however, in advanced small empyema as in the current case, it can be a big problem. During wire manipulation in such a small, stiff space, the wire can become stuck and scrape on the sharp edge of the needle tip. The surface of the guide wire was coated with polyurethane film, in contrast with the stiff guide wire, hence the surface coating film was easily peeled off. Similar cases can occur in a femoral artery puncture for angiography. If the guide wire is stuck in the Seldinger needle, its surface coating of polyurethane film could likewise be peeled off. Usually, this causes an embolism in the ipsilateral popliteal artery. We have experience removing it using a snare catheter.

Various kinds of foreign bodies in the pleural space have been reported. Most of them have been surgically removed by procedures such as a thoracotomy, video-assisted thoracoscopy, direct pleuroscopy, or simple incision (1-5). Recently, one case was reported in which a pigtail catheter fragment in the pleural space was removed by an interventional technique using a guide wire (Bentson wire, Cook Medical, Bloomington, IN, USA) and a loop snare (EN Snare Endovascular Snare System, Merit Medical, South Jordan, UT, USA) (6).

In summary, we do not recommend the use of a 0.035 hydrophilic coated guide wire for the purpose of draining advanced small empyema, since it involves a risk of the polyurethane coat

peeling off. Pleural foreign bodies are typically removed surgically, but various interventional techniques can also be used as a treatment of choice.

REFERENCES

1. Weissberg D, Weissberg-Kasav D. Foreign bodies in pleura and chest wall. *Ann Thorac Surg* 2008;86:958-961
2. Tie ST, Wong JL, Kannan SK, Rahman JA. Pleuroscopic retrieval of a sewing needle from the pleural cavity under conscious sedation by a chest physician. *J Bronchology Interv Pulmonol* 2012;19:246-248
3. Apiliogullari B, Duzgun N, Kurtipek E, Esme H. Retained foreign body after chest stab wound. *BMJ Case Rep* 2014;2014. <http://dx.doi.org/10.1136/bcr-2014-203598>
4. Paddle A, Elahi M, Newcomb A. Retained foreign body following pleural drainage with a small-bore catheter. *Gen Thorac Cardiovasc Surg* 2010;58:42-44
5. Williams CG, Haut ER, Ouyang H, Riall TS, Makary M, Efron DT, et al. Video-assisted thoracic surgery removal of foreign bodies after penetrating chest trauma. *J Am Coll Surg* 2006;202:848-852
6. Hong R, Kwon W. Loop snare removal of pigtail catheter fragment from the pleural space. *Cardiovasc Intervent Radiol* 2014;37:855-857

농흉내 의인성 이물: 투시하에서 올라미카테터와 내시경용 생검검자를 이용한 제거

한윤희 · 권재현

흉막천자 중 발생한 의인성 이물(유도철사의 표면에 입혀진 폴리아우레탄 막)을 투시하에서 올라미카테터와 내시경용 생검검자로 제거하였다.

동국대학교 일산병원 영상의학과