

Synovial Cyst of the Hip Joint as a Rare Cause of Unilateral Leg Edema: A Case Report¹

고관절 활액막낭종에 의한 편측 하지부종: 증례 보고¹

Jihun Kang, MD¹, Il Soo Chang, MD¹, Sang Woo Park, MD¹, Ik Jin Yun, MD², Hyung Kyu Park, MD³, Wan Seop Kim, MD³, Hui Jin Lee, MD¹, Na Ra Kim, MD¹, Sung Gyu Moon, MD¹

Departments of ¹Radiology, ²Surgery, ³Pathology, Konkuk University School of Medicine, Seoul, Korea

A synovial cyst of the hip joint is a rare cause of unilateral leg edema, and it is usually associated with arthropathies such as rheumatoid arthritis and osteoarthritis. An asymptomatic synovial cyst of the hip joint that is not associated with an arthritic condition occurs infrequently. In this paper, we described the case of a 52-year-old woman who presented with unilateral right leg edema caused by a synovial cyst of the hip joint.

Index terms

Leg
Edema
Hip Joint
Synovial Cyst
Veins

Received November 3, 2014

Accepted January 29, 2015

Corresponding author: Il Soo Chang, MD

Department of Radiology, Konkuk University School of Medicine, 120-1 Neungdong-ro, Gwangjin-gu, Seoul 143-729, Korea.

Tel. 82-2-2030-5487 Fax. 82-2-2030-5549

E-mail: raddrsu@kuh.ac.kr

This is an Open Access article distributed under the terms of the Creative Commons Attribution Non-Commercial License (<http://creativecommons.org/licenses/by-nc/3.0>) which permits unrestricted non-commercial use, distribution, and reproduction in any medium, provided the original work is properly cited.

INTRODUCTION

Unilateral lower limb edema can be caused by several conditions such as deep vein thrombosis (DVT), lymphedema, and chronic venous insufficiency (1). It is necessary to also be aware of the uncommon causes of this condition. We report an unusual case of a patient with unilateral limb edema, which occurred due to a synovial cyst that was treated successfully with surgical intervention.

CASE REPORT

A 52-year-old woman, with diabetes mellitus and a 10-year history of hypertension, presented with a gradually worsening right leg edema without pain which persisted for a month. There was no history of trauma, arthritis, or immobilization. During physical examination, no abnormality was found except for the presence of pitting edema in the right leg. Ultrasonography (US), contrast-enhanced computed tomography (CT), and

ascending venography were performed to rule out the DVT. US showed 2.1 cm sized hypoechoic mass compressing the right common femoral vein (Fig. 1). There was no blood flow within the mass on Doppler US. The CT scan demonstrated a 2.3 cm sized homogenous hypodense, well-defined, cystic mass compressing the right common femoral vein in front of the right hip joint (Fig. 2). No deep venous thrombosis was detected in the right lower extremity. Ascending venography was performed to demonstrate extrinsic compression and the absence of clots. It showed filling defect of the right common femoral vein, without the development of collateral venous flow (Fig. 3). On the basis of these findings, differential diagnosis included synovial cyst, ganglion cyst, paralabral cyst, and noninflammatory pseudotumor. During the surgery, a cystic mass of 2.5 cm in size was found protruding from the right hip joint and compressing the posterior wall of the left common femoral vein. The cystic mass was easily separated from the right common femoral vein and was excised successfully. No communication was found between the hip joint space and the cyst. Histological examination

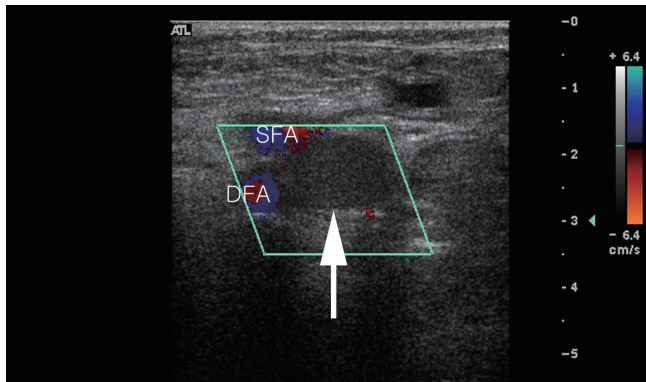


Fig. 1. Doppler ultrasonography shows a hypoechoic (not anechoic) mass compressing the right common femoral vein (white arrow). Note that there is no color signal that would suggest the presence of blood flow. The two color signals by the mass represent superficial (upper) and deep femoral artery (lower).
DFA = deep femoral artery, SFA = superficial femoral artery

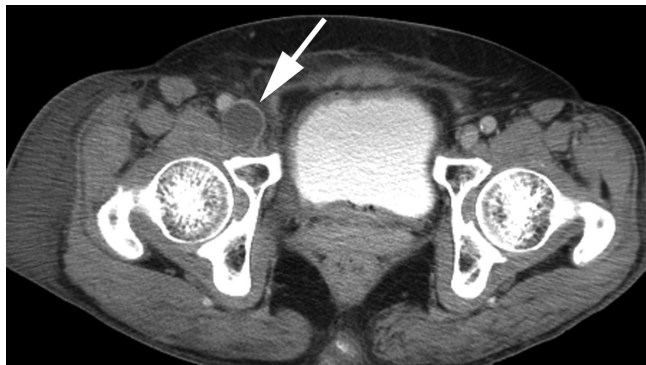

Fig. 2. The CT scan shows a cystic mass compressing the right common femoral vein (white arrow).

confirmed the diagnosis of a synovial cyst (Fig. 4). Surgical removal of the synovial cyst restored normal venous return and promptly relieved the patient's symptoms. The patient was discharged on the fifth postoperative day.

DISCUSSION

Benign cystic lesion, associated with compression of the femoral vein and lower leg edema around the hip joint is a rare condition. Until now, 33 cases have been reported in literature, including this case (2-4). Histologically, there are two types of cysts: synovial and ganglion cysts. While synovial cyst is a juxta-articular fluid collection lined by synovial cells, ganglion cyst is thought to be a myxomatous degeneration of certain fibrous tissue structures without the lining of synovial cell (3). Since the treatment for these two para-articular cysts is similar, clinical differentiation of ganglion and synovial cysts may not be impor-

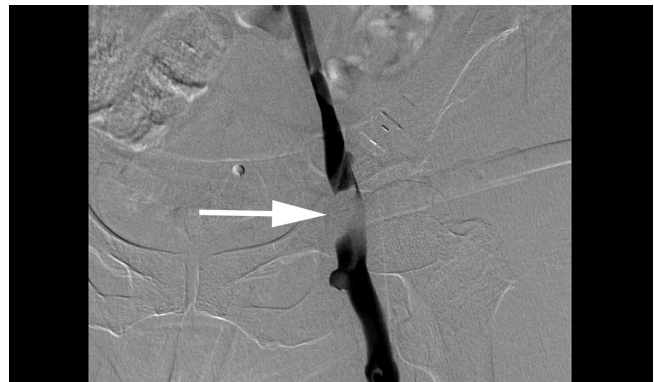

Fig. 3. Ascending venography (prone position) shows extrinsic compression of the right common femoral vein (white arrow). There is no evidence of deep vein thrombosis.

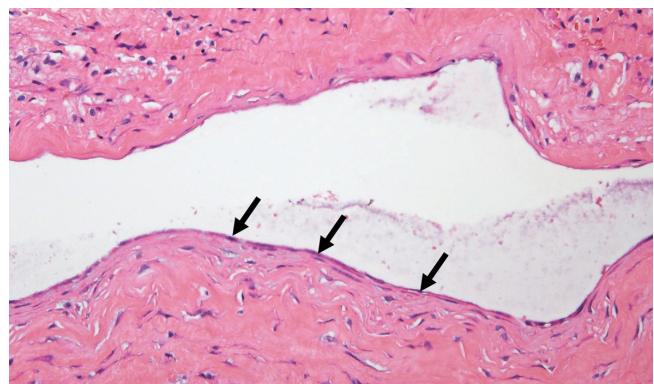


Fig. 4. The excised lesion showed a cyst with thin fibrous cyst wall. The cyst wall was lined by a layer of flat, elongated synovial cells (arrows) (hematoxylin & eosin, $\times 200$).

tant. Moreover, distinguishing between synovial and ganglion cyst using imaging is not always possible (5). It is known that synovial cyst is usually accompanied by the conditions affecting the hip, such as rheumatoid arthritis and osteoarthritis (6). A synovial cyst is a herniation of the synovial membrane caused by inflammation with an overproduction of synovial fluid (7). Such a cyst may cause unilateral edema in the lower extremity, when it compresses the adjacent venous structure (2). The most common clinical manifestation of a synovial cyst of the hip joint is a palpable mass or the pain in the inguinal area or in the anterior thigh, due to compression of the femoral nerve (8). Iliopsoas bursitis presents with a triad of findings, which includes a mass in the inguinal region, pressure effect on the nearby structures, and roentgenologic arthritic changes (9). However, Iwata et al. (4) insisted that the presence of an inguinal mass and groin pain is not mandatory for the diagnosis of iliopsoas bursitis. In addition, one report has shown that in only 55% of the cases with a synovial cyst of the hip joint, compression of the adjacent vein

was accompanied by a hip joint condition such as rheumatoid arthritis and osteoarthritis (2). Our patient also presented with unilateral edema in the lower leg, without a history of hip joint disease and other clinical manifestations such as pain or the presence of a palpable mass. The mass may have been difficult to palpate and it may not have caused compression of the femoral nerve, because of its small size and location under the femoral vein. Therefore, because a synovial cyst of the hip joint can only cause the lower limb edema without any other symptoms, it should be considered in the differential diagnosis of other conditions such as DVT and lymphedema.

Of the various imaging tools, US may be the most cost-effective, simple, and quick assessment of a synovial cyst in the inguinal area. However, it is difficult to differentiate between a cystic and solid mass, when the cyst contains debris and hyperplastic synovium (10). Although contrast-enhanced CT scan is a suitable imaging modality for the evaluation of the cyst size and its effect on the surrounding structures, magnetic resonance imaging (MRI) is the most accurate imaging technique for assessing the characteristics of soft tissue abnormalities and those associated joint disorders (3). All communications between the iliopsoas bursa and hip joint were demonstrated on MRI, whereas US demonstrated these in only 56% and CT in 60% of the cases (10). Ascending venography is useful for differentially diagnosing the synovial cyst of the hip joint and DVT, and it also helps to avoid anticoagulation therapy. However, recent developments in imaging techniques have decreased the need for venography.

A synovial cyst of the hip joint can be treated by surgical excision, needle aspiration, total hip arthroplasty, or instillation of a steroid or sclerosing agent (2, 4). In asymptomatic cases, it may be left untreated. However, when the vessels or nerves around the inguinal region are compressed by the cyst, it should be surgically excised because of the associated high rate of recurrence (37%) (2).

In conclusion, this case demonstrates that unilateral edema in the lower extremity may be caused by a synovial cyst of the hip joint, without any accompanying arthropathies or symptoms

such as pain and a mass in the inguinal region. In the presence of compression of the adjacent vessel or nerve, surgical excision is the treatment of choice for a synovial cyst of the hip joint.

REFERENCES

1. Ely JW, Osheroff JA, Chambliss ML, Ebell MH. Approach to leg edema of unclear etiology. *J Am Board Fam Med* 2006; 19:148-160
2. Colasanti M, Sapienza P, Moroni E, Mosiello G, Postacchini F, di Marzo L. An unusual case of synovial cyst of the hip joint presenting as femoral vein compression and severe lower limb edema. *Eur J Vasc Endovasc Surg* 2006;32:468-470
3. Matsumoto H, Yamamoto E, Kamiya C, Miura E, Kitaoka T, Suzuki J, et al. Femoral vein compression resulting from a ganglion of the hip joint: a case report. *Ann Vasc Dis* 2012;5:233-236
4. Iwata T, Nozawa S, Ohashi M, Sakai H, Shimizu K. Giant iliopsoas bursitis presenting as neuropathy and severe edema of the lower limb: case illustration and review of the literature. *Clin Rheumatol* 2013;32:721-725
5. Bhan C, Corfield L. A case of unilateral lower limb swelling secondary to a ganglion cyst. *Eur J Vasc Endovasc Surg* 2007;33:371-372
6. Sartoris DJ, Danzig L, Gilula L, Greenway G, Resnick D. Synovial cysts of the hip joint and iliopsoas bursitis: a spectrum of imaging abnormalities. *Skeletal Radiol* 1985;14:85-94
7. Williams RA, Marks LJ. Synovial cyst causing an inguinal mass. *Br Med J* 1978;2:91-92
8. Sugiura M, Komiyama T, Akagi D, Miyata T, Shigematsu H. Compression of the iliac vein by a synovial cyst. *Ann Vasc Surg* 2004;18:369-371
9. Melamed A, Bauer CA, Johnson JH. Iliopsoas bursal extension of arthritic disease of the hip. *Radiology* 1967;89:54-58
10. Wunderbaldinger P, Bremer C, Schellenberger E, Cejna M, Turetschek K, Kainberger F. Imaging features of iliopsoas bursitis. *Eur Radiol* 2002;12:409-415

고관절 활액막낭종에 의한 편측 하지부종: 증례 보고¹

강지훈¹ · 장일수¹ · 박상우¹ · 윤익진² · 박형규³ · 김완섭³ · 이희진¹ · 김나라¹ · 문승규¹

고관절에 발생하는 활액막낭종은 편측 하지부종의 드문 원인이며, 대개는 류마티스 관절염이나 퇴행성 관절염과 같은 관절질환과 연관되어 있다. 관절질환이나 증상을 동반하지 않는 고관절의 활액막낭종은 더욱 드물다. 이에 고관절 활액막낭종에 의해 발생한 편측 하지부종을 보인 52세 여자 환자에 대해서 보고하고자 한다.

건국대학교 의학전문대학원 ¹영상의학교실, ²외과학교실, ³병리과학교실